

# Venous congestion & lymphoedema

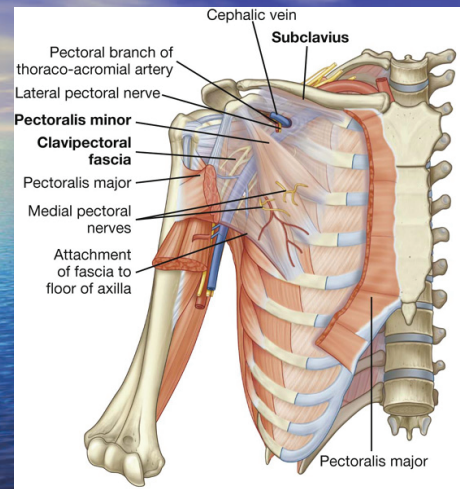
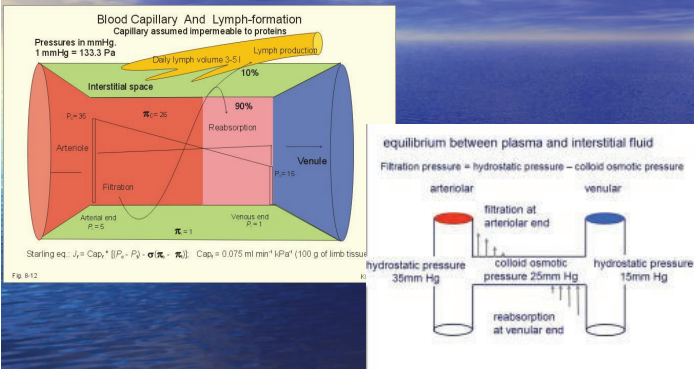
Mr Alex Munnoch FRCSed (Plast)  
 Consultant Plastic Surgeon  
 Ninewells Hospital, Dundee  
*Honorary Professor  
 Macquarie University, Sydney*



## Aims

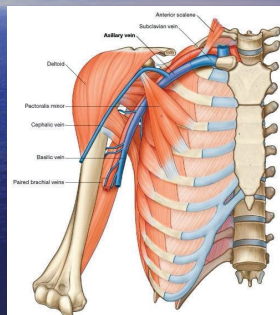
- Physiology
- Anatomy
- Aetiology
- Treatment

## Starling principle

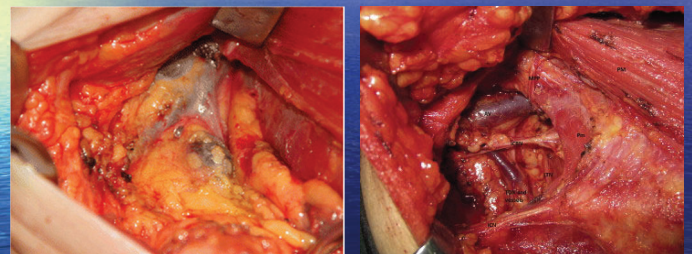

## Axillary venous congestion

- Anomalous pectoralis minor
- Thoracic outlet syndrome
- Thrombosis
- Pancoast tumour
- Scarring
  - Fractured clavicle
  - Nodal clearance +/- radiotherapy



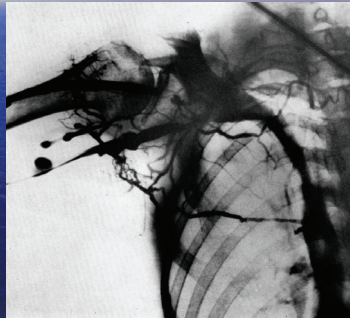
## Axillary dissection



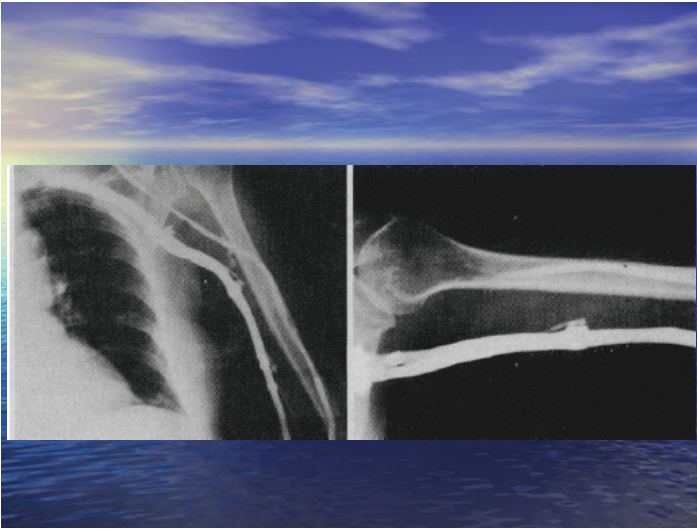
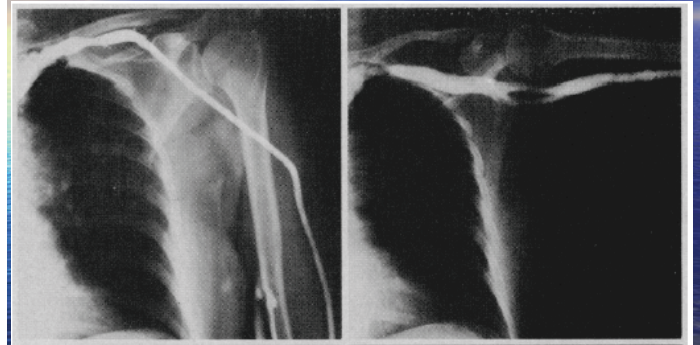


## Venous obstruction after axillary clearance

- Hughes BJS 1966 – 16/19 with lymphoedema had venous obstruction
- Arnulff Vasc Surg 1973 – 8/13 cases, lymphoedema resolved after scar release



## Larson – Arch Surg 1973

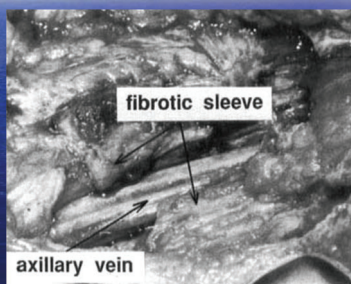


## Larson's findings

- 14 postmastectomy oedema patients
  - In adduction, axillary vein normal in 4, narrowed in 3, obstructed in 7
  - In abduction, 9 cases normal, 4 cases distorted, 1 not visualised
  - 8 underwent scar release – 5 excellent result with minimal oedema postop

## Segerstrom 1991

- Hypothesis – retracting scar tissue around vein contributes to brachial oedema



## Segerstrom results

Table I. Oedema expressed as difference in volume between affected and contralateral arms

Volume (ml)	No. of patients	
	Before operation	After operation
< 150	0	5
151-300	1	8
301-450	8	4
451-600	4	0
> 600	7	3



## Blood flow in axillary vessels after dissection

Mean blood flow velocity (cm/s)—G1	Ipsilateral	Contralateral	P value
Axillary artery	11.16 (1.67)	8.33 (0.75)	<0.0001*
Axillary vein	7.33 (1.67)	3.83 (0.83)	<0.0001*
Brachial artery	16.50 (3.08)	15.83 (2.33)	<0.0001*
Brachial vein	3.66 (0.34)	2.83 (0.67)	<0.0001*

Values expressed as median and interquartile range  
\* P < 0.05


- Matheus – breast cancer res treat 2011

## Becker – Annals Surgery 2006

- Long-term results following microsurgical lymph node transfer
  - 24 patients BCRL
  - Fibrotic muscular and burned tissue were dissected and adhesions released from axillary vessels
  - Lymph nodes from groin
  - 10 normal, 6 <50% reduction, 6 >50%, 2 unchanged

## Delayed breast reconstruction

- Objective improvement in upper limb lymphoedema following ipsilateral latissimus dorsi pedicled flap breast reconstruction – a case series and review of the literature. Abbas Kan *et al.* J Plast Reconstr Aesthetic Surg 2011



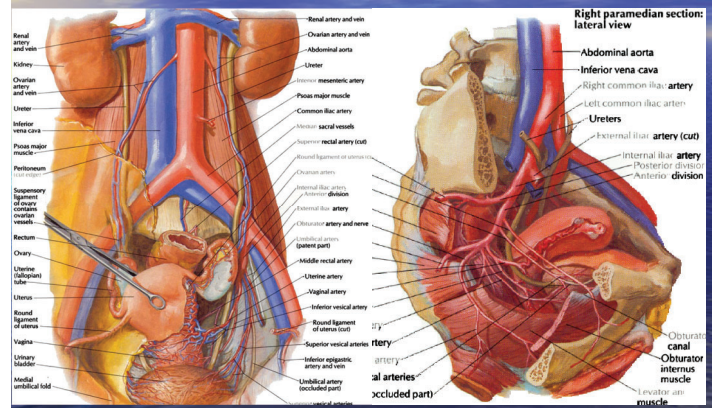
Positive impact of delayed breast reconstruction on breast-cancer treatment-related arm lymphoedema. Blanchard *et al* JPRAS 2012

## Release of scar tissue or new lymphatic drainage???

## Vandermeeren & Belgrado

- Release of axillary scarring & lipofilling
- Ongoing series of patients
- Positive adduction/compression test
- No garments 1 week preop & 2 weeks postop
- Volume measurements
- Demonstrates a volume reduction postop

## Pelvic anatomy





## Iliac vein congestion

- May Thurner (Cockett's) Syndrome
- Bladder distension
- Faecal impaction
- Pregnancy
- Renal transplant
- Endometriosis
- Hip arthroplasty
- Aortic aneurysm
- Retroperitoneal fibrosis
- Rheumatoid cyst
- Spondylolisthesis
- Thrombosis
- Post-thrombotic scarring
- Post-surgical scarring

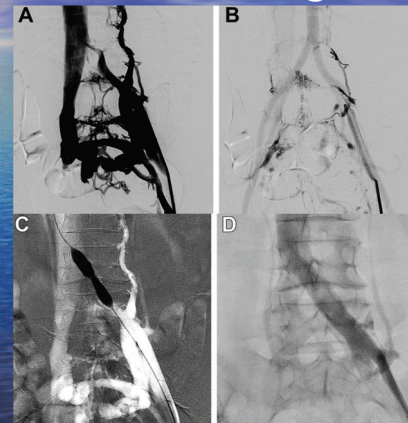
## May-Thurner syndrome

- First described in 1908 by McMurrich
- Anatomically by May & Thurner in 1957
- Clinically by Cockett & Thomas in 1965
- Left iliac vein compressed between right iliac artery & 5<sup>th</sup> lumbar vertebra
- Rarely right side can be affected
- 50% of population may have degree of LIVC

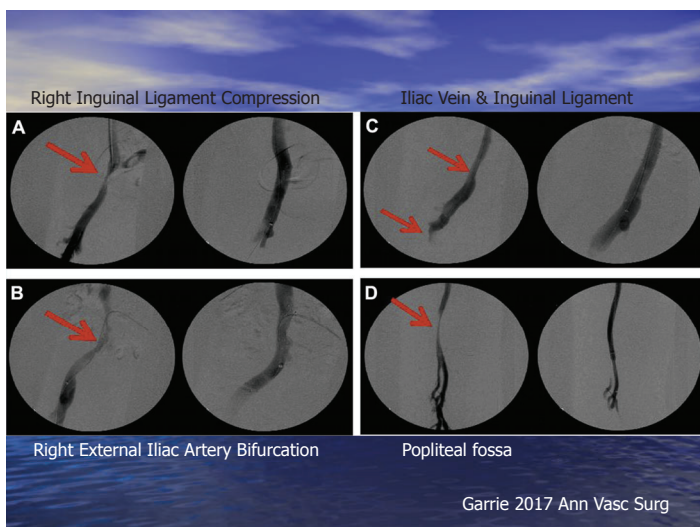
## Diagnosis

- History & examination
  - Adolescence, pregnancy, postmenopause
  - Leg oedema, DVT, Phlebitis, Chronic Venous Insufficiency
- Imaging – US, CT, MRI, Venogram
  - >50% luminal narrowing or extensive intravascular webs
  - Hypogastric or Retroperitoneal collateralization

## Endovascular stenting



Rollo 2017  
J Vasc Surg  
Venous  
Lymphat  
Disord



Garrie 2017 Ann Vasc Surg

## Summary

- Multiple aetiologies for oedema secondary to upper/lower limb venous obstruction
- Surgical release or endovascular stenting effective
- Compression beneficial

## Daily mail article 2012

- The amazing three-in-one cancer operation; it rebuilds your breast, gives you a tummy tuck AND cures swollen, aching arms
- 'I think the lymph node transfer started working immediately. I woke up the morning after the operation... and could easily slip my wedding ring on and off – before I couldn't budge it'
- 'A few days later...measured ... Both arms were the same size: the swelling had gone'

## Thank you

