

Venous congestion & lymphoedema

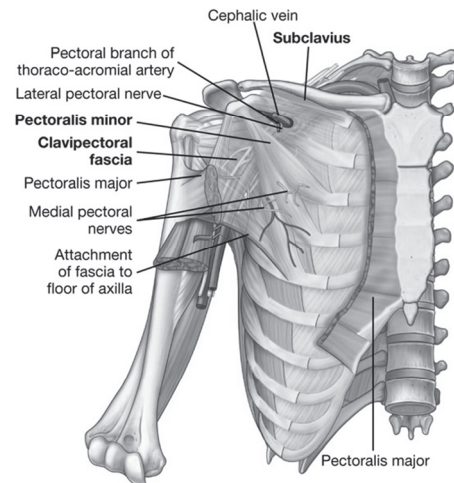
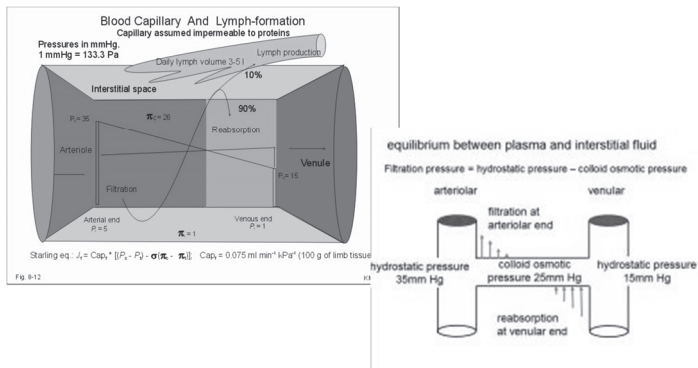
Mr Alex Munnoch FRCSed (Plast)
Consultant Plastic Surgeon
Ninewells Hospital, Dundee
Honorary Professor
Macquarie University, Sydney



Aims

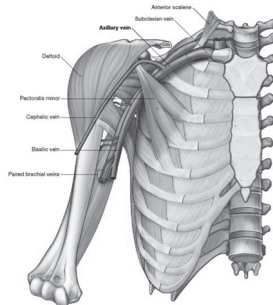
- Physiology
- Anatomy
- Aetiology
- Treatment

Starling principle

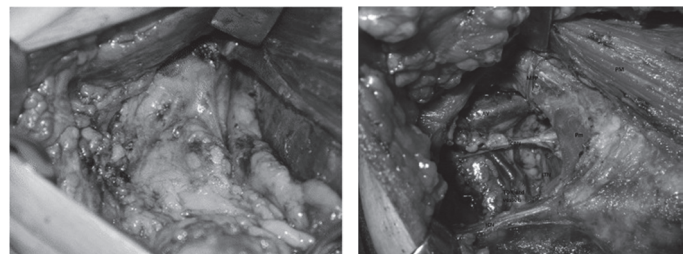


Axillary venous congestion

- Anomalous pectoralis minor
- Thoracic outlet syndrome
- Thrombosis
- Pancoast tumour
- Scarring
 - Fractured clavicle
 - Nodal clearance +/- radiotherapy

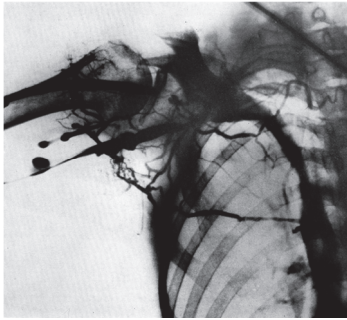


Axillary dissection

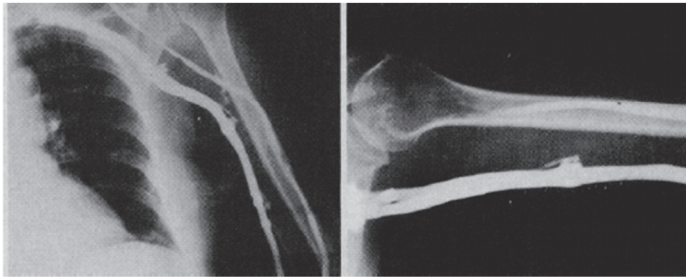
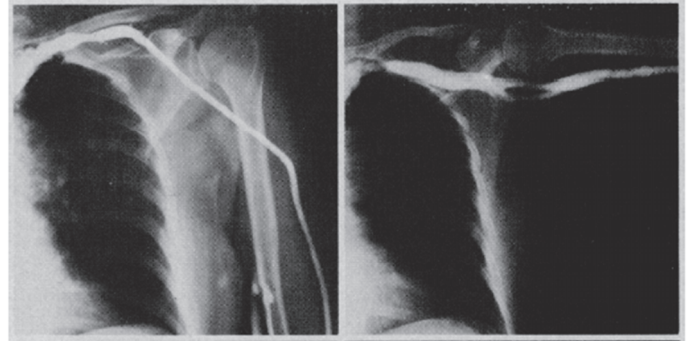


Venous obstruction after axillary clearance

- Hughes BJS 1966 – 16/19 with lymphoedema had venous obstruction
- Arnulff Vasc Surg 1973 – 8/13 cases, lymphoedema resolved after scar release



Larson – Arch Surg 1973

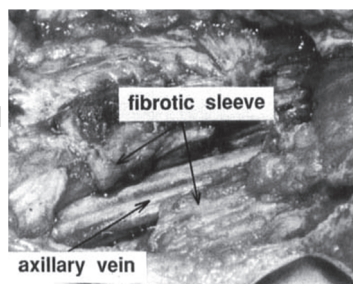


Larson's findings

- 14 postmastectomy oedema patients
 - In adduction, axillary vein normal in 4, narrowed in 3, obstructed in 7
 - In abduction, 9 cases normal, 4 cases distorted, 1 not visualised
 - 8 underwent scar release – 5 excellent result with minimal oedema postop

Segerstrom 1991

- Hypothesis – retracting scar tissue around vein contributes to brachial oedema



Segerstrom results

Table I. Oedema expressed as difference in volume between affected and contralateral arms

Volume (ml)	No. of patients	
	Before operation	After operation
< 150	0	5
151–300	1	8
301–450	8	4
451–600	4	0
> 600	7	3

Blood flow in axillary vessels after dissection

Mean blood flow velocity (cm/s)—G1	Ipsilateral	Contralateral	P value
Axillary artery	11.16 (1.67)	8.33 (0.75)	<0.0001*
Axillary vein	7.33 (1.67)	3.83 (0.83)	<0.0001*
Brachial artery	16.50 (3.08)	15.83 (2.33)	<0.0001*
Brachial vein	3.66 (0.34)	2.83 (0.67)	<0.0001*

Values expressed as median and interquartile range

* P < 0.05


- Mattheus – breast cancer res treat 2011

Becker – Annals Surgery 2006

- Long-term results following microsurgical lymph node transfer
 - 24 patients BCRL
 - Fibrotic muscular and burned tissue were dissected and adhesions released from axillary vessels
 - Lymph nodes from groin
 - 10 normal, 6 <50% reduction, 6 >50%, 2 unchanged

Delayed breast reconstruction

- Objective improvement in upper limb lymphoedema following ipsilateral latissimus dorsi pedicled flap breast reconstruction – a case series and review of the literature. Abbas Kan *et al.* J Plast Reconstr Aesthetic Surg 2011



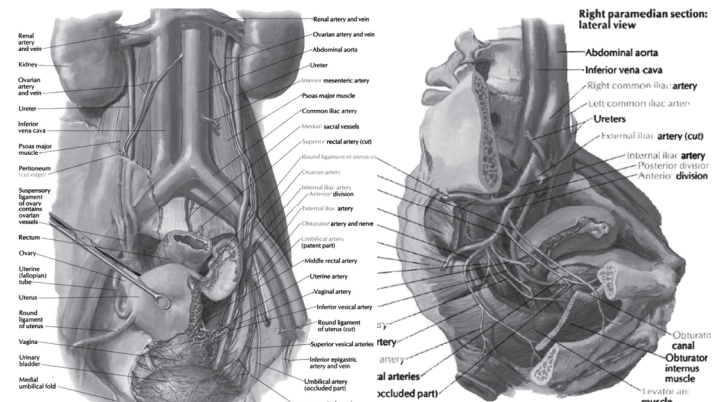
Positive impact of delayed breast reconstruction on breast-cancer treatment-related arm lymphoedema. Blanchard *et al* JPRAS 2012

Release of scar tissue or new lymphatic drainage????

Vandermeeren & Belgrado

- Release of axillary scarring & lipofilling
- Ongoing series of patients
- Positive adduction/compression test
- No garments 1 week preop & 2 weeks postop
- Volume measurements
- Demonstrates a volume reduction postop

Pelvic anatomy



Iliac vein congestion

- May Thurner (Cockett's) Syndrome
- Bladder distension
- Faecal impaction
- Pregnancy
- Renal transplant
- Endometriosis
- Hip arthroplasty
- Aortic aneurysm
- Retroperitoneal fibrosis
- Rheumatoid cyst
- Spondylolisthesis
- Thrombosis
- Post-thrombotic scarring
- Post-surgical scarring

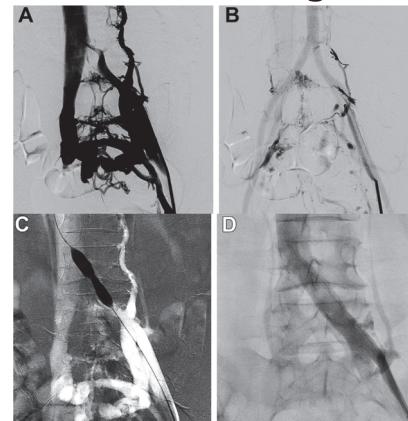
May-Thurner syndrome

- First described in 1908 by McMurrich
- Anatomically by May & Thurner in 1957
- Clinically by Cockett & Thomas in 1965
- Left iliac vein compressed between right iliac artery & 5th lumbar vertebra
- Rarely right side can be affected
- 50% of population may have degree of LIVC

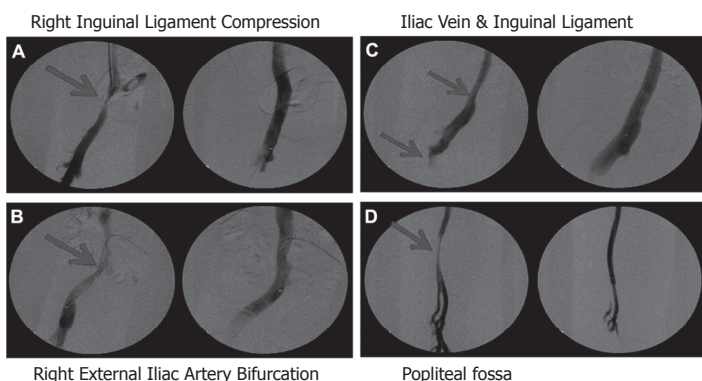
Diagnosis

- History & examination
 - Adolescence, pregnancy, postmenopause
 - Leg oedema, DVT, Phlebitis, Chronic Venous Insufficiency
- Imaging – US, CT, MRI, Venogram
 - >50% luminal narrowing or extensive intravascular webs
 - Hypogastric or Retroperitoneal collateralization

Endovascular stenting



Rollo 2017
J Vasc Surg
Venous
Lymphat
Disord



Garrie 2017 Ann Vasc Surg

Summary

- Multiple aetiologies for oedema secondary to upper/lower limb venous obstruction
- Surgical release or endovascular stenting effective
- Compression beneficial

Daily mail article 2012

- The amazing three-in-one cancer operation; it rebuilds your breast, gives you a tummy tuck AND cures swollen, aching arms
- 'I think the lymph node transfer started working immediately. I woke up the morning after the operation... and could easily slip my wedding ring on and off – before I couldn't budge it'
- 'A few days later...measured ... Both arms were the same size: the swelling had gone'

Thank you

