

## Lymphatic drainage of the upper limb. Substitution lymphatic pathways.

## Drainage lymphatique du membre supérieur. Voies lymphatiques de dérivation.

A. LEDUC \*, I. CAPLAN \*\* (†), O. LEDUC \*\*\*

\* *Vrije Universiteit Brussel - Université Libre de Bruxelles.*

\*\* *Universidad Buenos-Aires (1933-1992).*

\*\*\* *Université Libre de Bruxelles.*

### RÉSUMÉ

Des études cliniques ont montré l'existence de voies lymphatiques de suppléance. Ces voies sont susceptibles de détourner le cours de la lymphe.

Les auteurs ont étudié l'existence des voies de suppléance à partir de 300 cadavres humains.

L'échantillonnage est composé de 269 fœtus (de 7 à 9 mois), de 8 enfants (de 1 à 3 ans) et de 23 cadavres adultes (de 35 à 71 ans).

Les voies de dérivation qui ont été isolées sont représentées à la face antérieure par la voie céphalique ou de Mascagni (70 % des cas) et à la face postérieure par la voie tricipitale ainsi que les voies dorsales.

La voie tricipitale ou voie de Caplan se rend à un secteur ganglionnaire scapulaire superficiel tandis que les voies de dérivation par la face dorsale du tronc se rendent respectivement aux secteurs supra-claviculaires homo- (36 %) et contro-latéral (20 %) ainsi qu'au secteur axillaire contro-latéral (56 %).

### INTRODUCTION

The present study was undertaken with the purpose of providing better anatomical basis to the clinical care of upper limb lymphoedema which is one of the most important postoperative complication of breast surgery. In several cases, lymphoedema can reach such severe forms that it provokes partial or complete invalidation of the affected limbs. Physical therapy undoubtedly represents the most classical treatment of that affection thanks to different techniques enabling a better lymph flow in residual pathways, not affected by the intervention (4).

Previous in vivo studies performed in animals have provided good evidence for the possible existence of substitution pathways capable of diverting the normal course of lymph (4). With the purpose of disclosing substitution lymphatic pathways of the upper limb, we have therefore decided to examine the possible existence of anastomotic channels between the normal lymphatic pathways of the upper limb and those of dorsal cutaneous areas of the shoulder and posterior thoracic regions. The knowledge of such substitution pathways may be essential to human pathology since they can either prevent oedema formation or contribute to the regression of an already established lymphoedema.

### MATERIAL AND METHOD (1, 3, 6)

The experiments have been performed on 300 human bodies including 269 fetuses (from 7 to 9 months), 8 children (from 1 to 3 years old) and 23 adults (from 35 to 71 years old). In 250 of them, injections were made in different superficial and deep topographic areas of the upper limb; 50 were injected in cutaneous dorsal areas of the posterior scapular and upper thoracic regions.

The right side was injected in 136 cases and the left side in 164 cases. Formalin-fixed bodies have been avoided since they usually don't provide good results.

All observations have been gathered in the Department of Motor Revalidation of the Faculty of Medicine and Pharmacy of the "Vrije Universiteit Brussel" and in the Anatomical Research Department of the 2d chair of Normal Anatomy of the Faculty of Medicine of the University of Buenos Aires.

### TECHNIQUE OF INJECTION

#### A. The dye

The dye is the same as that recommended by GEROTA (1), but without ether addition. Several other dyes have been used such as the emerald green and the scarlet red.

Each dye is dissolved into terpentine and the solution is filtered twice. A few minutes before injection, the staining mass is heated up to about 40°C in a double boiler.

Key words : Lymphatics, lymphatic drainage, upper limb.

Reprints request to :

Prof. A. Leduc

Fac. of Med.

103, Laarbeeklaan, 1090 Brussels

Belgium.

two different kinds of syringes have been used : insulin injection - like glass syringes and metallic syringes with a carpule as those used by odontologists. The latter have our preference.

### C. Pretreatment of the material

As the unfixed material used is nearly always frozen, the injection areas have first been thawed out through 20 to 30 minutes exposure to a 200 W lamplight placed at a distance of 10 to 20 cm from the skin. More recently, the use of infra-red lamps have permitted quicker results.

### D. The injection areas

Most injections in the upper limb have been made in cutaneous areas of the digits, in joints and in a few cases in muscular structures. In the back, the injection was made along a vertical paracostovertebral line extending from the second to the tenth rib. When two injections are made in the back of the same subject, different dyes have been used in order to distinguish the lymphatic pathways of either sides and to be able to detect crossed pathways.

The injection was always performed slowly and gently in order to prevent the rupture of lymphatic channels. A slight massage with the tip of the fingers helps the diffusion of the staining mass through the interstitial space.

### E. The amount of injected mass

One to two ml. according to the subject's shape have been found sufficient for a successful preparation. When it is performed in superficial areas, a successful injection is immediately followed by the staining of a dense network of fine capillaries.

### F. Fixation of the injected material

After checking that the injection has been successful as revealed by the presence of stain in the lymph vessels and ganglia, the preparation is dipped into 40 % formalin, which precipitates the dye within the lymphatic network and allows an easier observation. It is then transferred for 12 to 24 hours into hydrogen peroxide (100 volumes) which bleaches all tissues with the exception of the stained parts.

## RESULTS

### 1) The lymphatic system of the upper limb

The lymph vessels and ganglia of the upper limb can be divided into superficial and deep systems running on either sides of the superficial aponeurotic sheath. The superficial or supraaponeurotic system contains a great number of collecting vessels (7, 8). Well protected by the subcutaneous fatty tissues, they run aside the superficial blood vessels and finally reach the ganglionic groups of the axilla and, for some of them, the supraclavicular or the posterior scapular ganglia. The lymph vessels of the deep or subaponeurotic systems are less numerous and run along with the deep neurovascular channels of the upper limb. They end generally in the different ganglionic groups and chains of the axilla.

Only the superficial lymph system will be examined here : only their anastomotic relationship with the " posterior " or " posterior scapular " pathways and therefore may contribute to create substitution pathways.

All lymph vessels originate in regional networks present in the dermis and superficial aponeurosis which therefore represent the walls of the superficial lymphatic space where the collecting vessels run in parallel with the supraaponeurotic blood vessels. Two lymphatic pathways can be recognized in that space : a subdermal pathway composed of numerous very fine and collecting vessels which can be easily ruptured by unexperienced investigators and a subaponeurotic pathway composed of large collecting vessels located beneath the aponeurosis, not or poorly visible through the skin but which can be easily dissected out.

Four well-defined primary pathways run from the hand to the elbow where they divide into four secondary terminal pathways 3 anterior and 1 posterior.

The four primary lymphatic pathways (2 anterior and 2 posterior) become divided into :

- a) anterior radial or anterolateral pathway ;
- b) anterior ulnar or anteromedial pathway ;
- c) posterior radial or posterolateral pathway ;
- d) posterior ulnar or posteromedial pathway.

The four secondary lymphatic pathways (3 anterior and 1 posterior) themselves divide into :

- a) anterior or bicipital pathway ;
- b) medial or basilic pathway ;
- c) lateral or cephalic pathway ;
- d) posterior or tricipital pathway.

Each pathway will now be submitted to detailed descriptive analysis.

### B. Descriptive analysis

#### B.1. Primary pathways

- a) *The anterior radial or anterolateral pathway*

It runs obliquely from the proximal part of the hand to the elbow, parallel to the vena radialis superficialis. There the anterolateral pathway divides into 3 terminal secondary pathways : medial, anterior and lateral. No ganglion could be found along this collecting pathway which drains the skin of the thumb, of the thenarian area and of the anterolateral part of the forearm. In the middle and superior part of its course, the anterolateral pathway is joined by the posterolateral or posterior radial pathway.

- b) *The anterior ulnar or anteromedial pathway*

This pathway extends from the hypothenar eminence to the elbow where it divides into 2 to 3 secondary terminal pathways running on the medial and anterior aspects of the arm. Less obliquely oriented than the anterior radial pathway, the anterior ulnar pathway accompanies the vena basilica and regularly presents a ganglionic group located in the proximal one third of the forearm. The anteromedial pathway drains the skin of digit V, of the hypothenarian area and of the anterolateral territory of the forearm. In its middle and superior parts it receives numerous collecting vessels from the posteromedial or posterior ulnar pathway.

- c) *The posterior radial or posterolateral pathway*

Extending from the proximal part of the dorsal aspect of the fingers, the posterior radial pathway runs through the anterior aspect of the forearm, elbow and arm where it contributes to form 2 out of the 3 terminal secondary pathways : the lateral and the anterior.

posteromedial pathway, the posterolateral pathway forms the secondary posterior pathway of the arm. The number of its collecting vessels varies from 5 to 12.

The posterolateral pathway represents the only lymphatic outflow which realizes a true anastomotic network between the dorsum of the hand and the proximal part of the forearm; there it divides into 2 posterior pathways. It receives the lymph from the skin of all five fingers, from the dorsum of the hand and from the posterolateral territory of the forearm. No ganglion was observed along its course.

d) *The posterior ulnar or posteromedial pathway*

Similarly with the posterolateral one, the posteromedial pathway starts from the proximal end of the dorsal aspect of the fingers, runs through the dorsum of the hand and wrist and reaches the proximal one third of the forearm. Thence, both posterior pathways of the forearm continue in the direction of the anterior aspect of the forearm and arm where they join the anteromedial or anterior ulnar pathway which, in the elbow area contributes to the formation of 2 to 3 secondary terminal pathways (anterior and medial). The posterior ulnar pathway is usually well developed, the number of its constituent vessels varying from 5 to 14. Like the posterolateral pathway, it gives origin to the posterior lymphatic outflow of the arm.

B.2. *The secondary lymphatic pathways*

B.2.1. *Anterior pathways*

a) *The anterior bicipital pathway*

In relation with the anterior aspect of the muscle biceps brachii, the anterior bicipital pathway drains four primary lymphatic pathways originating from the hand and forearm. It is composed of 8 to 15 collecting vessels. Obliquely directed from lateral to medial, it extends from the elbow up to the basis of the axilla. There it goes through the superficial aponeurosis and joins the different axillary lymph chains.

A single ganglion located 2 cm below the axillary basis on the anteromedial aspect of the superior one third of the arm was found in one case; to the best of our knowledge, it was never mentioned before.

b) *The anteromedial or basilic pathway*

Closely related to the basilic vein and to the medial bicipital groove, the anteromedial pathway receives the anterior and posterior ulnar primary pathways originating from the arm and forearm. In a few cases, the anterior and posterior radial outflows were also found ending in the basilic pathway. The basilic pathway is usually represented by 3 to 6 collecting vessels. Their course may follow two different ways. The first one accompanies the basilic vein in the canalis brachialis and reaches the deep ganglia of the axillary region by running parallel to the humeral blood vessels; the ganglia of the basilic chain or of the humeral chain are frequently found along that pathway. The vessels following the second course run superficially in the medial bicipital groove and cross the superficial aponeurosis of the axillary basis where they also join the axillary ganglionic chains. In one case, they were found associated with a single ganglion superficially located in the angle between the muscles triceps (*caput longum*) and latissimus dorsi. This ganglion had so far never been described.

c) *The anterolateral or cephalic pathway*

Closely associated with the cephalic vein, the anterolateral or cephalic pathway prolongs the antero- and posterolateral pri-

mary pathways originating from the hand and forearm. It is a constant lymphatic channel which starts in the inferior one third of the arm, successively runs in the lateral bicipital and deltopectoral grooves before reaching the trigonum clavipectoralis. There the collecting vessels may follow three different routes: (1) along the cephalic vein towards the ganglia of the axillary chain, (2) a superficial one which crosses the outer aspect of the clavicle and reaches the transverse cervical ganglionic chain (this route was described by MASCAGNI (5) and later on by SAPPEY (10) (fig. 1); (3) another route ending in the claviculopectoral group of the cephalic chain near the deep bending of the vein; some of its collecting vessels follow the cephalic vein and end in the axillary ganglia, others reach the superclavicular ganglionic chain after crossing the clavicle superficially. The variants (2) and (3) play a decisive role in the surgery of the breast cancer, they ought to be spared during complete or subtotal mastectomy and surgical exploration should be avoided in that area.

Similarly, if the patient receives pre- or postsurgical radiotherapy, the deltopectoral area should be protected, if possible, by lead plates in order to avoid the destruction of the unique possibility of lymph drainage of the upper limb. This drainage can contribute to suppress or alleviate the lymphoedema which might appear thereafter.

B.2.2. *The posterior or tricipital pathway* (fig. 2)

Closely associated with the muscle triceps brachii, this pathway starts from the upper one third of the back of the forearm; according to the case it may be a continuation of the posterior ulnar, of the posterior radial or of both of this primary lymphatic pathways. It is obliquely directed from the lateral to the medial part of the dorsal aspect of the arm and reaches the axillary ganglia. In four cases, however, the tricipital pathway followed the delto-tricipital groove and reached a ganglion located on the muscle teres major belonging to the inferior scapular chain. In one single case, a lymphatic vessel was found running from that ganglion to the posterior scapular chain. A ganglion so far not mentioned was found along that pathway in the angle between the muscles triceps brachii and latissimus dorsi. In another case, a direct lymphatic communication was found between the superficial dorsal network of the arm and that of the posterior thoracic region.

The knowledge of the tricipital pathway is of tremendous importance in the interpretation of the lymphatic drainage after mastectomy.

2) The subcutaneous lymph vessels of the dorsal thoracic wall

A. *Homolateral lymphatic pathways* (figs. 3 and 4)

Two different kinds of well defined lymphatic pathways have been revealed after injection of GEROTA's (1) mass along the spinal border of the scapula between the second and the tenth rib: homolateral and contralateral pathways. They can be distinguished by their topographically distinct regional and extraregional courses.

Four homolateral pathways can be recognized and were named according to their course:

- 1) the axillary pathway,
- 2) the supraclavicular pathway,
- 3) the dorsal or dorsoscapular pathway,
- 4) the posterior intercostal pathway.

They can be described as follows.

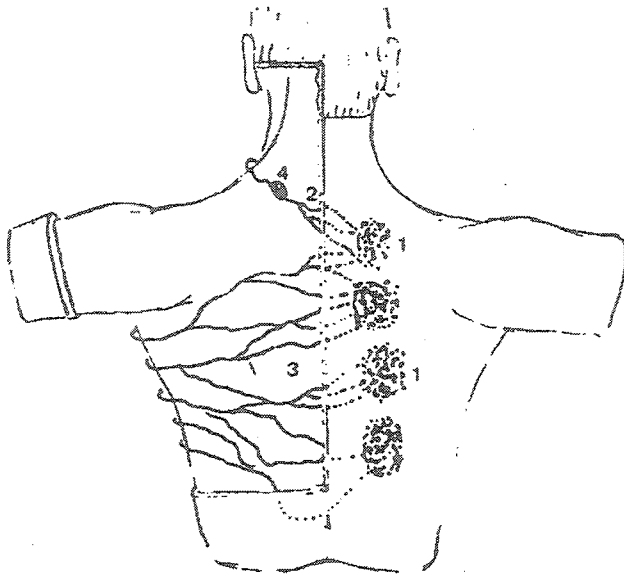


Fig. 5 a

*Superficial contro-lateral pathways*

1. injections
2. supraclavicular pathway
3. axillary pathway
4. superficial node.

*Voies contralatérales superficielles*

1. injection
2. voie supraclaviculaire
3. voie axillaire
4. ganglion superficiel.




Fig. 5 b

*Supraclavicular pathway - Voie supraclaviculaire*

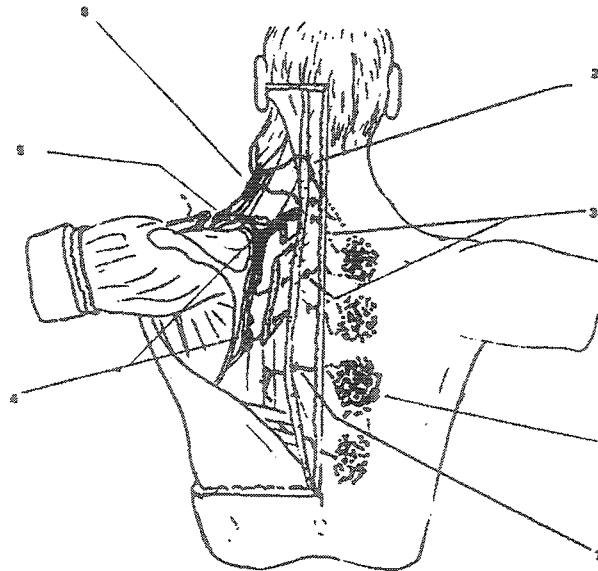
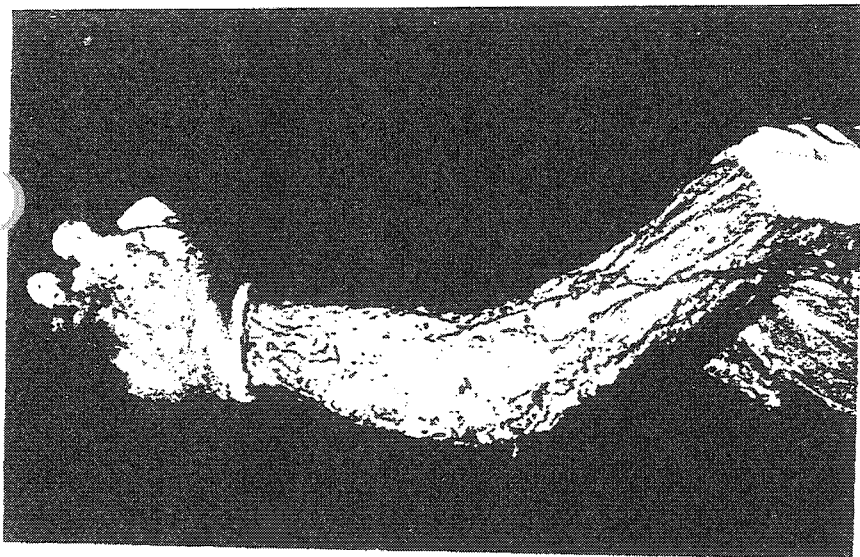


Fig. 6

*Deep controlateral pathways - Voies contralatérales profondes*

1. injection
2. supra-clavicular pathway  
voie supraclaviculaire
3. dorso-scapular pathway  
voie dorsoscapulaire
4. posterior scapular chain  
chaîne scapulaire postérieure
5. deep transverse  
chaîne transverse profonde
6. cervical jugular node  
ganglion cervical jugulaire
7. posterior intercostal pathway.  
voie intercostale postérieure.



4 Fig.2

The tricipital pathway  
or the "CAPLAN's pathway".

This proposal was introduced by  
Profs CUICCI and LEDUC A.  
during the Int. Congr. of Phlebology  
and Lymphology in Tucuman  
(Argentine 1993)  
and was accepted.

La voie tricipitale ou "voie de CAPLAN".

Cette proposition introduite par les  
Prof. CUICCI et LEDUC a été acceptée  
lors du Congrès International de Phlébologie  
et Lymphologie  
de Tucuman (Argentine, 1993).

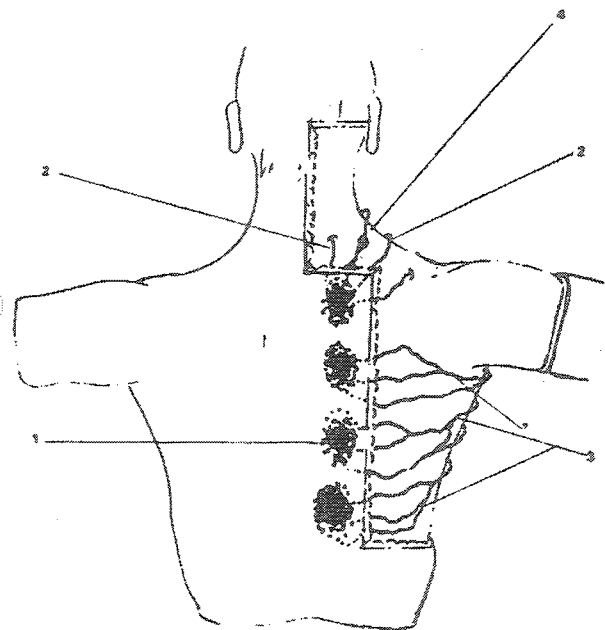


Fig. 3

Homolateral superficial lymphatic pathways

1. injection
2. supra-clavicular pathway
3. axillary pathway
4. superficial lymphnode.

Voies lymphatiques superficielles homolatérales

1. injection
2. voie supraclaviculaire
3. voie axillaire
4. ganglion superficiel

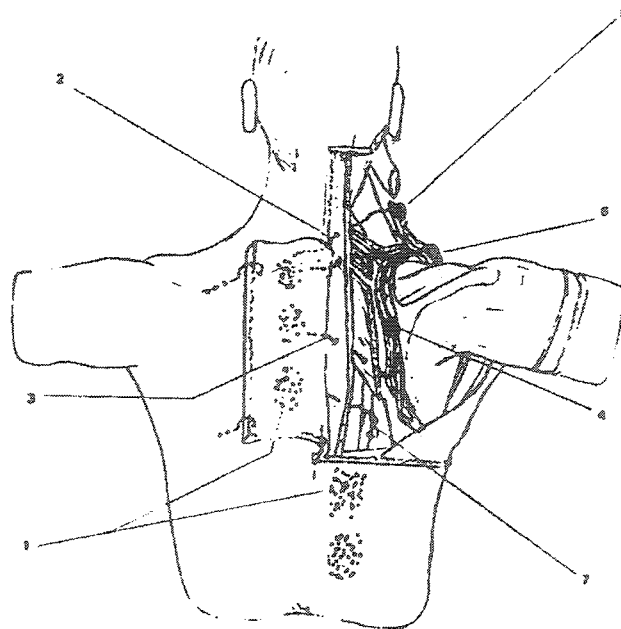


Fig. 4

Homolateral deep lymphatic pathways

1. injections
2. supraclavicular pathway
3. dorso-scapular posterior pathway
4. scapular chain
5. jugular node
6. deep transverse cervical chain
7. posterior intercostal pathway.

Voies lymphatiques profondes homolatérales

1. injection
2. voie supraclaviculaire
3. voie dorsoscapulaire postérieure
4. chaîne scapulaire
5. ganglion jugulaire
6. chaîne normale transverse profonde
7. voie intercostale postérieure.

It is the main superficial lymph outflow and was found constant. Seven to 12 collecting vessels are converging toward the axilla where they reach different ganglionic chains, particularly the external mammary chain (92 %), the inferior subscapular chain (84 %) and the axillary chain (32 %).

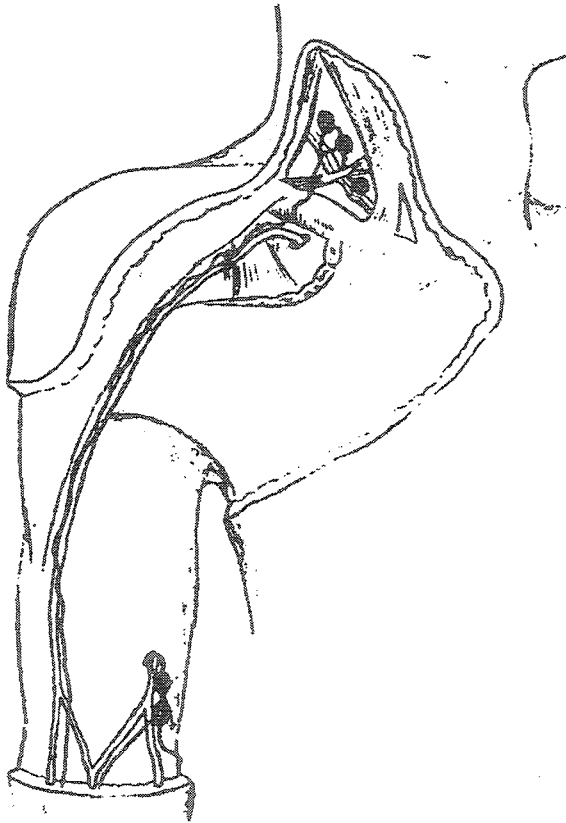
2) *The supraclavicular pathway*

It represents the second substitution pathway of the superficial and deep lymphatic drainage originating from the dorsal cutaneous component of the upper thorax. It was found present in 36 % of the cases and generally includes 1 to 4 collecting lymph vessels running towards the neck either superficially or through the muscle trapezius. In either case, they end in the deep trans-

verse cervical chain located in the supraclavicular area. One or two ganglia are usually found associated with the superficial vessels and take place in front of the muscle at the level of the 7th cervical vertebra.

3) *The dorsal or dorsoscapular pathway*

It is the third substitution pathway of the deep lymphatic network in this area. Observed in 36 % of the cases, it is composed of 1 to 4 collecting vessels which after a short subcutaneous course penetrate across the superficial aponeurosis and run within the muscle trapezius between the 2d and 5th thoracic vertebrae. They may then follow one of the two following routes : the subtrapezian or the subrhomboidal ones.




◀ Fig. 1 a

Fig. 1 b

*Possibilities described by MASCAGNI :*  
 a. directly to the transverse cervical ganglionic chain ;  
 b. indirectly along a preclavicular node.

*Possibilités décrites par MASCAGNI :*  
 a. directement à la chaîne ganglionnaire cervicale transverse ;  
 b. indirectement à travers un ganglion préclaviculaire.



*subtrapezian pathway* runs *behind the muscle* trapezius and *in front of* the muscles rhomboid and levator scapulae, along with the dorsal superior artery, a branch of the cervical transverse artery. It is followed by 1 or 2 collecting vessels which may end in the posterior scapular or in the deep transverse cervical chain. They may also reach the fossa supraspinata through the posterior scapular chain. One or 2 ganglia have been observed in a few cases along the superior dorsal or the subtrapezian chain.

(b) *The subrhomboidal pathway* is followed by one or two collecting vessels which in different places were found crossing the muscles trapezius and teres major before ending in the scapular chain satellite of the posterior scapular vessels. The latter runs along the spinal border of the scapula. This chain receives the lymph from the inferior scapular ganglia representing the posterior lymphatic drainage from the upper limb through the third substitution pathway. This route is only rarely used.

#### 4) *The posterior intercostal pathway*

It represents the fourth deep drainage route from the posterior cutaneous thoracic region extending from the 6th to the 12th rib. Present in 24 % of the cases, its collecting vessels rapidly go across the muscle trapezius or sometimes across the muscle rhomboid major before penetrating the deep intermuscular spaces between the thoracic portions of the muscles longissimus, iliocostalis and semispinosus. They usually accompany the dorsal perforating branches of the posterior intercostal vessels. Once in the intercostal space, the vessels end in the posterior intercostal chain which itself reaches the thoracic duct. One or two ganglia have been found associated with the dorsospinal perforating vessels.

#### Controlateral pathways (figs. 5 and 6)

In 76 % of the cases collecting lymphatic vessels originating from the posterior cutaneous thoracic region were found crossing the midline and reaching one of the following 4 controlateral substitution pathways: the axillary pathway, the supraclavicular pathway, the dorsoscapular pathway or the posterior intercostal pathway. They can be described as follows.

#### 1) *The axillary pathway*

It is the most important controlateral pathway. Present in 56 % of the cases, it is represented by 2 to 10 collecting vessels which cross the dorsal midline superficially and reach the lateral boundary of the posterior axillary wall. There they penetrate the axillary basal aponeurosis and join preferentially the inferior scapular and external mammary chains or, less frequently, the chain of the axillary vein.

#### 2) *The supraclavicular pathway*

Present in 20 % of the cases, it is represented by 1 or 2 collecting vessels which after crossing the dorsal midline reach the basis of the neck and continue in front of the muscle trapezius. One or two ganglia can be found along their course at the surface of the muscle. They finally reach the controlateral supraclavicular area where they come to end either in the superficial transverse cervical chain, in the posterior jugular chain or in the deep transverse cervical chain. In 10 % of the cases, one or two collecting vessels of the supraclavicular pathway run through the muscle trapezius and join the deep transverse cervical chain.

#### 3) *The dorsal or dorsoscapular pathway*

This deep controlateral pathway was found present in 16 % of the cases. It is represented by 1 or 2 collecting vessels which go across the dorsal midline, penetrate the heterolateral muscle

trapezius (thoracic part) and then follow either a subtrapezian or a subrhomboidal course. The *subtrapezian* course is generally composed of 1 or 2 collecting vessels which accompany superior dorsal vessels and join the deep transverse cervical chain. One or two ganglia were frequently found along their intermuscular course.

The *subrhomboidal* pathway goes through the space between the muscle rhomboides major and minor and reaches the posterior scapular chain along with the posterior scapular vessels near the spinal border of the scapula. Its collecting vessels drain the lymph from the inferior scapular chain which itself receives that from the dorsal aspect of the upper limb through the third substitution pathway. This latter situation is inconstant.

#### 4) *The posterior intercostal pathway*

The controlateral posterior intercostal pathway was found present in 4 % of the cases and therefore appears as the less frequent deep controlateral lymphatic pathway of the dorsal thoracic wall. It was represented by one single collecting vessel which goes across the dorsal midline and successively penetrates the muscles trapezius and rhomboid major (sometimes) before entering the intermuscular space between the muscles longissimus thoracis and semispinalis thoracis, along with dorsospinal perforating vessels originating from the posterior intercostal vessels. It finally ends into the posterior intercostal chain.

## CONCLUSIONS

Numerous potential substitution lymphatic pathways capable of collecting the lymph from the upper limb have been detected in this study. They are preferentially located on the dorsal aspect of the shoulder and represent interlymphatic anastomoses between the dorsal aspect of the arm and the posterior thoracic wall. These substitution pathways drain the lymph to homo- and controlateral ganglionic chains or to the thoracic duct, which represent normal lymphatic pathways.

After complete or partial axillary ganglionic removal, the substitution pathways can take in charge the whole lymphatic drainage from the upper limb. The "replacement" of normal by substitution pathways is not always immediate. It is often necessary to help the opening of anastomotic vessels through increasing the intralymphatic hydrostatic pressure by careful manipulation. The homo- and controlateral substitution pathways are usually represented by numerous collecting vessels grouped into definite pedicles.

## REFERENCES

1. GEROTA D.  
Zur Technik der Lymphogefässinjection.  
*Anat. Anz.*, 1896, 12, 216-224.
2. GRAY H.  
Gray's anatomy.  
*Longman Edit.*, London, 1973.
3. KUBIK S.  
Clinical anatomy of the lymphatic system.  
*Verh. Anat. Ges.*, 1975, 69, 109-116.
4. LEDUC A., LIEVENS P.  
Les anastomoses lympho-lymphatiques : incidences thérapeutiques.  
*Soc. Sc. Belg. Kin.*, Vol. IV, NI, 1976.
5. MASCAGNI P.  
Vasorum lymphaticorum corporis humani. Historia & Iconographia.  
*P. Carli Edit.*, Senis, 1787.
6. PAPAMILTIADES M.  
Injection of lymphatics with colored cedar oil, with plastic.  
*Stain Technol.*, 1961, 36, 241-246.
7. POIRIER P., CHARPY A.  
Traité d'anatomie humaine.  
*Masson Edit.*, Paris, 1899.
8. ROUVIERE H.  
Anatomie des lymphatiques de l'homme.  
*Masson Edit.*, Paris, 1932.
9. ROUVIERE H., VALETTE C.  
La pression lymphatique dans les collecteurs périphériques.  
*Bull. Acad. Méd.*, 1935, 114, 800-802.
10. SAPPEY S.  
Manuel d'anatomie descriptive et de préparations anatomiques.  
*Masson & Cie, Edit.*, Paris, 1850.
11. TESTUT L.  
Traité d'anatomie humaine.  
*G. Doin, Edit.*, Paris, 1931.