

NLN

NATIONAL LYMPHEDEMA NETWORK

LYMPH Link

Vol. 18, No. 1 January~March 2006

ISSN 1065-9951

Editor: LIZ GREGOR

Managing Editor: SASKIA R.J. THIADENS, RN

Graphics: MARCIA KRUSE
Cathedral City, CA

Editorial Committee: JANE ARMER, RN, PHD
MARCIA BECK, RN, CS, CMLDT
KATHLEEN FRANCIS, MD
BONNIE B. LASINSKI, MA, PT
CATHERINE M. TUppo, PT

NATIONAL LYMPHEDEMA NETWORK
Latham Square

1611 Telegraph Avenue, Suite 1111
Oakland, CA 94612-2138
Telephone 510-208-3200
Website www.lymphnet.org
E-mail nlm@lymphnet.org

The NLN Mission Statement

The mission of the NLN is to create awareness of lymphedema through education and to promote and support the availability of quality medical treatment for all individuals at risk for or affected by lymphedema.

The NLN is dedicated in:

- promoting research into the causes, prevention and treatment of lymphedema;
- securing adequate insurance coverage for medically necessary, safe and effective treatment;
- expanding the number and geographical distribution of lymphedema treatment facilities and certified therapists.

To achieve these goals, the NLN disseminates information about lymphedema to health care professionals so they can appropriately counsel their patients on its avoidance, and prescribe safe, effective treatment for those affected by this condition. The NLN also provides this information to the general public.

Lymphoscintigraphy: Its Role In Lymphedema Management

By Andrea L. Cheville, M.D.

This issue of *LymphLink* focuses on the benefits and challenges of imaging in the diagnosis and treatment of lymphedema. The focus of this article is on the specialized examination called **Lymphoscintigraphy**.

Lymphoscintigraphy (lim-fo-sin tigg'rah-fee) uses the injection of radioactive tracer to assess lymphatic structure and function. Similar to many nuclear medicine techniques, lymphoscintigraphy requires a special camera to create images based on the distribution and density of radioactive tracer that has accumulated in the tissues. Structures appear dark where tracer molecules have been densely absorbed and generated lots of counts. Images can be repeated at intervals ranging from minutes to hours to study the movement of tracer over time. Evaluation of repeated images permits us to make inferences about the function and structure of the lymphatic system.

Lymphoscintigraphy begins with the injection of radio-labeled tracer molecules into or just below the skin using a fine gauge needle. Controversy persists over where the tracer should be injected. Some diagnostic centers inject into the skin and other just below the skin¹. Sulfur colloid is a tracer molecule utilized widely for lymphoscintigraphy. The relatively large size of sulfur colloid molecules (<100 m) limits their absorption by blood capillaries². Their distribution on lymphoscintigraphic images is, therefore, specific to lymphatic structures; collectors, nodes and ducts.

Tracer is usually injected into the dorsal (top) surface of the hands or feet. However, it can be deposited anywhere within the body including breast, scalp, genitals, or internal organs, depending on the area of suspected lymphatic insufficiency. Tracer movement depends on the integrity of local lymph capillaries and vessels. Functioning lymphatics take up the tracer and transport it to regional lymph nodes. Tracer concentrates in the lymph nodes which appear as clusters of dark spots on lymphoscintigraphic images. Lymph drainage pathways may or may not be visible, depending on the rate of tracer transport, its

concentration in the vessels, and frequency with which images are obtained. Generally, only large lymphatics contain enough tracer to appear clearly on images. If the lymphatic system is sufficiently intact, the injected tracer will eventually enter the blood stream and appear in the liver, spleen, bladder and heart.

Lymphoscintigraphy reports typically offer qualitative information. They describe tracer movement through the regional and systemic lymphatics and may identify sites of diminished or absent movement. Locations of low count density presumably correspond to areas of functional insufficiency. Images with tracer present 2 to 24 hours after injection may suggest retrograde flow through lymph vessels, as well as diffusion of the tracer throughout the limb³. In such cases, the silhouette of the affected body parts often becomes visible.

Although it is less commonly and consistently reported, considerable quantitative information can also be gained. (Quantitative information is in numerical form and can be analyzed by statistical procedures.) Values that can be quantitatively measured include count reduction at the injection site, transit time to the lymph nodes, and time required for 50% of the tracer to be concentrated in the

Continued on page 2

In This Issue

PRESIDENT'S MESSAGE	3
CASE HISTORY	4
LE LEGISLATIVE SUMMARY	7
RESEARCH PERSPECTIVES	9
RESOURCE GUIDE <i>8 page outline</i>	11
SUPPORT GROUPS	17
NEWS & NOTES	19
QUESTION CORNER	22
EDUCATION CORNER	24
BECOME AN NLN SUPPORTER	27

Lymphoscintigraphy...

Continued from cover page

nodes. Repeated measurement allows calculation of tracer clearance rates. Clearance rates have been reported for unaffected individuals as well as patients with different stages of lymphedema⁴.

The clinical significance of this quantitative data is still unknown. As of now, they do not allow prediction of important clinical events such as lymphedema progression or cellulitic infection.

Lymphedema therapists may question whether lymphoscintigraphy images can reveal drainage

pathways for use in mobilizing stagnant lymph. Several limitations of lymphoscintigraphy should be considered when addressing this very reasonable question. First, only large lymph collectors that contain significant amounts of tracer will appear on the images. Small networks of collateral lymph vessels may never acquire sufficient count density to be seen. Second, it is important to remember that lymphoscintigraphy only displays tracer counts. If vessels, organs, bones, and other tissues do not absorb tracer, they will not be seen. Even when lymph drainage pathways are well visualized, the failure of lymphoscintigraphy to image surrounding anatomy makes it difficult to orient the pathways in anatomic planes. If more precise anatomic location is required, it is necessary to use radio-emitting external markers to identify the body landmarks.

The following case study shows how Lymphoscintigraphy can refine diagnoses and improve lymphedema treatment. It illustrates how the functional information gained from lymphoscintigraphy can alter the relevance of findings on conventional imaging. Structures that appear intact on imaging, like MRI, may prove to be functionally incompetent. Physiological tests, like lymphoscintigraphy, may provide little

information about structure. That is not their purpose. Rather, they allow us to make inferences about how systems function and to identify where functional integrity breaks down.

The patient was a 54-year-old woman with a history of bilateral breast cancer

volume increase. The patient was tentatively diagnosed with a muscle strain/sprain attributed to the increasing weight of her arm. Treatment consisted of analgesics, myofascial release and the initiation of phase I complete decongestive therapy (CDT).

The patient's neck pain worsened,

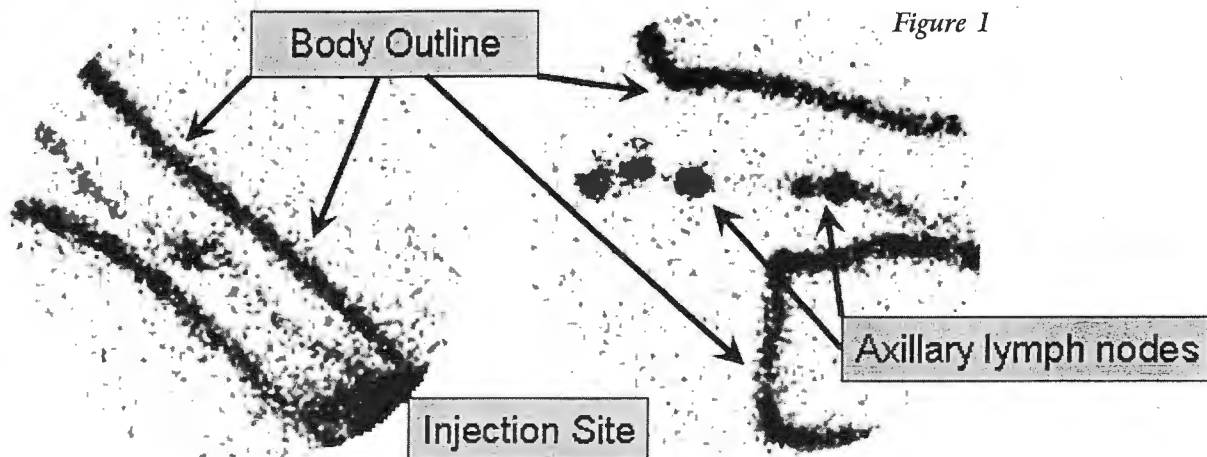
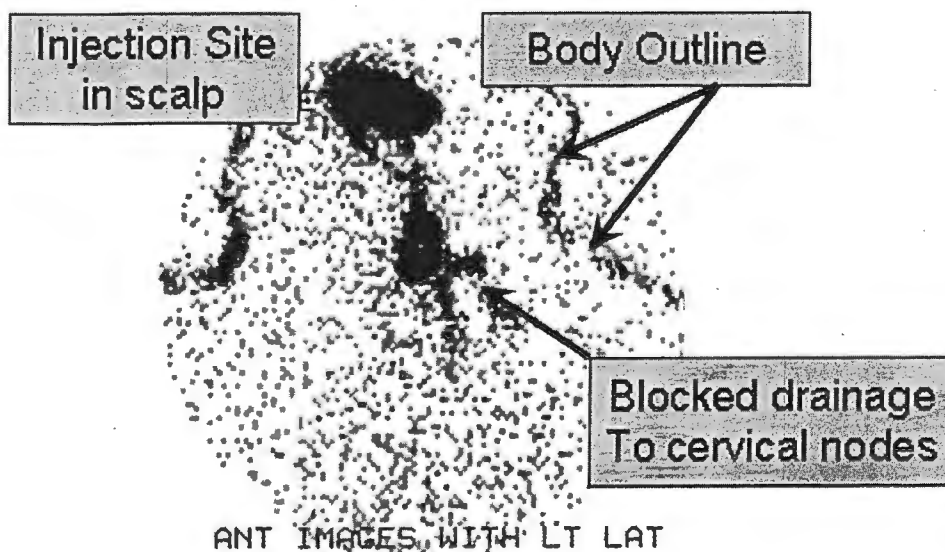


Figure 1

who presented with a two-month history of increasing right neck pain and arm swelling. She had undergone bilateral mastectomies and Level I & II axillary lymph node dissections, but was felt only to require radiation to her right axillary and supraclavicular lymph nodes. Despite persistent use of a Class I

despite a 21% reduction in arm volume over the following two weeks. Her therapist noted a steady increase in right supraclavicular swelling that appeared correlated with the degree of volume reduction. Given her history and persistent neck pain, an MRI was obtained to evaluate her right neck. The study was read as



compression sleeve, her right arm volume steadily increased. Physical examination revealed trigger points and taut bands throughout the right cervical musculature, fullness at the right neck base, no neurological deficits, and a 36% limb

normal. Therefore, therapy was continued with slight technical modifications and the initiation of opioid analgesics.

Despite a greater than 55% volume reduction, her pain and supraclavicular

Continued on page 23, column 2

rapidly absorbed into some of these highly active vessels and, as such, show a "clinical picture" of normalcy. Certainly, it is important to keep in mind that lymphedema is most often a clinical diagnosis, relying upon skilled assessment including history, visual features, and palpable (textural) presentation more than any other factors.

Another potential test that may indicate a false negative finding is called the Stemmer Sign. This test measures the textural change or skin thickening in the skin of the toes to verify whether or not protein rich fluid is stagnating in this area. Since lymphedema usually starts in the area farthest from the trunk, the toes and fingers are classically the first areas to show textural changes. The interesting fact however, similar to the false negative LAS reading, is that sometimes lymphedema chooses to spare the foot and toes, rendering a negative Stemmer sign. One must only look above the foot to see positive traits of lymphedema.

Steve Norton, CLT-LANA, is Director of The Norton School of Lymphatic Therapy, www.nortonschool.com.

Case History...

Continued from page 6

over the genital area and excellent skin care, and that she employ a dietary restriction of long-chain triglyceride. Only if she continues to be plagued by discomfort and drainage from chylous papules would other measures such as cautery, intralesional injection of sclerosing solution, or local laser treatment be offered.

Conclusion: The utilization of a combination of lymphoscintigraphy and MRI are important tools in determining advanced sclerosing techniques to be employed in the management of this patient's painful draining labial chylous papules. Use of these techniques also allowed for the recommendation to employ other methods for local control of these papules in the future, should conservative approaches fail to bring desired relief.

Paula J.B. Stewart, M.D., M.S., CLT-LANA, is Program Director of Cancer Rehab and Lymphedema Services at HealthSouth Lakeshore Rehabilitation Hospital in Birmingham, AL, and an active member of the NLN Medical Advisory Committee. Email: Paula.Stewart@healthsouth.com.

Lymphoscintigraphy...

Continued from page 2

swelling worsened. Two months after starting CDT, lymphoscintigraphy of the right arm was performed to assess her pain and neck swelling. Images (Figure 1) showed normal tracer movement without appreciable abnormalities. Therefore, a second lymphoscintigraphy was performed with tracer injected into her scalp to evaluate her cervical and supraclavicular lymphotome. A discrete blockage was apparent at the right neck base with overflow of lymph from the head and scalp into the supraclavicular soft tissue and upper extremity (Figure 2).

The patient's cervical MRI was then carefully reviewed. A previously noted focus of mild enhancement at the neck base gained greater significance. It was thought to represent a discrete area of radiation fibrosis. After non-invasive measures failed to reduce the patient's fibrosis, she elected to undergo surgical exploration. Several supraclavicular fibrotic bands were identified and lysed. Post-operatively, the patient reported a 60% decrement in her pain and reduced neck swelling.

This case illustrates how findings initially dismissed as insignificant on high-resolution images can acquire greater significance in light of the information provided by clinical evaluation and functional testing.

- 1 Szuba A, Shin WS, Strauss HW, Rockson S. The third circulation: radionuclide lymphoscintigraphy in the evaluation of lymphedema. *J Nucl Med.* 2003 Jan;44(1):43-57.
- 2 Hung JC, Wiseman GA, Wahner HW, Mullan BP, Taggart TR, Dunn WL. Filtered technetium-99m-sulfur colloid evaluated for lymphoscintigraphy. *J Nucl Med* 1995;36:1895-1901.
- 3 Larcos G, Foster DR. Interpretation of lymphoscintigrams in suspected lymphoedema: contribution of delayed images. *Nucl Med Commun.* 1995 Aug;16(8):683-6.
- 4 Weissleder H, Weissleder R. Lymphedema: evaluation of qualitative and quantitative lymphoscintigraphy in 238 patients. *Radiology.* 1988;167:729-735

Andrea Cheville, M.D., is Director of Cancer Rehabilitation and Assistant Professor, Department of Rehabilitation, University of Pennsylvania, Philadelphia, PA; Member of the NLN Medical Advisory Committee; and Board Member of LANA.

President's Message...

Continued from page 3

benefits of LAS and other techniques using the knowledge he has gained from his vast experiences working with Drs. Marlys and Charles Witte at the University of Arizona. With the rapid evolution, growth and awareness of the lymphatic system in the United States, we want to see more physicians adding lymphology, including these sophisticated imaging methods, into their existing practices.


We again have the opportunity to recognize the many courageous LE patients as well as their dedicated supporters, caregivers and treatment staff in the LE community on Lymphedema "D-Day," March 4, 2006. Please be sure to read the News & Notes section on page 21 for more information on how you can honor a deserving patient, therapist, or caregiver.

Let's start a fresh year with hopes of improved welfare for our many LE patients around the country and the world. If there's anything the NLN staff can do to assist you as a LE patient, professional, or advocate, as always, please do not hesitate to contact us.

LYPHHEDEMA THERAPY CERTIFICATION COURSES

At Klose Training and Consulting, we provide the highest quality Manual Lymph Drainage (MLD) and Complete Decongestive Therapy (CDT) training available in the U.S. We accomplish this high standard by drawing from many years of hands-on experience in the field, a constant monitoring of the latest developments in MLD/CDT treatment, and by providing our students the best educational materials available.

Klose Training & Consulting provides students:



- The most comprehensive package of study materials available anywhere incl. the Textbook of Lymphology by Profs. M. Foeldi, E. Foeldi and S. Kubik, Limb Volume Calculation Software, complete set of Lymphedema Bandage Materials, Lymphatic System Posters, Lymphedema Videotapes and much more.
- Expert Physician lectures on Diagnosis, Differential Diagnosis and Treatment of Lymphedema

- Ongoing postgraduate phone and e-mail support (help with difficult to treat patients)
- Free Therapist Directory (Website) listing
- Advanced & Review Courses

A complete listing of current courses are available on our website: www.klosetraining.com

KLOSE TRAINING & CONSULTING LLC
LYMPHEDEMA THERAPY CERTIFICATION COURSES

110 Highway 35 • Red Bank, New Jersey 07701
Toll free: 866-621-7888 • Telephone: 732-530-7888
Fax: 732-530-2802 • E-mail: info@klosetraining.com
www.klosetraining.com