

# Lipedema: A Clinical Entity Distinct from Lymphedema

George H. Rudkin, M.D., and Timothy A. Miller, M.D.

Los Angeles, Calif.

In a review of 250 cases of lymphedema of the lower extremity, 9 patients were noted to share unique similarities in their history and physical findings. Although these patients had mild swelling in their pretibial areas and were all referred with a diagnosis of lymphedema of the legs, their findings differed significantly from the usual patient with either congenital or acquired lymphedema. Notably, the lower extremity swelling was always bilateral and symmetrical in nature and never involved the feet. Skin changes characteristic of lymphedema were not found, and consistent fat pads were present anterior to the lateral malleoli in each patient. These findings are representative of a clinical entity known as lipedema, which is distinct from lymphedema and for which treatment may be different. (*Plast. Reconstr. Surg.* 94: 841, 1994.)

*Lymphedema* is the abnormal accumulation of protein-rich interstitial fluid within the skin and subcutaneous tissue due to lymphatic dysfunction. Lymphedema may be either congenital or acquired, and the diagnosis can be made on the basis of history and physical examination in the majority of patients. Treatment is conservative in the early stages of lymphedema, and many patients can be managed without surgical intervention. Surgery may be palliative for those with more advanced stages of the disease and may provide both functional and cosmetic improvement. We have previously reported our experience with skin and subcutaneous excision in the treatment of lymphedema.<sup>1,2</sup>

In a review of 250 patients with lymphedema, 9 patients were found to share unique findings in their histories and physical examinations that were atypical for lymphedema. These patients are thought to have a condition known as *lip-edema*, a lipodystrophy that may be confused with lymphedema.

## CLINICAL EXPERIENCE

All nine patients were women between the ages of 28 and 70 years. They presented with symmetrical enlargement of both legs that began at the ankle and extended proximally to the upper thighs. The enlargement in the lower extremities consistently first appeared in all patients in their teenage years or early in their third decade (13 to 23 years). This enlargement was perceived by most patients to be a combination of an increase of fatty tissue and swelling of the subcutaneous tissue. All patients had been told by physicians that their condition was "lymphedema."

Compressive stocking use was of little help in controlling the swelling in our patients and often caused considerable discomfort, particularly in the ankle area. Six of the nine patients had tried various diuretic therapy regimens without improvement. Although the patients reported variations in the swelling of the leg, it was always symmetrical, never massive in extent, and never involved the feet. None of the patients had difficulty putting on shoes. In four of the nine patients there was a family history of a similar condition affecting one father, two mothers, and one maternal grandmother.

Interestingly, eight of the nine patients complained of an unusual discomfort in the plantar surface of the foot, often described as a "tingling" or "burning" sensation. Efforts to treat this discomfort with anti-inflammatory medications had been attempted in four of the nine patients and was completely unsuccessful. The discomfort was aggravated by standing for pro-

longed periods of time and by wearing compressive stockings.

None of the patients gave a history of lymphangitis seen in patients with lymphedema or any other type of infection in the legs. Only two patients had a lymphangiogram, which in both instances showed a moderate dilation of the lymphatics and some tortuosity consistent with incompetent valves. The number of lymphatic collecting channels was, however, normal.

The physical findings in these nine patients, all women, were extraordinarily similar and always bilateral. Most striking was the abrupt increase in the thickness of the subcutaneous tissue presenting as a ring of fatty tissue just above the ankle (Fig. 1). The skin was soft in all patients, and the subcutaneous tissue proximal to the ankle contained increased amounts of soft but otherwise normal-appearing fatty tissue. There was 1/4+ edema in the pretibial area. In none of the patients was there dermal thickening or induration seen so commonly in patients with lymphedema. Notably, a consistent fat pad was always found just anterior to the lateral malleolus, with additional fatty tissue between the Achilles tendon and medial malleolus. Distal to the ankle, no edema was present; indeed, no abnormality of any kind could be identified in the foot.

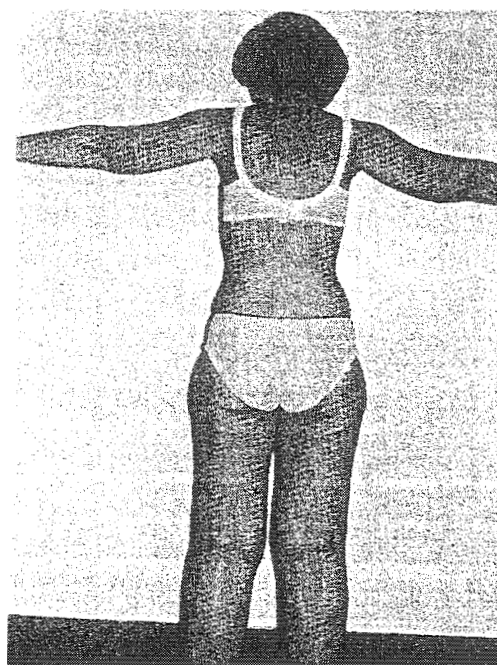
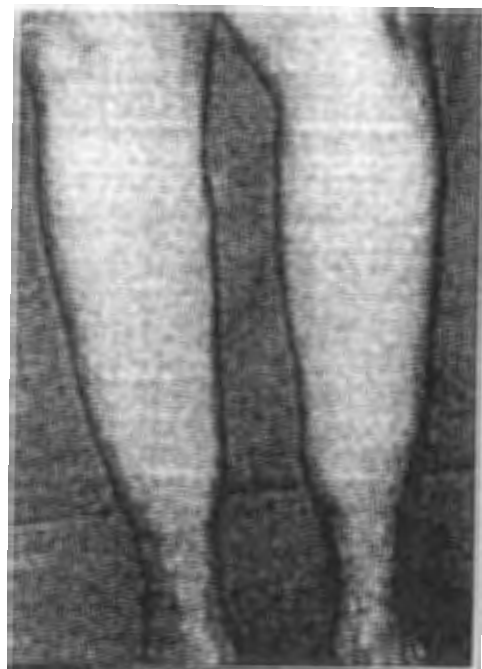


FIG. 1. Representative appearance of patients with lipedema. The enlargement of the subcutaneous tissue begins abruptly just above the level of the malleoli. In these patients, slight pitting pretibial edema exists. The skin appears to be normal, and the excessive subcutaneous fat is quite soft. Note the absence of edema in the foot and ankle and the symmetrical but disproportionate enlargement of the lower extremities.

#### SURGICAL TREATMENT

Three of the nine patients underwent surgical therapy consisting of skin and subcutaneous excision<sup>1,2</sup> (Figs. 2 and 3). Although there was significant postoperative improvement in the contour and size of the extremities of all three patients, one patient experienced postoperative swelling of the feet beginning within the first 2 months following surgery. This swelling did not exist preoperatively. In addition, there was an exacerbation of the burning sensation in the plantar aspect of the heel, although during the operative procedure the sural nerve was identified and not injured.

In an additional four patients, suction lipectomy was used effectively in conjunction with limited skin and subcutaneous excision (Fig. 4). Postoperatively, contour and size of the extremities were substantially improved. None of these four patients experienced postoperative swelling of the feet. The scars in these patients healed extremely well, unlike what is commonly seen in patients with lymphedema.

#### GROSS AND MICROSCOPIC FINDINGS

During all operative procedures, the subcutaneous fatty tissue in these patients was extremely soft, normal in consistency, and abun-

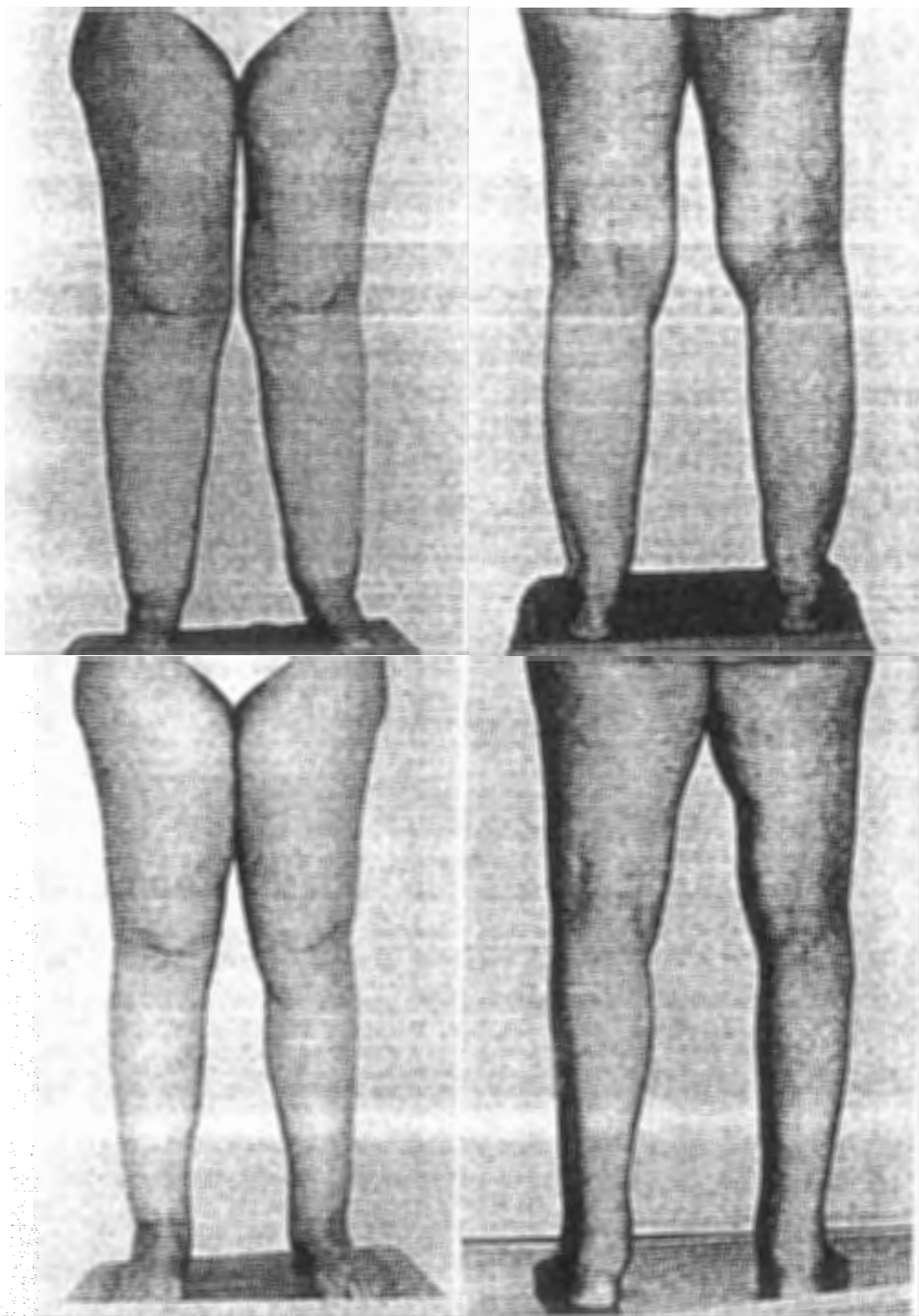


FIG. 2. Preoperative and 1-year postoperative photographs (anterior and posterior views) of a 65-year-old patient with moderate lipedema who underwent skin and subcutaneous excision.

dant. None of the fibrotic changes or lymph drainage from the wound so consistently observed in patients with lymphedema was observed.<sup>3</sup> Microscopic examination of the skin and subcutaneous tissue excised confirmed these clinical findings. There was minimal perivascular fibrotic change in the subcutaneous compartment so common in lymphedema

(Fig. 5). There was no dermal thickening, and the excessive subcutaneous tissue showed no histologic abnormality.

#### DISCUSSION

A review of the literature reveals little mention of this combination of clinical findings, with the exception of brief descriptions of a

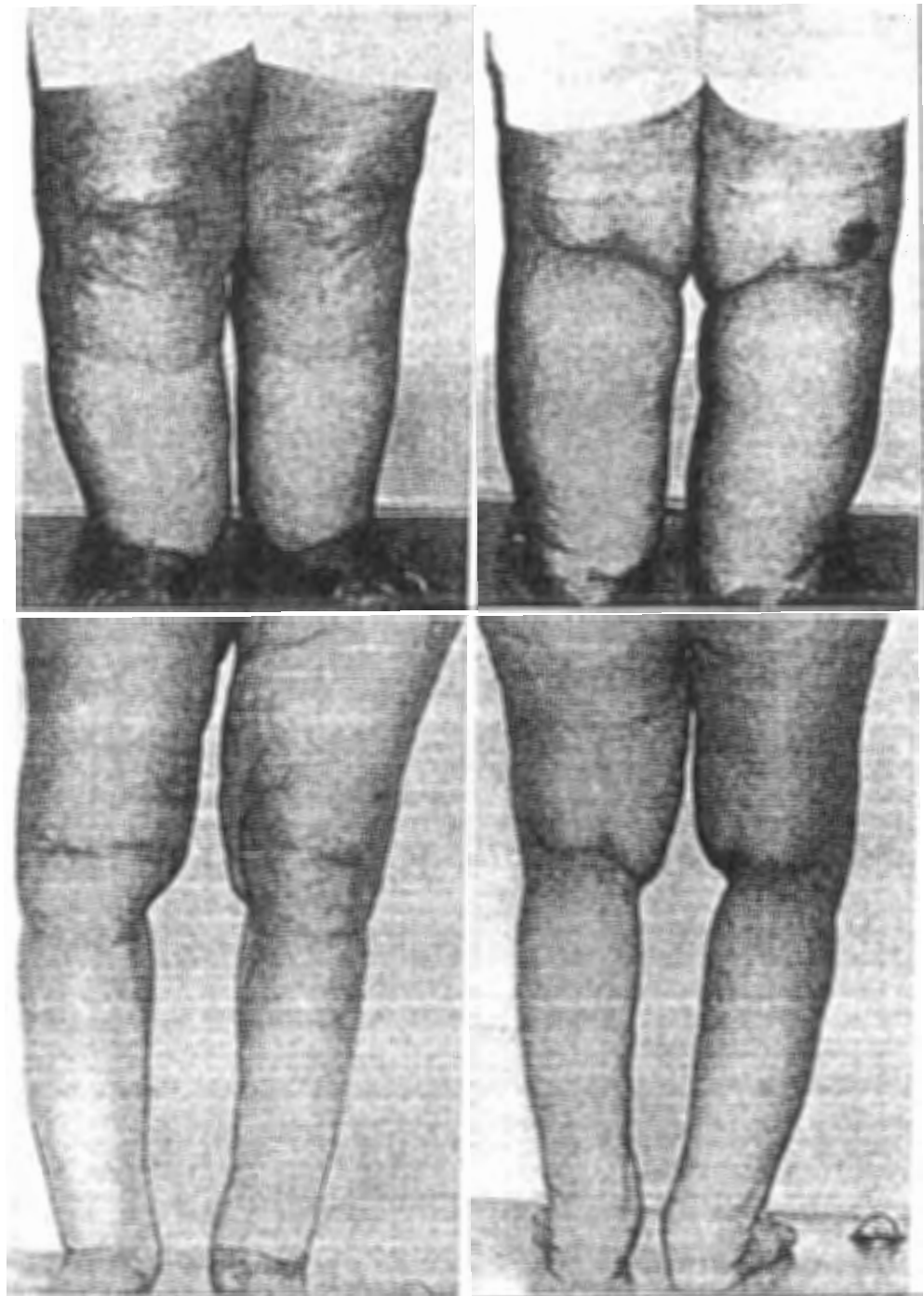


FIG. 3. Preoperative and postoperative photographs (anterior and posterior views) of a 70-year-old patient with lipedema. This patient was the only one in the series with significant obesity. Please note that although the legs are massively enlarged, the feet are not edematous. Postoperative photographs were taken 2 years after skin and subcutaneous excision.

condition termed *lipedema*.<sup>4</sup> This condition was first described by Allen and Hines<sup>4</sup> in 1940 as a "painful fat syndrome." They described a lipodystrophy with "subcutaneous deposition of fat in the buttocks and lower extremities and the accumulation of fluid in the legs (orthostatic

edema)." In a subsequent report,<sup>5</sup> they noted that patients afflicted with this condition had symmetrically enlarged legs and buttocks, with sparing of the feet; prominent malleolar fat pads were noted in some patients. The involvement of the lower extremities was described as

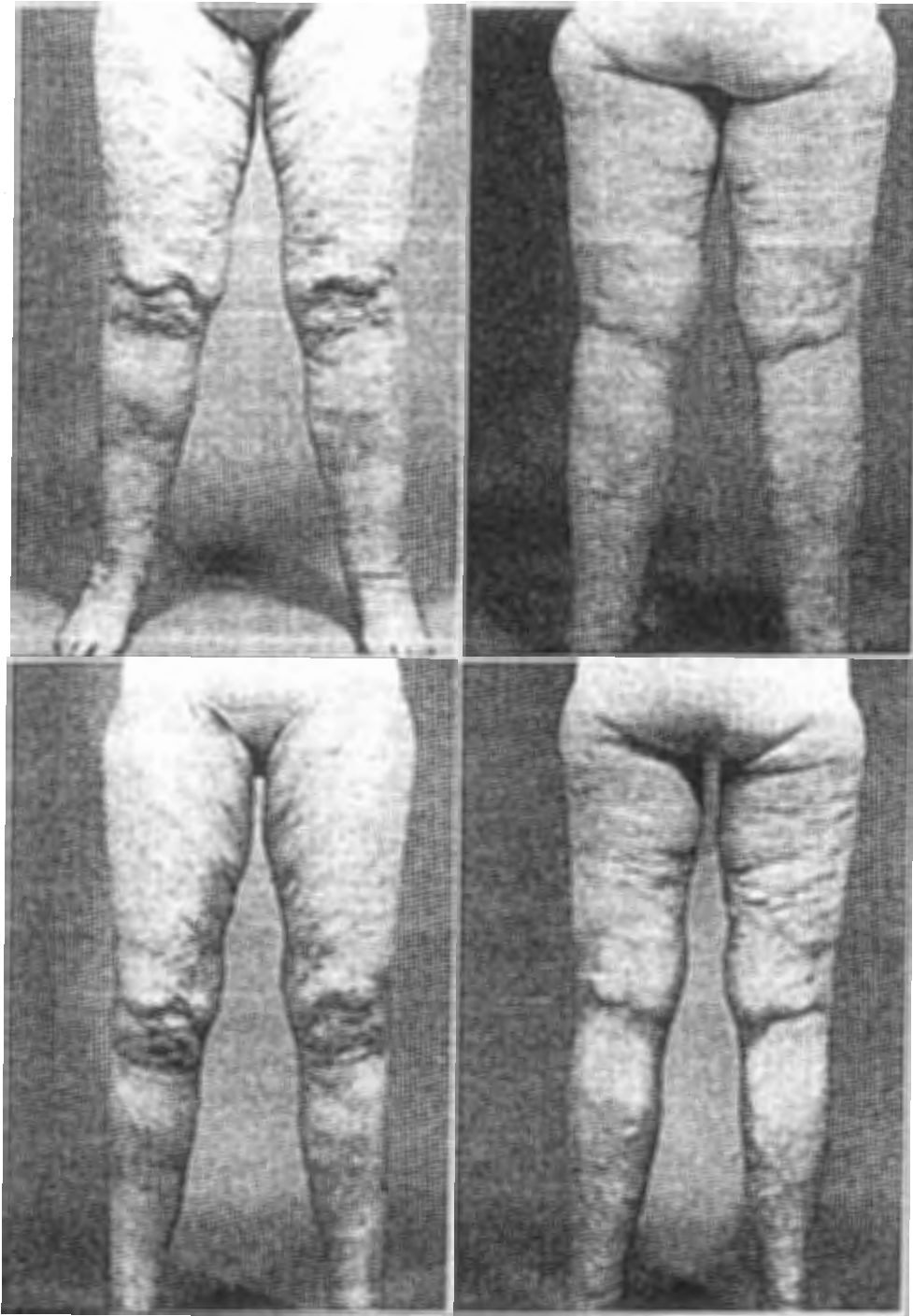


FIG. 4. Preoperative and 18-month postoperative photographs (anterior and posterior views) of a 60-year-old lipedema patient who underwent limited skin and subcutaneous excision with liposuction.

being soft and pliable, unlike that seen in the latter stages of lymphedema. Fifty percent of their patients experienced "diffuse pain, tenderness and aching" in the legs. Elevation and compressive stockings were noted to be of little assistance, with stockings frequently causing considerable discomfort. Unlike lymphedema,

a history of cellulitis was never or rarely obtained, whereas a family history of the condition was frequently obtained.

The constellation of findings described by Allen and Hines is strikingly similar to that of the nine patients described above and most likely represents the same clinical entity. Table

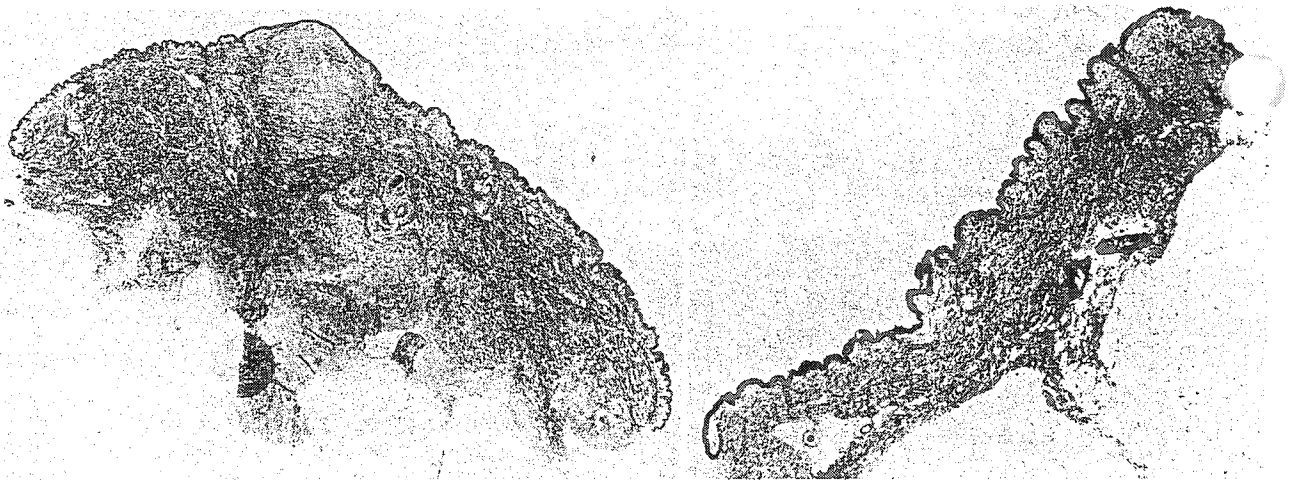


FIG. 5. (Left) High-power view of skin and subcutaneous tissue in a patient with lymphedema. There is increased fibrous tissue in perivascular and dermal areas. (Right) High-power view of skin and subcutaneous tissue in a patient with lipedema. Note absence of skin thickening and absence of fibrosis in subcutaneous fat.

TABLE I  
History and Physical Findings in Lymphedema and  
Lipedema

Signs and Symptoms	Lymphedema	Lipedema
Sex	Male or female	Female
Generalized obesity	±	±
Unilateral/bilateral	Usually unilateral	Bilateral
Nature of swelling	Firm	Soft
Pitting	Often marked	Minimal
Pain on pressure	Rare	Common
Foot involvement	Yes	No
Effect of elevation	Effective initially	Ineffective
Family history	Rare	Often
History of cellulitis	Occasional	Rare
Surgical options	Excisional	Limited excision with suction lipectomy

It points out the clinical findings in lymphedema versus lipedema. It should be noted that the majority of Allen and Hine's patients were noted to be overweight. In the series of patients reported herein, however, only one patient could be considered obese. The remainder had relatively thin upper bodies, although there was an abnormal distribution of fat localized to the lower extremities. This distribution has been noted in other reports of this lipodystrophy.<sup>6,7</sup>

Based on the history and physical and operative findings, this condition is quite different from lymphedema, either congenital or acquired. Certainly, the most striking clinical findings in our patients are the prominent malleolar fat pads and the absence of any swelling distal to the ankle. The character of the subcutaneous tissue in this condition is dramatically different from that seen in patients with lymphedema. The absence of dermal and

perivascular fibrosis seen so consistently in patients with lymphedema is also noteworthy.

The postoperative edema of the foot and ankle that developed in one patient following skin and subcutaneous excision was quite mild but has persisted for 6 years. The burning sensation in the plantar aspect of her heel and midtarsal area was present preoperatively but was significantly aggravated by surgery. The cause of this pain preoperatively and its exacerbation by surgery remain unexplained despite neurologic evaluations and can only be theoretical. This patient's preoperative lymphangiogram showed moderately dilated collecting channels in their usual locations along the medial aspect of the leg. It is possible that in the resection of tissue many of these channels were excised, resulting in edema distally. Why does not aggravation of distal swelling occur in patients with classic lymphedema who undergo the same operative procedure? Current (as yet unpublished) work using radioisotopes in patients with lymphedema strongly suggests that most of the lymph circulation takes place in the subdermal plexus, and it seems reasonable to assume that it will not be appreciably altered by skin and subcutaneous excision beneath flaps.

It is noteworthy that suction lipectomy was used effectively in four of these patients in conjunction with limited skin and subcutaneous excision. While liposuction has been utilized in the treatment of lymphedema,<sup>8</sup> in our experience, the use of suction techniques in patients with lymphedema has not been rewar-

ing. Although we have used this technique on 14 patients with lymphedema, it has been only as a supplemental technique and most helpful in the thigh. Generally speaking, despite vigorous and tiring effort, the suction cannula retrieves little fatty tissue in the patient with significant lymphedema—likely because of the subcutaneous fibrosis, which presents a formidable obstacle. In the lipodystrophy patient, however, the soft quality of the fat facilitates its comparatively easy removal by this technique, and suction lipectomy may be used successfully. It is entirely possible that suction lipectomy in conjunction with limited skin and subcutaneous excision may be the procedure of choice in lipodystrophy patients and reduce, theoretically at least, the possibility of chronic postoperative swelling of the foot.

In conclusion, lipedema is a unique clinical entity that is separate and distinct from lymphedema. Its characteristics include symmetrical enlargement of the lower extremities with soft fatty tissue and minimal edema, prominent malleolar fat pads, and sparing of the feet; the skin changes so commonly seen in lymphedema are lacking. Suction lipectomy with limited skin and subcutaneous excision provides significant improvement in contour and size of the extremities and may prevent the postopera-

tive edema of the feet described with more extensive skin and subcutaneous excision alone.

Timothy A. Miller, M.D.  
 UCLA Medical Center  
 200 Medical Plaza, Suite 669  
 Los Angeles, Calif. 90024-6960

#### REFERENCES

1. Miller, T. A. Surgical management of lymphedema of the extremity. *Plast. Reconstr. Surg.* 56: 633, 1975.
2. Miller, T. A. Surgical management of lymphedema of the extremity. *Ann. Plast. Surg.* 1: 84, 1978.
3. Fonkalsrud, E. W. A syndrome of congenital lymphedema of the upper extremity and associated systemic lymphatic malformations. *Surg. Gynecol. Obstet.* 145: 228, 1977.
4. Allen, E. V., and Hines, E. A., Jr. Lipedema of the legs: A syndrome characterized by fat legs and orthostatic edema. *Proc. Staff Meet. Mayo Clin.* 15: 184, 1940.
5. Wold, L. E., Hines, E. A., Jr., and Allen, E. V. Lipedema of the legs: A syndrome characterized by fat legs and edema. *Ann. Intern. Med.* 34: 1253, 1951.
6. Stallworth, J. M., Hennigar, G. R., Jonsson, H. T., Jr., and Rodriguez, O. The chronically swollen painful extremity: A detailed study for possible etiological factors. *J.A.M.A.* 228: 1656, 1974.
7. Beninson, J., and Edelglass, J. W. Lipedema: The non-lymphatic masquerader. *Angiology* 35: 506, 1984.
8. O'Brien, B. McC., Khazanchi, R. K., Kumar, P. A. V., Dvir, E., and Pederson, W. C. Liposuction in the treatment of lymphedema: A preliminary report. *Br. J. Plast. Surg.* 42: 530, 1989.

---

# Discussion

---

## Lipedema: A Clinical Entity Distinct from Lymphedema

by George H. Rudkin, M.D., and Timothy A. Miller, M.D.

*Discussion by G. Lin Puckett, M.D.*

Drs. Rudkin and Miller are to be commended for introducing a concept of which most of us were previously quite probably unaware. Among Dr. Miller's large series of personally managed lymphedema patients, the authors identified nine in whom typical characteristics of lymphedema were aberrant. It appears that these individuals represented a fairly distinct form of lipodystrophy that could masquerade as lower extremity lymphedema. If I have interpreted their clinical description accurately, the majority of these patients had mild pretibial edema of some degree that probably confused what otherwise might have been an easier diagnosis of lipodystrophy. The patients whom they describe have the swelling confined to the ankle area and above and specifically have no involvement of the feet. Lymphedema of the lower extremity characteristically involves the foot and, indeed, routinely involves the digits of the involved extremity. This has been one of the significant diagnostic distinctions made between lymphedema and edema of venous origin.<sup>1</sup> In essence, we have patients with a specific presentation of lower extremity lipodystrophy masquerading as lower extremity lymphedema. The authors have provided a very helpful table differentiating points between the two entities that should be of value in making the distinction in our own patients. In actuality, I suspect that many of us who have had significant involvement in the treatment of patients with lymphedema may have encountered a patient of this nature and perhaps even misdiagnosed it and mistreated it. However, in this circumstance, since surgical treatment should routinely result in improvement while conservative

measures (traditional for lymphedema patients) such as elastic support and elevation would not, I suspect that no real harm has been done.

As I have become increasingly conservative in my management of lymphedema patients in recent years, it has been my impression that the vast majority can be controlled with a carefully applied conservative regimen. Only specifically recalcitrant cases and particularly those with functional disadvantage have been candidates for surgical treatment. A quicker and more accurate diagnosis of the occasional lipedema patient should direct us more expeditiously to a surgical solution.

The application of suction lipectomy to this entity is a logical evolution of the times. Since, conceptually, the operation's goal is primarily aesthetic enhancement, it is certainly appealing to accomplish this with minimal scarring and the contouring capability afforded with today's liposuction techniques. In reviewing my lymphedema cases, I have not discovered any that fit this precise diagnosis of lipedema. However, I did find a case of lower extremity lipodystrophy that I believe fits (Fig. 1). Although this patient was never diagnosed as having lymphedema, she did have an inordinate disproportion of lower extremity and, specifically, lower leg fatty deposition with the characteristics described by Rudkin and Miller. Indeed, I was able to note a complaint of mild pretibial edema mentioned intermittently by the patient. Liposuction was quite effective in satisfying her aesthetic goals. In retrospect, I believe it is appropriate to assign this patient to the diagnosis offered by this article.



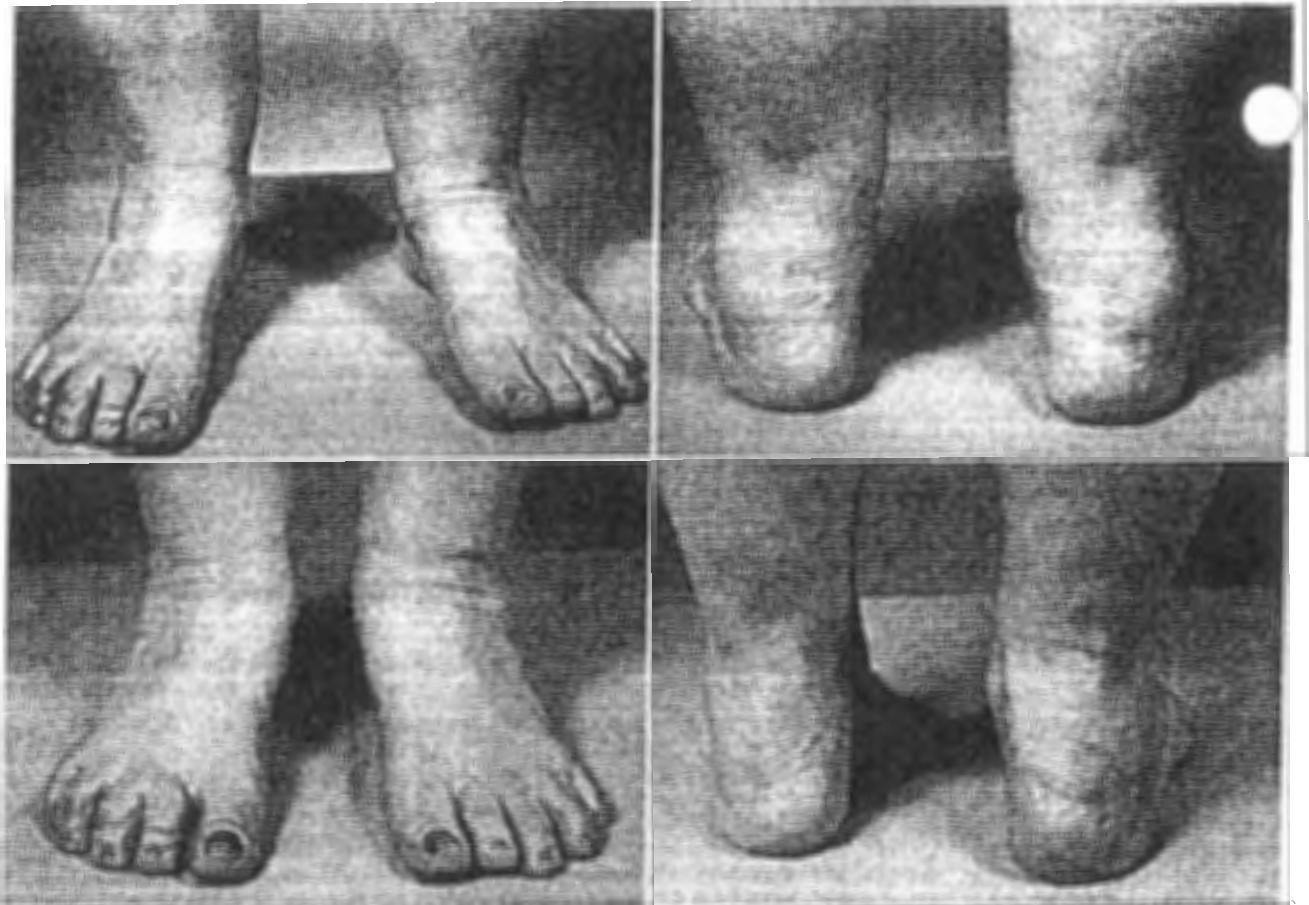


FIG. 1. (Above) Although a mild case, this patient demonstrates lateral malleolar fat accumulation and fat between the Achilles tendon and the medial malleolus. She related a history of mild and intermittent pretibial and ankle edema. (Below) Liposuction was her only treatment.

In summary, Drs. Rudkin and Miller have provided us with an apt description of an entity previously undescribed in our literature. Familiarity with this concept is certainly valuable to any of us involved in the evaluation and treatment of either lipodystrophy patients or lymphedema patients. This diagnosis of lipedema (which we must remind ourselves is a variant of lipodystrophy), as noted by the authors, is an entity distinct from lymphedema and should be adequately differentiated on the basis of physical examination prior to the consideration of therapeutic options.

*C. Lin Puckett, M.D.*

*University of Missouri Health Sciences Center  
Division of Plastic and Reconstructive Surgery  
One Hospital Drive  
Columbia, Mo. 65212*

#### REFERENCE

1. Puckett, C. L., and Silver, D. Principles and Management of Leg Ulcers. In G. S. Georgiade, N. G. Georgiade, R. Riefkohl, and W. J. Barwick (Eds.), *Textbook of Plastic, Maxillofacial and Reconstructive Surgery*, 2d Ed, Vol. II. Baltimore: Williams & Wilkins, 1992.