

Original Article

A new classification system for primary lymphatic dysplasias based on phenotype

Connell F, Brice G, Jeffery S, Keeley V, Mortimer P, Mansour S. A new classification system for primary lymphatic dysplasias based on phenotype. Clin Genet 2010; 77: 438–452. © John Wiley & Sons A/S, 2010

Traditional classification systems for lymphoedema are of limited use for the diagnosis of specific forms of primary lymphoedema. The understanding of primary lymphoedema has been impeded by confusing terminology and a tendency to simply divide patients into three categories based on the age of onset: lymphoedema congenita manifests at or shortly after birth, lymphoedema praecox is apparent before the age of 35 years and lymphoedema tarda manifests thereafter. The clinical presentation in the spectrum of primary lymphoedema disorders is very variable; the phenotypes of primary lymphoedema conditions vary in the age of onset, site of the oedema, inheritance patterns, associated features and genetic causes. Different inheritance patterns are recognised and there are numerous associated anomalies. Some subgroups, such as Milroy disease and Lymphoedema distichiasis, are well characterised, but others are not. A new clinical classification for primary lymphoedema has been developed as a diagnostic algorithm. Its use is demonstrated on 333 probands referred to our lymphoedema clinic. Grouping patients by accurate phenotyping facilitates molecular investigations, understanding of inheritance patterns, and the natural history of different types of primary lymphoedema. Descriptions of the diagnostic categories, some of which have not been previously clearly defined as distinct clinical entities, are illustrated by clinical cases.

**F Connell^a, G Brice^b, S Jeffery^a,
V Keeley^c, P Mortimer^d
and S Mansour^b**

^aMedical Genetics Unit, Clinical Developmental Sciences, and ^bSouth West Thames Regional Genetics Unit, St George's University of London, Cranmer Terrace, London SW17 0RE, UK, ^cDerby Hospitals NHS Foundation Trust, Nightingale Macmillan Unit, 117A London Road, Derby DE1 2QS, UK and ^dCardiac and Vascular Sciences (Dermatology), St George's University of London, Cranmer Terrace, London SW17 0RE, UK

Key words: *CCBE1* – *FOXC2* – generalised – lymphangiectasia – lymphatic dysplasia – lymphoedema distichiasis – Milroy disease – phenotype classification – primary lymphoedema – *VEGFR3*

Corresponding author: Sahar Mansour, South West Thames Regional Genetics Unit, St George's University of London, Cranmer Terrace, London SW17 0RE, UK. Tel.: +44 2087250957; fax: +44 2087253444; e-mail: smansour@sgul.ac.uk

Received 18 December 2009, revised and accepted for publication 1 February 2010

A new clinical classification system for primary lymphoedema is introduced as a diagnostic algorithm. Its use in the clinical setting is demonstrated on 333 patients. Primary lymphoedema is a chronic oedema caused by a developmental abnormality of the lymphatic system (1). Secondary lymphoedema has recognised acquired causes; for example, radiation, surgery, neoplasm, or infection. Primary lymphoedema is rare, affecting approximately 1.15/100,000 of the population less than 20 years of age (2). The clinical presentation in this spectrum of disorders is very variable. Different inheritance patterns are recognised

and there are numerous associated anomalies. The pathogenesis of this rare group of conditions is not fully understood, but research in this field has gained momentum in recent years with the identification of lymphatic endothelial specific markers and regulators, and the development of mouse models. Jeltsch et al., Oliver and Alitalo, Tammela et al., and Mäkinen et al. provide valuable reviews on lymphangiogenesis (3–6). Mutations in the genes *VEGFR3*, *FOXC2*, and *SOX18* are known to cause Milroy disease, Lymphoedema distichiasis, and hypotrichosis-telangiectasia-lymphoedema syndrome, respectively (7–9). Ferrell et al. carried

out sequencing of a series of biologically plausible candidate genes (including *PROX1*, *EMILLINI*, *LCP2*, *LYVE1*, *NRP2*, *PDPN*, *SYK*, and *VEGFC*) in primary lymphoedema families. They excluded 21 candidate genes as common causes of primary lymphoedema and found mutations in four genes (*FABP4*, *NRP2*, *SOX17*, and *VCAM1*) (10). There are limitations to their findings in these genes as the families are too small to convincingly conclude co-segregation of mutation and phenotype. The results warrant further follow-up of these genes. In one study, hepatocyte growth factor (*HGF*) and its high affinity *HGF* receptor (*MET*) were directly sequenced in primary lymphoedema probands, women with secondary lymphoedema, patients with lymphoedema and intestinal lymphangiectasia, and unrelated, ethnically matched controls (11). Mutations leading to missense or truncation changes were found in individuals from each of these groups except the control group, suggesting a causal/susceptibility relationship between these two genes and/or the *HGF/MET* pathway and a broad range of lymphoedema phenotypes (11). Further work is required to fully establish the role of *HGF* and *MET* in primary and secondary lymphoedema as there have been no subsequent confirmatory reports supporting their pathogenicity. Most recently, mutations in *CCBE* have been identified to cause generalised lymphatic dysplasia in a cohort of patients (12, 13). The genetic causes of other primary lymphoedema conditions remain unidentified.

Understanding of primary lymphoedema has been impeded by confusing terminology and a tendency to simply divide patients into three categories based on the age of onset: lymphoedema congenita manifests at or shortly after birth, lymphoedema praecox is apparent before the age of 35, and lymphoedema tarda manifests thereafter (2, 14–16). Clinical experience has shown us that this classification system is over-simplified and redundant in clinical practice as it does not facilitate categorisation based on more specific phenotypes.

There are other classifications for lymphatic anomalies. Browse et al. presented a method based on pathophysiology which highlighted the importance of using a system based on known abnormalities without implying, as yet unproven, causative mechanisms (17). This is a principle to which our pathway also adheres but in the clinical setting, we find a phenotype-based classification to be more practical. It would be very useful to classify lymphoedema based on the underlying nature of the lymphatic defect, but this is prohibited by the fact that investigation and imaging of the lymphatics is limited. Hilliard et al.

described two classifications: a pathological delineation and a clinical one (18). In the first case of these, lymphoedema is one classification and not further differentiated, and in the latter, the congenital abnormalities of the lymphatic system are described according to the anatomical location of the oedema and associated features (18). The groups in this classification are: (i) masses, (ii) bone lesions, (iii) presentations due to a single abnormal function of the lymphatics, (iv) presentation due to combination of abnormal functions of lymphatics, (v) associated abnormalities, and (vi) symptoms related to mixed angiomas (18). In practice, this clinical classification would group together all the following diagnoses as having 'presentation due to a single abnormal function of the lymphatics' (i.e. lymphoedema): Milroy disease, Meige disease, Lymphoedema distichiasis, congenital unisegmental, and congenital multi-segmental lymphoedema. These conditions have different clinical presentations, different implications for offspring risk, different genetic causes, and different management issues. Therefore, a diagnostic pathway that helps to differentiate between such diagnoses is of more benefit in the clinical setting. Miller et al. produced a lymphoedema classification based on clinical observation, using concepts of inspection, palpation, changes with elevation of limb, and function/mobility of joints/limbs (19). The aim of devising this system was to collect epidemiological data on lymphoedema in an attempt to understand how best to prevent and treat the disease. This system divides lymphoedema into four grades of severity based on the concepts given above but does not consider anatomical location of lymphoedema, systemic involvement, family history (FH), or associated features, all of which we feel are essential in distinguishing between different phenotypes. Shinawi presents an 'updated flowchart for the classification of unilateral limb lymphoedema' (20). This flowchart is neither updated nor widely useful. It uses the historical classification of lymphoedema congenita, lymphoedema praecox, and lymphoedema tarda for idiopathic primary lymphoedema, and the hereditary primary lymphoedemas are divided into syndromic and non-syndromic. Shinawi's flowchart is only for the unilateral limb lymphoedema and this limits the number of primary lymphoedema patients for which it is of use (20).

We have therefore developed an innovative classification pathway with the aim of improving phenotyping in primary lymphoedema. The pathway serves as a guide for clinicians on how to approach a patient who presents with primary lymphoedema

in terms of working towards a diagnosis, appropriate management, and discussion regarding recurrence risks (risk of subsequent offspring/siblings being affected by the same condition as the proband), inheritance patterns and prognosis. The benefit of this is to help the management of what can be a disabling, disfiguring, and even life-threatening condition, to gain understanding about the progression and prognosis of different types of lymphoedema, and lead us towards identifying the underlying genetic causes of primary lymphoedema.

Method

A pathway has been developed based on clinical phenotype, FH, and age at manifestation of symptoms. Having finalised the pathway, it was used to classify 333 probands with primary lymphoedema, referred to the lymphoedema service at St George's Hospital, London, during period of 2001–2008. Only 21 probands were not examined in our clinic and were therefore classified according to the clinical details provided by the referring clinician. Thirteen out of these 21 probands had their diagnosis confirmed on molecular, cytogenetic, or haematological investigations. The classification is presented in the form of an algorithm. The pathway is colour coded as a way to illustrate the five main categories of primary lymphoedema. Within the five main categories there are individual classifications/diagnoses (Fig. 1).

Use of the pathway requires appreciation of the terminology:

- (1) **Syndromic** refers to a constellation of various abnormalities, one of which is lymphoedema. Any patient with dysmorphic features was considered 'syndromic' (except those with facies purely consistent with *in-utero* oedema. See Fig. 2). The syndrome may be a known syndrome, or if the features did not fit a recognised pattern, the classification of 'unknown syndrome' was assigned. Opitz described the 'congenital lymphoedema face' (facies consistent with *in-utero* oedema) that included the following features: epicanthic folds, broad nasal bridge, redundant neck skin/neck webbing, low set ears, down-slanting palpebral fissures, and retrognathia (Figs 2, 8a, and 9a) (21).
- (2) **Prenatal onset** refers to detection of a lymphatic abnormality (excluding isolated pedal oedema) in the prenatal period. Prenatal onset isolated pedal oedema has been reported in Milroy disease and therefore was excluded

from prenatal onset of lymphoedema leading to generalised lymphatic dysplasia. An isolated raised nuchal translucency did not constitute prenatal onset of lymphoedema. Pleural and pericardial effusions, ascites, and hydrops were all considered as prenatal onset of a more generalised congenital lymphatic abnormality.

- (3) **Systemic/visceral involvement** refers to ongoing problems of a systemic/visceral lymphatic nature beyond the newborn period or manifesting at any age thereafter. It includes chylous reflux, ascites, intestinal lymphangiectasia, pleural and pericardial effusions, and pulmonary lymphangiectasia.
- (4) **Disturbed growth** of bone or soft tissue results in altered length of a body part (includes hypertrophy/overgrowth and hypotrophy).
- (5) **Vascular anomalies** include congenital vascular malformations (capillary malformations, venous malformations, lymphatic malformations, and arterio-venous malformations) and vascular tumours (haemangiomas and lymphangiomas). The combined vascular malformation group includes patients with localised lymphatic malformation with a blood vessel component (formerly referred to as haemangio lymphangiomas) (22–25).
- (6) **Cutaneous manifestations** refer to naevi/pigmentation variations (e.g. epidermal naevi).
- (7) **KT/KT-like** is an abbreviation for Klippel–Trenaunay/Klippel–Trenaunay-like syndrome. KT-like patients have features of KT syndrome but do not fulfil the diagnostic criteria (26).
- (8) **Proteus-like** patients have features of Proteus syndrome but do not fulfil the diagnostic criteria (27).
- (9) **Distichiasis** is the presence of aberrant eyelashes arising from the meibomian glands (not simply a second row of eyelashes). Pathognomonic of Lymphoedema distichiasis syndrome in the presence of lymphoedema (Fig. 3).
- (10) **Congenital onset** (for purposes of our pathway) is defined as lymphoedema that is present before the age of one year. This definition was established on review of the age of onset of lymphoedema in the mutation confirmed cases of Milroy disease. In this known congenital lymphoedema condition, most present with lymphoedema at birth, but in some, the onset is delayed into the infantile period (28).
- (11) **Late onset** means that lymphoedema was only apparent after one year of age.

Primary lymphatic dysplasias based on phenotype

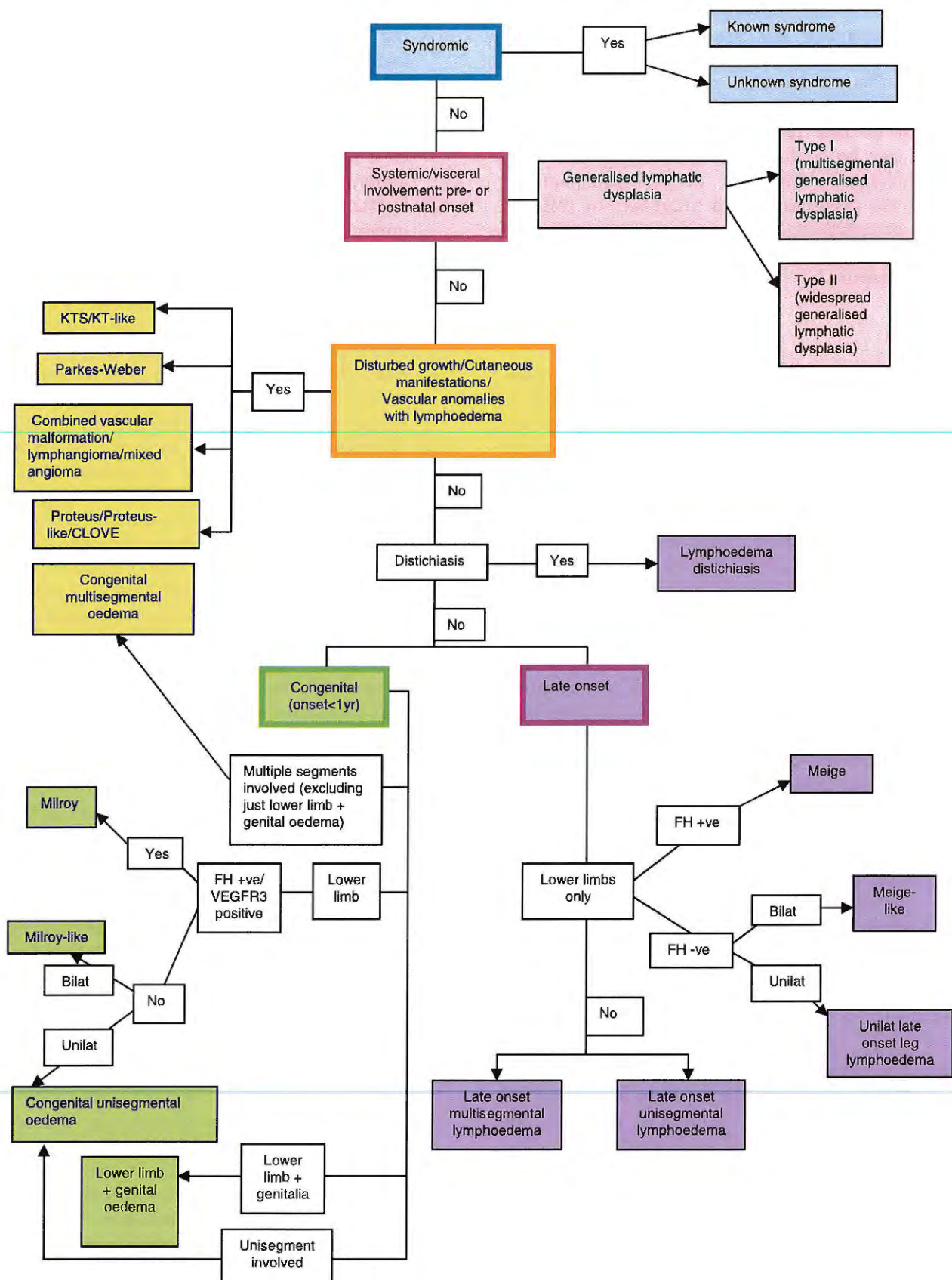


Fig. 1. Classification pathway for primary lymphoedema. FH, family history; +ve, positive; -ve, negative; bilat, bilateral; unilat, unilateral.

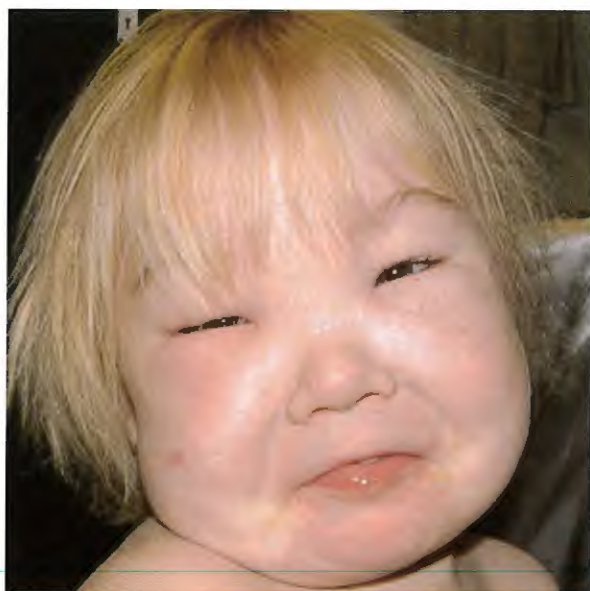


Fig. 2. *In-utero* oedema facies: epicanthic folds, broad nasal bridge. Residual facial oedema.

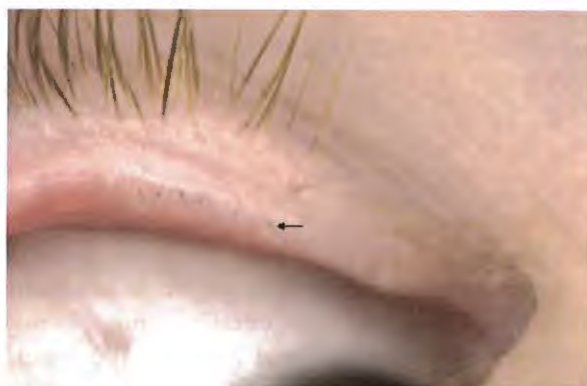

Fig. 3. Distichiasis.

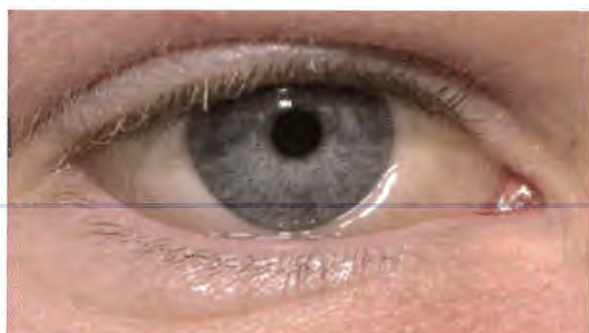

Fig. 4. Conjunctival oedema.

- (12) **Segment** refers to a body part affected by lymphoedema [i.e. face, genitalia, conjunctiva (Fig. 4), upper limbs, lower limbs – each

of which constitute one body part]. Multi-segment refers to more than one segment affected by lymphoedema (e.g. face and arms, or face, arm, and genitalia, or arm and leg). Bilateral leg swelling is not considered to be multi-segmental lymphoedema.

- (13) **FH** of primary lymphoedema was perceived as positive if there was a verifiable history of an affected family member that could be linked to the proband by means of a recognised inheritance pattern.

Results

Three hundred and thirty-three patients with primary lymphoedema were assigned a classification using the pathway. Figure 5 shows the numbers of patients identified in each category, and although this does not reflect accurate prevalence figures of different types of primary lymphoedema, it does demonstrate the extent of the clinical experience from which the classification system originates.

Syndromic primary lymphoedema

In the pathway syndromic refers to a constellation of features one of which is lymphoedema. Dysmorphic patients were considered to be 'syndromic' (except patients whose dysmorphic features could be attributed to *in-utero* oedema – see description above). The patients in the syndromic cohort were divided into two groups; *known syndrome* if their combination of features was consistent with a diagnosis of a named syndrome, and *unknown syndrome* if it was not possible to label them with a specific, recognised syndrome.

Lymphoedema is not a search criterion option on the London Dysmorphology Database but oedema of hands/feet is a recognised feature of 67 syndromes and if hydrops is included then 175 syndromes are listed (29). In this study, out of 333 patients, 33 were assigned a known syndromic diagnosis (excluding those patients assigned diagnoses that exist in other categories of the pathway) (Table 1). Genetic counselling regarding prognosis and recurrence risks should be specific for each syndrome.

Turner, Noonan, Prader Willi, and CHARGE are all syndromes well known to geneticists, in which lymphoedema can be a feature. Primary lymphoedema is also seen in several less frequent syndromes including Aagaenae's, Microcephaly-chorioretinopathy-lymphoedema, Mucke, Hennekam, Irons-Bianchi, Hypotrichosis-telangiectasia-lymphoedema, OL-EDA-ID (osteopetrosis,

Primary lymphatic dysplasias based on phenotype

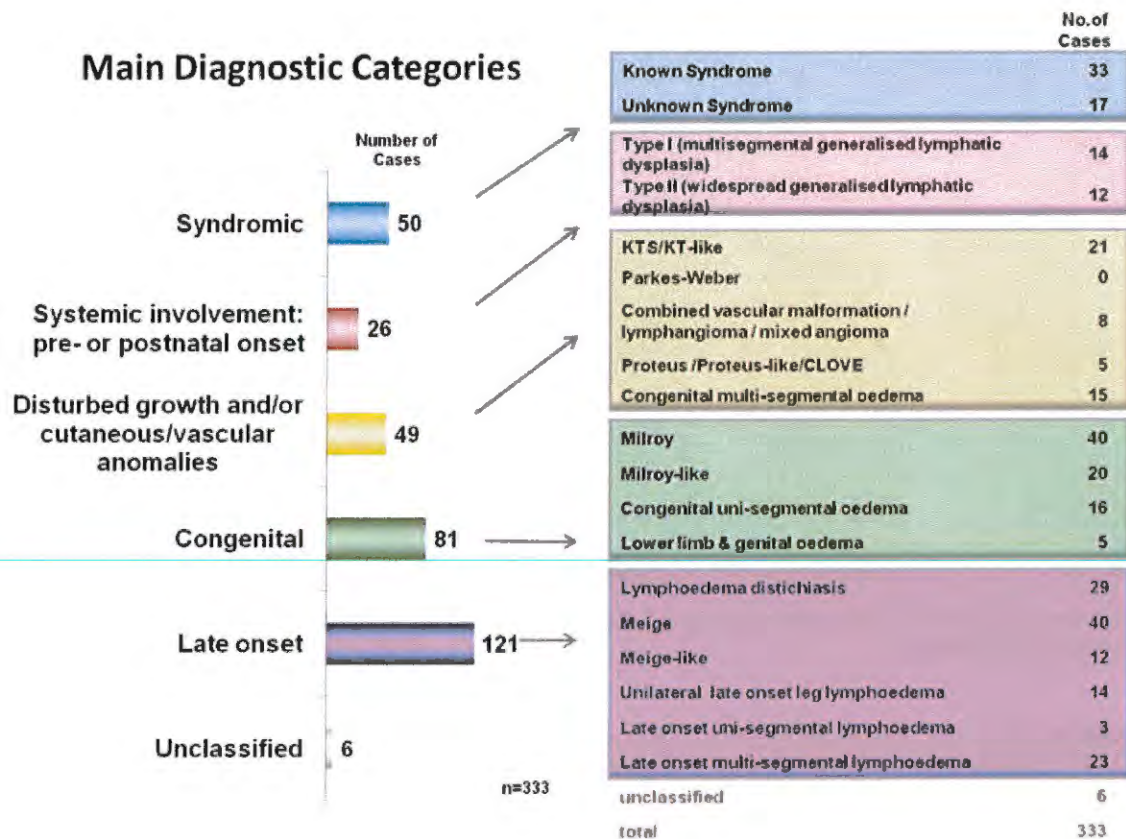


Fig. 5. Number of cases in each diagnostic category ($n = 333$).

Table 1. Numbers of patients with lymphoedema as part of a known syndromic diagnosis

Known syndrome	Number of cases
Agenaes syndrome	1
Cardio-facio-cutaneous syndrome	1
CHARGE association	1
Chromosomal abnormality	7
Ectodermal dysplasia, anhidrotic, immunodeficiency, osteopetrosis and lymphoedema	1
Lymphoedema-myelodysplasia	7
Lymphoedema-microcephaly-chorioretinopathy dysplasia	6
Megalencephaly-cutis marmorata-telangiectasia-congenita	1
Noonan syndrome	2
Thrombocytopenia with absent radius	1
Turners syndrome	2
Yellow nail syndrome	1

lymphoedema with anhidrotic ectodermal dysplasia and immunodeficiency) and WILD (disseminated warts, depressed cell-mediated immunity, primary lymphedema, and anogenital dysplasia) syndromes (30–37). On seeing a patient with primary lymphoedema it is important to obtain a

full history and clinical examination as other clinical signs may point towards a specific syndromic diagnosis. Molecular/cytogenetic testing and management issues should be directed at the specific syndrome being diagnosed. Seven patients in this cohort had identifiable chromosome abnormalities and therefore karyotyping should be carried out in all dysmorphic patients with lymphoedema. Recently, *CCBE1* has been reported to be mutated in a proportion of patients with Hennekam syndrome and analysis of this gene is therefore worth considering in patients with a Hennekam syndrome phenotype (lymphoedema, lymphangiectasia, and mental retardation) (12, 13).

There were 17 patients with dysmorphic features, lymphoedema and other abnormalities, that were labelled as having unknown syndromes. It is only by phenotyping these unusual cases that patterns amongst patients become apparent and syndromes emerge, as is demonstrated by the fact that seven patients have been identified with a phenotype featuring myelodysplasia and lymphoedema (Mansour et al. – submitted) and recognised syndromes can be delineated.

Generalised lymphatic dysplasia

The diagnosis of a generalised lymphatic dysplasia implies a congenital developmental abnormality of the lymphatic system that has resulted in systemic involvement, the onset of which can be pre- or post-natal. Out of 333 patients, 26 were classed as having a generalised lymphatic dysplasia.

Signs of prenatal onset of a lymphatic disorder include pericardial effusions, pleural effusions, ascites, and hydrops. Prenatal hydrops can occur secondary to many different causes and therefore can only be considered as a primary lymphoedema if other causes (e.g. Parvo virus, Rhesus incompatibility) have been excluded. It is a diagnosis that is usually made retrospectively. *VEGFR3* and *FOXC2* mutations have also been reported in hydropic infants suggesting that Milroy disease and lymphoedema distichiasis can present as hydrops (38, 39). This is rare but is worth considering, especially if there is a FH suggestive of these conditions.

Systemic (visceral) involvement includes pericardial and pleural effusions, ascites, chylous effusions, and pulmonary and intestinal lymphangiectasia. Recognising these problems has important management implications. Effusions may require drainage, and medium-chain-triglyceride (MCT) diets are proven to be of benefit in managing intestinal lymphangiectasia and chylous disorders (40). The absence of fat in the diet prevents chyle engorgement of the intestinal lymphatic vessels thereby preventing their rupture with its ensuing lymph loss (41). MCTs are directly absorbed into the portal venous circulation avoiding lacteal overload (41). A history of loose, frequent, offensive, fatty stools is suggestive of intestinal lymphangiectasia and should specifically be asked about, as patients do not always offer this information. Pleural effusions and intestinal lymphangiectasia were the most frequent form of systemic involvement. Patients were seen with different combinations of types of systemic involvement.

In our experience, patients with a generalised lymphatic dysplasia fall into two categories:

- (1) *Type I multi-segmental generalised lymphatic dysplasia*: mosaic pattern of lymphoedema affecting different body parts, in a segmental, asymmetrical pattern, with systemic involvement and a low recurrence risk.
- (2) *Type II widespread generalised lymphatic dysplasia*: widespread, more uniform pattern of lymphoedema. These patients can have facial features consistent with *in-utero* oedema, and/or systemic involvement. Some of these

patients have a positive FH and this has an impact on the recurrence risk.

Out of the total of 26 patients with generalised lymphatic dysplasia, 14 fell into the type I category. These patients had an asymmetrical pattern of oedema of the limbs with/without genitalia or facial lymphoedema. The systemic involvement in these patients was variable. Case reports 1 (Fig. 6) and 2 (Fig. 7) describe two typical patients in this group. They both have a negative FH and recurrence risk is presumed to be low. The prognosis for the lymphoedema is difficult to predict but management of systemic symptoms should be addressed and conservative management of the lymphoedema should be implemented to minimise deterioration.

The type II generalised lymphatic dysplasia group are important to recognise as the recurrence risk is a significant issue. We have 12 patients in this group. Inheritance patterns consistent with autosomal dominant and recessive transmission have been noted in different families. A full FH, including details of lost pregnancies, is essential in order to formulate the pedigrees. Case reports 3 (Fig. 8) and 4 (Fig. 9) are examples of probable autosomal recessive families. The distinguishing feature of the lymphoedema in these cases is the more uniform pattern of oedema rather than the segmental, mosaic pattern seen in type I, and the *in-utero* oedema facies seen in some cases. Again the systemic involvement is variable. *CCBE1* gene analysis is appropriate in this cohort of patients with an autosomal recessive FH as it has been reported to cause recessively inherited generalised lymphatic dysplasia (12, 13). There are some patients in this group where the inheritance pattern is uncertain, but counselling of recurrence risks has to take into account the various possibilities.

Lymphoedema with overgrowth, vascular, or cutaneous manifestations and congenital multi-segmental lymphoedema

This is a diverse group of patients with vascular anomalies, disturbed limb growth and/or cutaneous manifestations, of varying types, plus lymphoedema. This group of patients have a low recurrence risk given the sporadic, mosaic nature of these conditions. Garzon et al. provide a comprehensive review of vascular anomalies and associated syndromes, and tackle the conflicting nomenclature that confuses this topic (24, 25).

Lymphoedema can be seen as a component of Klippel–Trenaunay syndrome (KTS), Parkes–Weber syndrome, Proteus syndrome, and CLOVE

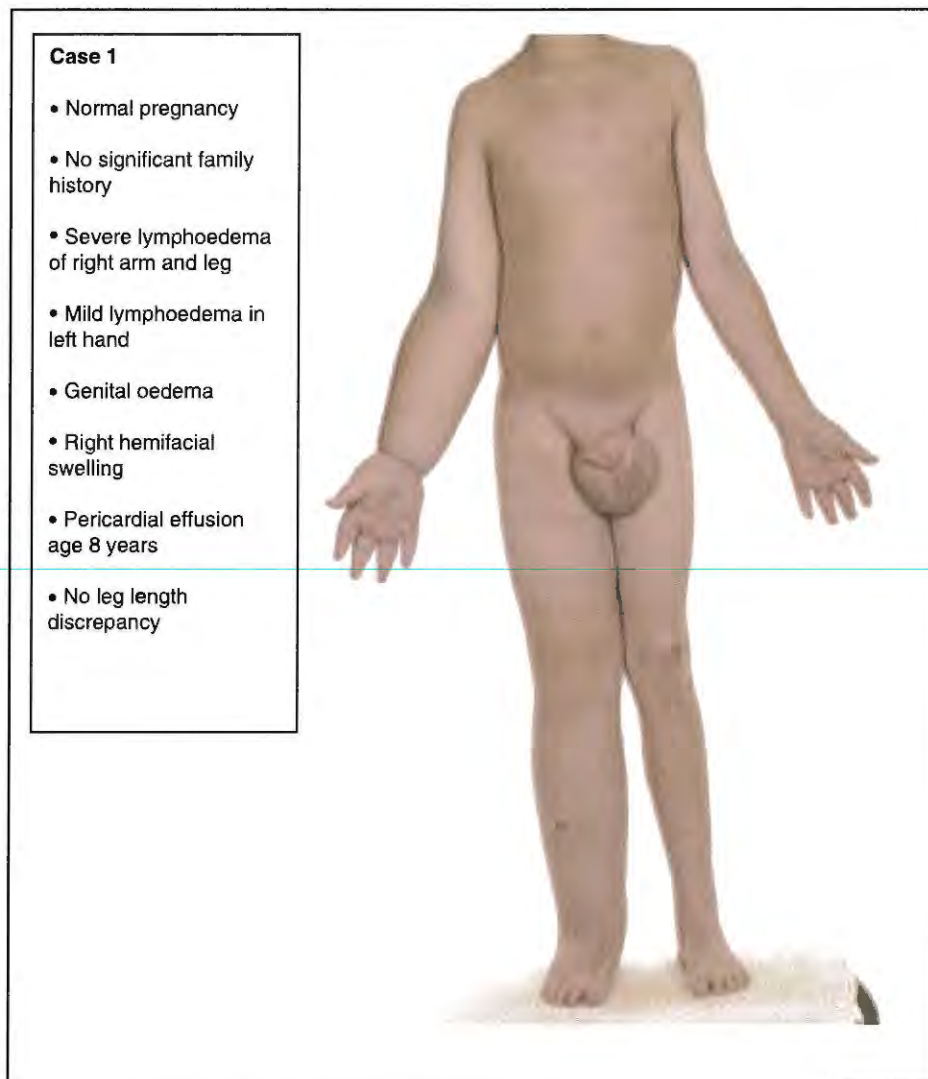


Fig. 6. Case 1; case example of a 9-year-old male with multi-segmental generalised lymphatic dysplasia.

syndrome, and they have all been included in this category of the classification system. These are distinct congenital malformation entities about which there is much literature and debate that attempts to delineate diagnostic criteria. It is not within the remit of this publication to review these diagnostic criteria. The pathway includes the terms 'KTS-like' and 'Proteus-like' as we recognise that there are patients that resemble the phenotype of these conditions but may not fit some of the diagnostic criteria. Oduber et al., review the diagnostic criteria for KTS with their definition of KTS being; vascular malformations (capillary, venous, arterio-venous, or lymphatic) and disturbed growth (of bone or soft tissue) (26).

In this study, we only had five Proteus/Proteus-like patients and no Parkes-Weber patients. There were 21 patients in the KTS/KTS-like group. The

phenotypic features to highlight about this group are that epidermal naevus was a feature in three patients, and five of the 21 KTS/KTS-like cases had lymphoedema involving the genitalia. Epidermal naevus and genitourinary complications are recognised in the KTS literature (42, 43). Our findings support these reports that epidermal naevi and genital lymphoedema can be the features associated with KTS. Three of the patients in this group had hypotrophy of the affected limb whereas the rest had overgrowth. The severity of the vascular malformations in these patients is very variable.

Another diagnostic category in this group is congenital vascular anomalies involving lymphatic vessels (not strictly lymphoedema, although in some cases there is lymphoedema associated with the localised malformation). Congenital combined vascular malformations involve any

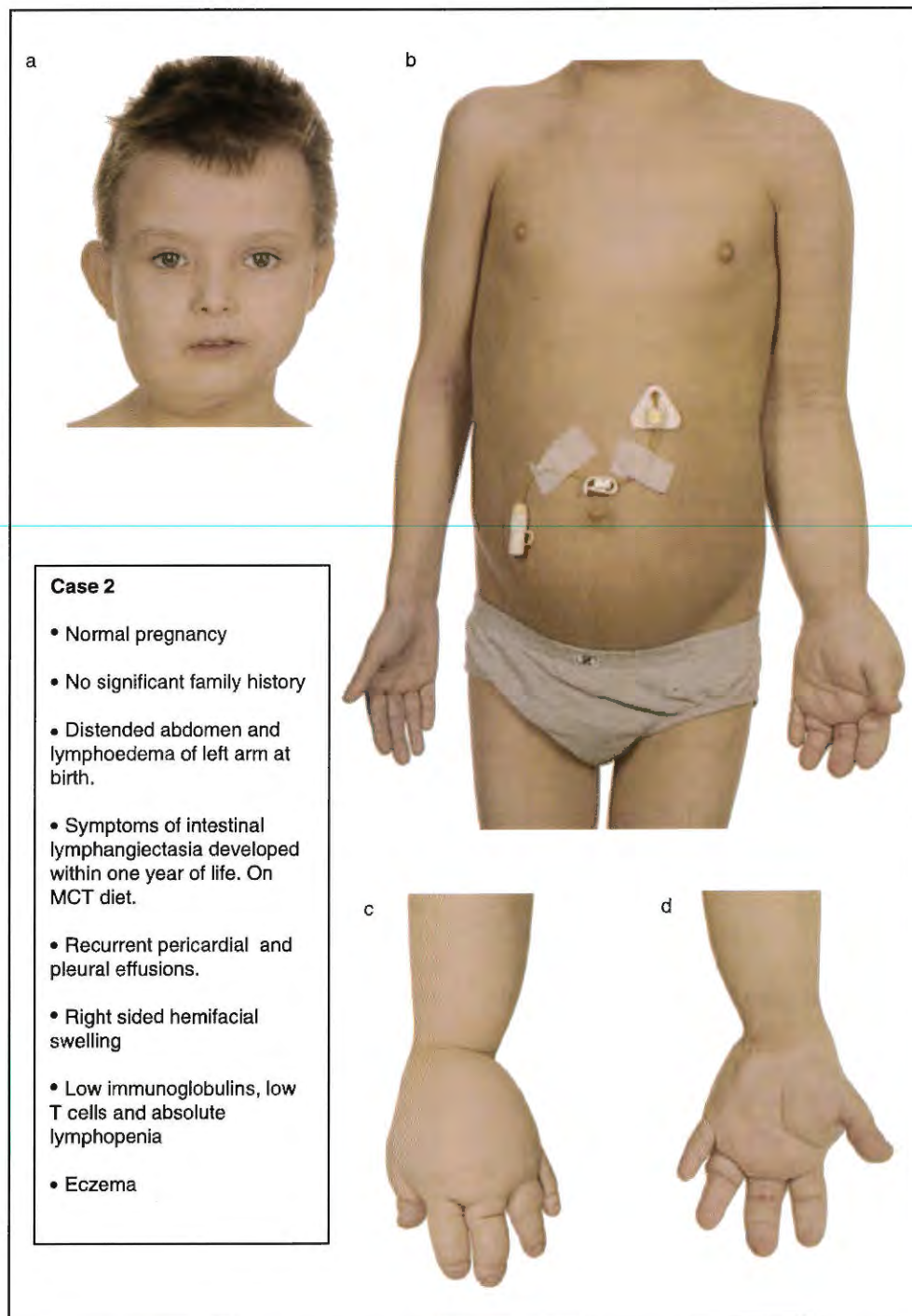


Fig. 7. (a–d) Case 2; case example of a 10-year-old male with multi-segmental generalised lymphatic dysplasia.

combination of capillary, venous, and/or arterial vessels, together with a lymphatic component, and were historically called haemangiolymphangioma. However, Mulliken's classification of vascular anomalies is now recognised as the accepted format (23, 44). We have eight patients with these lesions that are macrocystic in nature, are not associated with disturbed growth (as in KTS)

and grow commensurately with the individual. In our experience, they can show a proliferative phase antenatally, which can lead to intrauterine death (45). Morbidity in survivors can be significant. Figure 10a,b shows images of fetuses with combined vascular malformations.

Congenital multi-segmental lymphoedema (no systemic involvement, disturbed growth, or

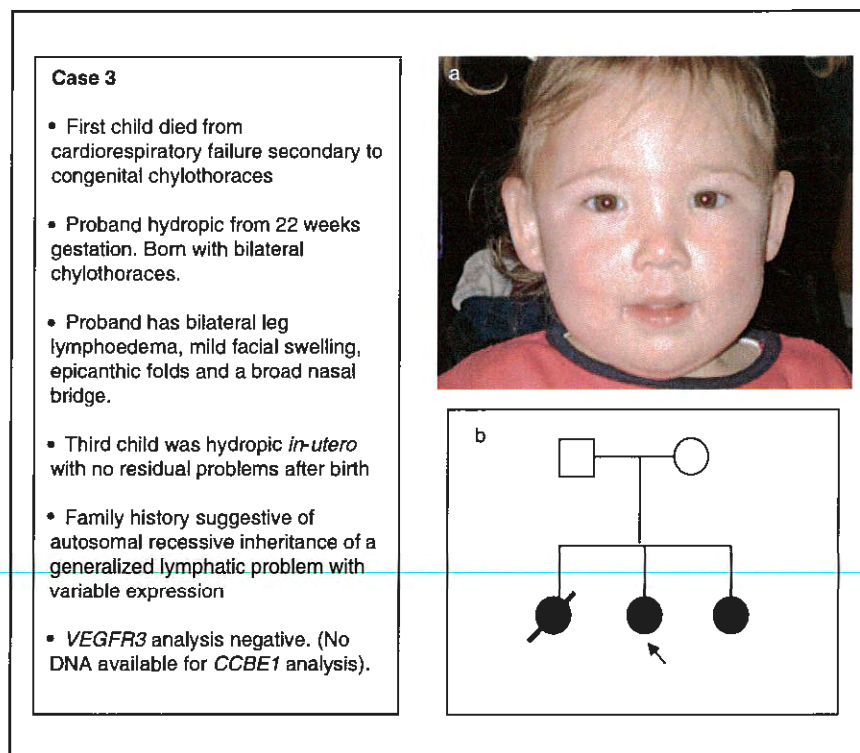


Fig. 8. (a–b) Case 3; 1-year-old female with widespread generalised lymphatic dysplasia.

cutaneous manifestations) also falls into this category of patients because of the asymmetrical, mosaic pattern of the lymphoedema, also seen in KTS and Proteus, and thus confers a low recurrence risk. We have 15 patients in this group with a combination of different body segments affected. There is no specific pattern as to which segments are involved.

Congenital onset lymphoedema

In this study, the main criterion of the diagnoses in this group is the presentation of lymphoedema before one year of age.

This group includes Milroy disease. Milroy disease is an autosomal dominant congenital disorder of the peripheral lymphatics and was first described by Milroy in 1892 (46). Mutations in *VEGFR3* are known to cause Milroy disease and in our experience can be detected in 68% of patients with a phenotype that is typical of Milroy disease and 75% if they have a positive FH (28). Non-penetrance has been reported (up to 15%) (7, 44).

The pathway divides the Milroy phenotype into two categories: Milroy disease and Milroy-like disease. Typically, Milroy disease consists of lymphoedema evident at birth, which is usually, but not necessarily, bilateral lower limb lymphoedema. It characteristically has a brawny texture. Deep

creases are seen on the toes and often large calibre greater saphenous veins are seen. Figure 11 shows the feet of a neonate with Milroy disease: the dorsal foot swelling, the small, dysplastic, and upslanting toe nails are characteristic signs. Hydrocoeles are a recognised associated feature (47). An autosomal dominant FH may be given but is not essential for the diagnosis (48, 49). Lymphoscintigraphy in Milroy disease demonstrates non-functioning initial lymphatic absorption. Lymphatics are seen histologically in skin biopsies. Therefore there is not aplasia of these initial lymphatics, as previously thought (R Mellor – personal communication).

Patients in whom the lymphoedema resembles the Milroy phenotype but FH is negative and *VEGFR3* mutation screening is negative have been labelled as Milroy-like. There are 20 patients in this group for whom the long-term prognosis is undetermined and the inheritance pattern is unclear.

Congenital unisegmental lymphoedema affects 16 of our 333 patients. Eleven cases had one leg involvement (of the eight tested, none had *VEGFR3* mutations) and five had one arm affected (Fig. 12a,b). No patients in this group had a positive FH, suggesting a low recurrence risk. Genital, facial, and conjunctival lymphoedema have not been seen in isolation in this cohort of patients.

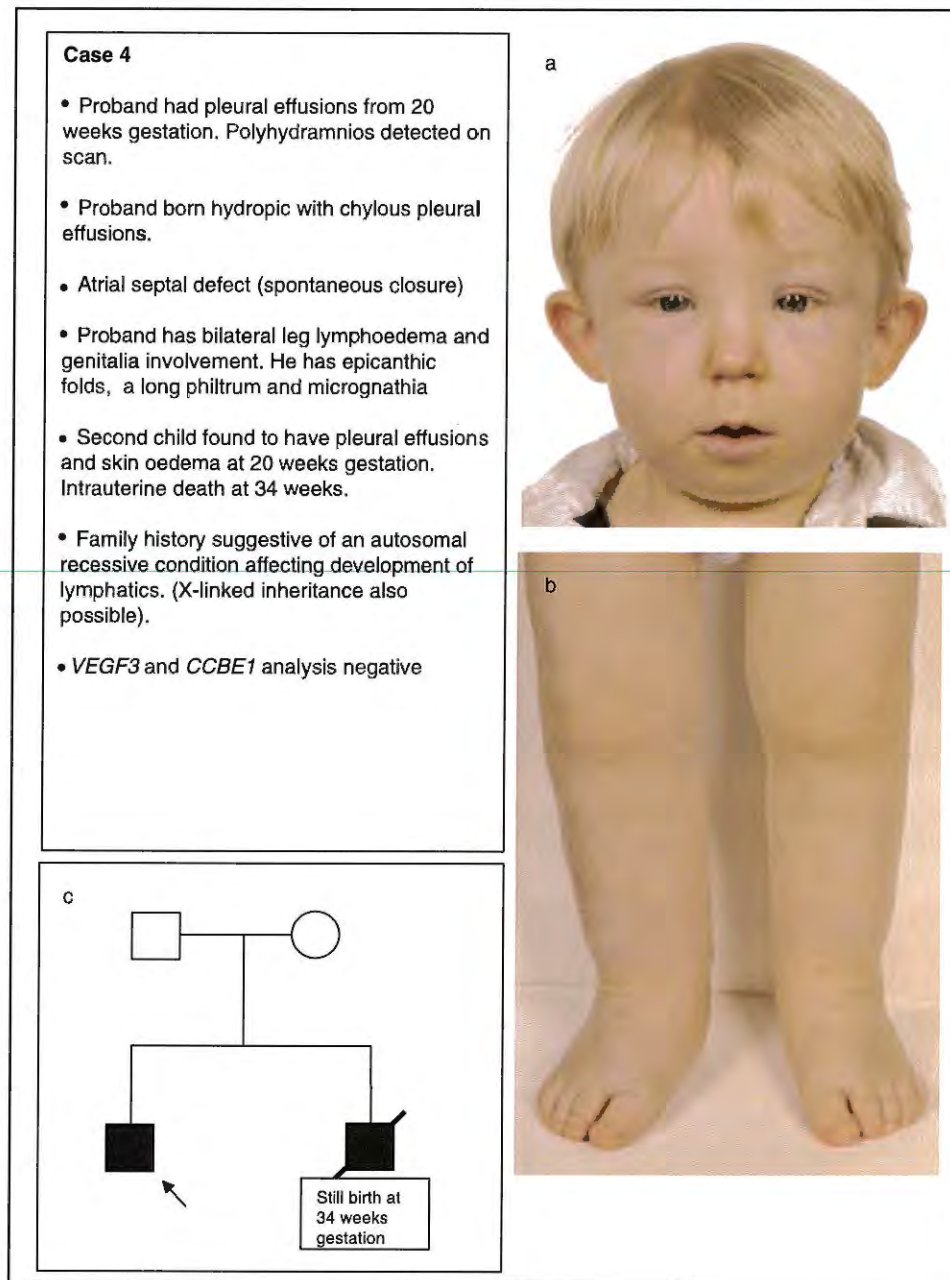


Fig. 9. (a–c) Case 4; 2-year-old male with widespread generalised lymphatic dysplasia.

The last classification in this section is lower limb and genital oedema. There are five patients who fall into this category as genital oedema appears to be more commonly associated with more widespread lymphatic problems or KTS, and on direct questioning many of the patients with limb and genital lymphoedema also had systemic involvement, particularly intestinal lymphangectasia with persistent diarrhoea. Lower limb lymphoedema with genital oedema is also the pattern of lymphoedema recognised in the Lymphoedema-myelodysplasia cohort and given the serious nature

of this disorder, we highlight the need to be aware of the other potential problems in patients presenting with this pattern of lymphoedema (S Mansour – submitted).

Late onset lymphoedema

The onset of lymphoedema in this cohort of patients is over the age of one year. In primary lymphoedema, other than congenital onset lymphoedema, age of onset and thus presentation in the clinic, is often in the pubertal/teenage years.

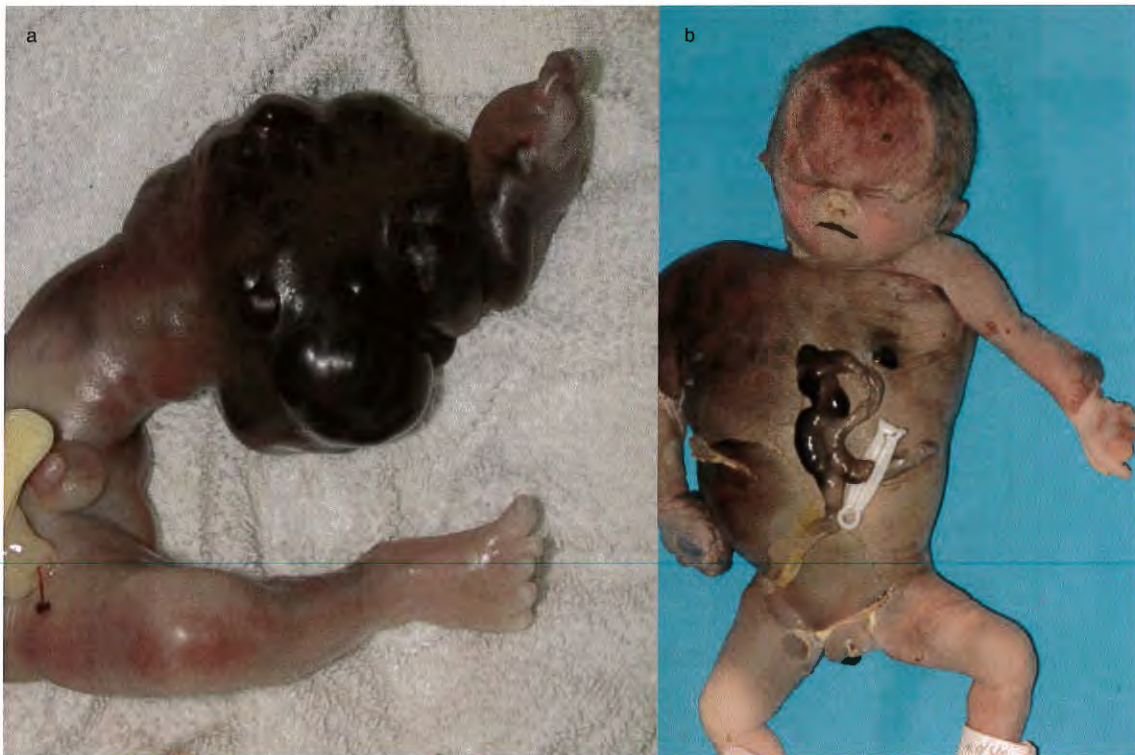

Fig. 10. (a) Macrocytic combined vascular malformation of left lower limb of foetus (postmortem). (b) Macrocytic combined vascular malformation of the thorax of foetus (postmortem).

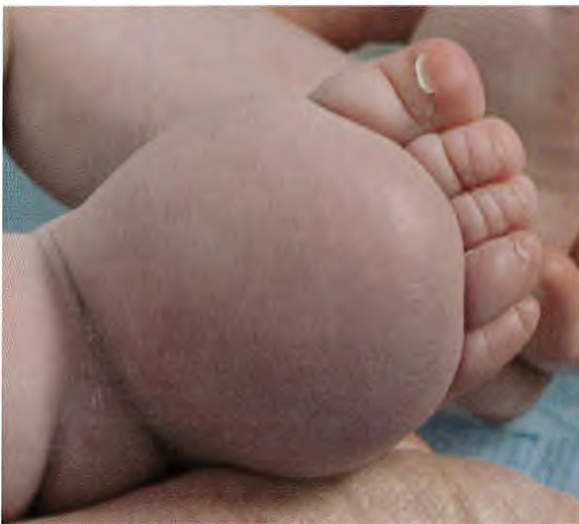

Fig. 11. Typical appearance of lymphoedema in Milroy disease. Characteristics of congenital presentation of foot lymphoedema: small, upturned toe nails and deep toe creases.

Lymphoedema distichiasis is a dominantly inherited condition in which the onset of lymphoedema of lower limbs (usually bilateral) is at or post-puberty (onset can be as late as in fifth decade) (50). Distichiasis is pathognomic of this disorder in the presence of lymphoedema

(Fig. 3). Lymphoscintigraphy in patients with lymphoedema distichiasis demonstrates distal lymph reflux. This is secondary to lymphatic valve failure (51). Deficient venous valves lead to venous reflux in all patients with *FOXC2* mutations (52). Early onset varicose veins are a feature of the condition. Our analyses have found that >95% of lymphoedema distichiasis patients have mutations in *FOXC2* (50). Most mutations appear to be inactivating, but a recent report suggests activation of *FOXC2* in some cases (53).

Meige/Meige-like disease is characterised by lower limb lymphoedema, rarely extending above the knee. It is more common in females (3 : 1 female : male ratio). FH is often consistent with an autosomal dominant pattern of inheritance. Those with a Meige phenotype but negative FH have been labelled as Meige-like. The lymphoedema in Meige/Meige-like does not appear in childhood, but in adolescence or adulthood. There are no other associated features of the condition and no genetic cause has been identified thus far (54).

Late onset segmental lymphoedema, affecting one or multiple body segments is also seen in a proportion of patients. Late onset multi-segmental lymphoedema is the most commonly seen ($n = 23$), followed by late onset unilateral

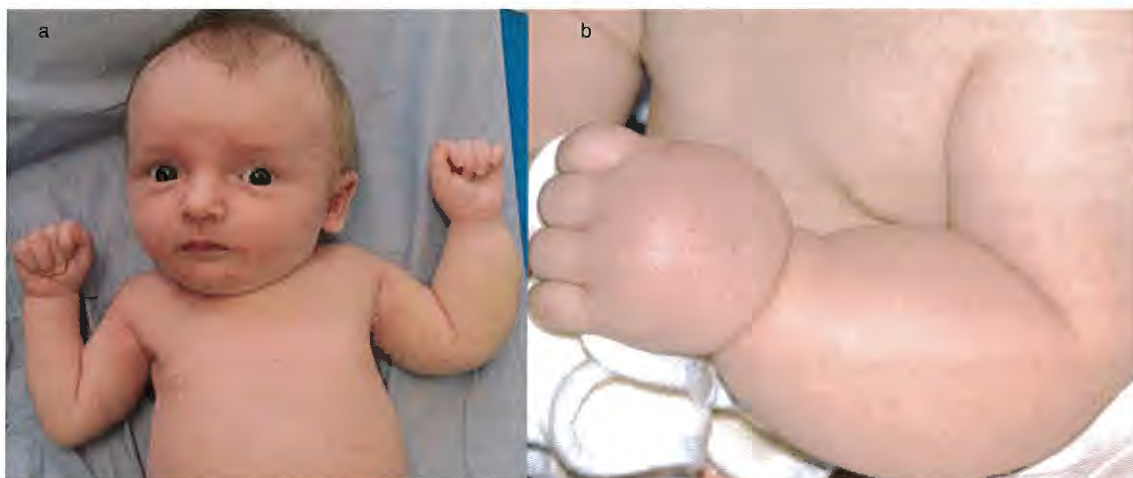


Fig. 12. (a–b) Known syndrome Number of cases Aagaard syndrome 1 Cardio-facio-cutaneous syndrome 1 CHARGE association 1 Chromosomal abnormality 7 Ectodermal dysplasia, anhidrotic, immunodeficiency, osteopetrosis, and lymphoedema 1 Lymphoedema-myelodysplasia 7 Lymphoedema-microcephaly-chorioretinopathy dysplasia 6 Megalencephaly-cutis marmorata-telangiectasia-congenita 1 Noonan syndrome 2 Prader-Willi syndrome 2 Thrombocytopenia with absent radius 1 Turners syndrome 2 Yellow nail syndrome 1 Congenital unisegmental lymphoedema of left arm (a) aged 6 weeks (b) aged 1 year.

leg lymphoedema ($n = 14$) and, least common, late onset unisegmental lymphoedema ($n = 3$) (most frequently affecting one arm), seen in 7%, 3%, and <1%, respectively of our population group. In these patients, particularly those with unilateral/unisegmental lymphoedema, the secondary causes of lymphoedema (e.g. lymph node sclerosis, filariasis, lymphatic obstruction secondary to growth of a mass) should always be excluded before diagnosing a late onset primary lymphoedema.

In the late onset multi-segmental lymphoedema cohort ($n = 23$), a proportion had a positive FH consistent with autosomal dominant inheritance, with a four limb lymphoedema phenotype. Some of these patients reported a progressive nature to their pattern of lymphoedema (i.e. started in one limb and over time other limbs became affected). Four-limb lymphatic dysfunction is not always clinically evident but is apparent on lymphoscintigraphy scans. Therefore, in order to assess the extent of the lymphatic problem, it is advisable to carry out four-limb lymphoscintigraphy in patients presenting with arm and leg swelling. Patients in this cohort did not have facial or conjunctival oedema, or systemic involvement and only two had genital involvement.

Unclassified

Six patients were not assigned a definitive diagnostic category because they were not seen in the clinic and insufficient clinical details had been provided by the referring clinician.

Discussion

Evaluation of primary lymphoedema has long been hampered by inadequate, confusing, and conflicting descriptions. Our aim in this study was to develop a new working diagnostic pathway for primary lymphoedema for use in a clinic setting. It has been demonstrated on 333 patients, thereby illustrating that it is a functional tool which can be applied when faced with the challenge of phenotyping primary lymphoedema patients. It cannot be a definitive diagnostic tool as some patients do not easily fit into one category, but with clinical experience in recognising the various presentations of lymphoedema, classification categories can be ascribed using this method of clinical phenotyping. As the genetic basis of different phenotypes emerge and the imaging of the lymphatic system improves, the hope is that this classification system will evolve and phenotypes will be further refined.

Difficulties in phenotyping some patients arose when clinical signs were ambiguous, particularly as options for investigations in lymphoedema are limited. In some patients, the history suggests possible intestinal lymphangiectasia, but rarely this diagnosis is proven on endoscopic biopsies, and has to be made on response to an MCT diet. Establishing whether or not there is disturbance of limb growth in an oedematous limb can be difficult. It has to be determined on limb length measurement as girth measurement is not useful in the presence of lymphoedema. MRI imaging may be helpful in patients in whom disturbed limb growth is suspected. Resolution of clinical signs

can confuse the picture and phenotyping in these cases can also be more difficult.

Summary

For progress to be made in genotyping conditions with primary lymphoedema, it is vital that phenotyping in this area is updated. The benefits of an updated and clinically operational pathway are summarised below:

- (1) The pathway has facilitated the recognition of groups of patients with similar phenotypes, and in doing so new conditions have been identified.
- (2) Defining phenotypes means that mutation testing can be targeted at the patients in whom it is more likely that a mutation will be found.
- (3) Recognising *in-utero* signs of lymphoedema means that a knowledge base and experience is being developed on the pattern of presentation and prognosis of prenatal onset lymphoedema. Hopefully, this experience will lead to guidelines on how to manage antenatally diagnosed lymphoedema conditions and knowledge about the natural history of the condition.
- (4) Grouping patients according to phenotype will facilitate identification of new pathogenic genes in primary lymphoedema.
- (5) Establishing likely recurrence risks, so that patients can receive useful prenatal advice.
- (6) Phenotyping patients accurately will facilitate the recognition of patterns of prognosis and development of evidence based practice with regard to the management.
- (7) This classification system will evolve as the genetic bases of the diagnostic categories are established and lymphatic imaging techniques improve. It therefore provides a good basis to start understanding the phenotypes of primary lymphoedema.

Acknowledgements

Thanks to the patients and families from our clinic. We would like to acknowledge members of the Lymphoedema Research Consortium, UK and thank the British Heart Foundation and British Skin Foundation for funding.

Conflict of interest

All authors declare no conflict of interest.

References

1. Mortimer PS. Managing lymphoedema. *Clin Exp Dermatol* 1995; 20: 98–106.

2. Smeltzer DM, Stickler GB, Schirger A. Primary lymphedema in children and adolescents: a follow-up study and review. *Pediatrics* 1985; 76: 206–218.
3. Jeltsch M, Tammela T, Alitalo K et al. Genesis and pathogenesis of lymphatic vessels. *Cell Tissue Res* 2003; 314: 69–84.
4. Oliver G, Alitalo K. The lymphatic vasculature: recent progress and paradigms. *Annu Rev Cell Dev Biol* 2005; 21: 457–483.
5. Tammela T, Petrova TV, Alitalo K. Molecular lymphangiogenesis: new players. *Trends Cell Biol* 2005; 15: 434–441.
6. Mäkinen T, Normén C, Petrova TV. Molecular mechanisms of lymphatic vascular development. *Cell Mol Life Sci* 2007; 64: 1915–1929.
7. Ferrell RE, Levinson KL, Esman JH et al. Hereditary lymphedema: evidence for linkage and genetic heterogeneity. *Hum Mol Genet* 1998; 7: 2073–2078.
8. Fang J, Dagenais SL, Erickson RP et al. Mutations in FOXC2 (MFH-1), a forkhead family transcription factor, are responsible for the hereditary lymphedema-distichiasis syndrome. *Am J Hum Genet* 2000; 67: 1382–1388.
9. Irrthum A, Devriendt K, Chitayat D et al. Mutations in the transcription factor gene SOX18 underlie recessive and dominant forms of hypotrichosis-lymphedema-telangiectasia. *Am J Hum Genet* 2003; 72: 1470–1478.
10. Ferrell RE, Kimak MA, Lawrence EC et al. Candidate gene analysis in primary lymphedema. *Lymphat Res Biol* 2008; 6: 69–76.
11. Finegold DN, Schacht V, Kimak MA et al. HGF and MET mutations in primary and secondary lymphoedema. *Lymph Res and Biol* 2008; 6: 65–68.
12. Connell F, Kalidas K, Ostergaard P et al. Linkage and sequence analysis indicate that CCBE1 is mutated in recessively inherited generalised lymphatic dysplasia. *Hum Genet* 2010; 127: 231–241.
13. Alders M, Hogan BM, Gjini E et al. Mutations in CCBE1 cause generalized lymph vessel dysplasia in humans. *Nat Genet* 2009; 41 (12): 1272–1274.
14. Allen EV. Lymphoedema of the extremities. Classification, etiology and differential diagnosis: A study of three hundred cases. *Arch Intern Med* 1934; 54: 606–624.
15. Kinmonth JB, Taylor GW, Tracey GD et al. Primary lymphoedema: Clinical and lymphangiographic studies of a series of 107 patients in which the lower limbs were affected. *Br J Surg* 1957; 45: 1–10.
16. Levine C. Primary disorders of the lymphatic vessels—a unified concept. *J Pediatr Surg* 1989; 24: 233–240.
17. Browse NL, Stewart G. Lymphoedema: pathophysiology and classification. *J Cardiovasc Surg* 1985; 26: 91–106.
18. Hilliard RI, McKendry JB, Phillips MJ. Congenital abnormalities of the lymphatic system: A new clinical classification. *Pediatrics* 1990; 86: 988–993.
19. Miller AJ, Bruna J, Beninson J. A universally applicable clinical classification of lymphedema. *Angiology* 1999; 50: 189–192.
20. Shinawi M. Lymphedema of the lower extremity: is it genetic or nongenetic? *Clin Pediatr* 2007; 46: 835–841.
21. Opitz JM. On congenital lymphedema. *Am J Med Genet* 1986; 24: 127–129.
22. Mulliken JB, Glowacki J. Hemangiomas and vascular malformations in infants and children: a classification based on endothelial characteristics. *Plast Reconstr Surg* 1982; 69: 412–422.
23. Cohen MM Jr. Vascular update: morphogenesis, tumors, malformations, and molecular dimensions. *Am J Med Genet A* 2006; 140: 2013–2038.
24. Garzon MC, Huang JT, Enjolras O et al. Vascular malformations: Part I. *J Am Acad Dermatol* 2007; 56: 353–370.

25. Garzon MC, Huang JT, Enjolras O et al. Vascular malformations. Part II: associated syndromes. *J Am Acad Dermatol* 2007; 56: 541–564.
26. Oduber C, van der Horst CM, Hennekam RCM. Klippel-Trenaunay Syndrome: Diagnostic Criteria and Hypothesis on Etiology. *Ann Plast Surg* 2008; 60: 217–223.
27. Biesecker L. The challenges of Proteus syndrome: diagnosis and management. *Eur J Hum Genet* 2006; 14: 1151–1157.
28. Connell FC, Ostergaard P, Carver C et al. Analysis of the coding regions of VEGFR3 and VEGFC in Milroy disease and other primary lymphoedemas. *Hum Genet* 2009; 124 (6): 625–631.
29. London Dysmorphology database (Winter-Baraitser Dysmorphology Database) <http://www.lmdatabases.com/> Last accessed on 2003.
30. Aagaes O, Sigstad H, Bjorn-Hansen R. Lymphoedema in hereditary recurrent cholestasis from birth. *Arch Dis Child* 1970; 45: 690–695.
31. Leung AK. Dominantly inherited syndrome of microcephaly and congenital lymphedema. *Clin Genet* 1985; 27: 611–612.
32. Mucke J, Hoepffner W, Scheerschmidt G et al. Early onset lymphoedema, recessive form - a new form of genetic lymphoedema syndrome. *Eur J Pediatr* 1986; 145: 195–198.
33. Hennekam RC, Geerdink RA, Hamel BC et al. Autosomal recessive intestinal lymphangiectasia and lymphedema, with facial anomalies and mental retardation. *Am J Med Genet* 1989; 34: 593–600.
34. Irons MB, Bianchi DW, Geggel RL et al. Possible new autosomal recessive syndrome of lymphedema, hydroceles, atrial septal defect, and characteristic facial changes. *Am J Med Genet* 1996; 66: 69–71.
35. Glade C, van Steensel MA, Steijlen PM. Hypotrichosis, lymphedema of the legs and acral telangiectasias—new syndrome? *Eur J Dermatol* 2001; 11: 515–517.
36. Doffinger R, Smahi A, Bessia C et al. X-linked anhidrotic ectodermal dysplasia with immunodeficiency is caused by impaired NF-kappa-B signaling. *Nat Genet* 2001; 27: 277–285.
37. Kreuter A, Hochdorfer B, Brockmeyer NH et al. A human papillomavirus-associated disease with disseminated warts, depressed cell-mediated immunity, primary lymphedema, and anogenital dysplasia: WILD syndrome. *Arch Dermatol* 2008; 144 (3): 366–372.
38. Daniel-Spiegel E, Ghalamkarpour A, Spiegel R et al. Hydrops fetalis: an unusual prenatal presentation of hereditary congenital lymphedema. *Prenat Diagn* 2005; 25: 1015–1018.
39. Ghalamkarpour A, Debauche C, Haan E et al. Sporadic in utero generalised edema caused by mutations in the lymphangiogenic genes VEGFR3 and FOXC2. *J Pediatr* 2009; 155 (1): 90–93.
40. Jeffries GH, Chapman A, Slesinger M. Low fat diet in intestinal lymphangiectasia. *N Eng J Med* 1964; 270: 761–767.
41. Vignes S, Bellanger J. Primary intestinal lymphangiectasia (Waldmann's disease). *Orphanet J Rare Dis* 2008; 3: 5.
42. Dervendizi Sikova D, Pavlova LT, V'ickova Laskoska MT et al. Naevus varicosus osteohypertrophicus. An early diagnostic approach. *Adv Exp Med Biol* 1999; 455: 535–540.
43. Furness PD, Bisignani G et al. Klippel-Trénaunay syndrome: 2 case reports and a review of genitourinary manifestations. *J Urol* 2001; 166: 1418–1420.
44. Mulliken JB. Cutaneous vascular anomalies. *Semin Vasc Surg* 1993; 6: 204–218.
45. Connell FC, Homfray T, Thilaganathan B et al. Congenital vascular malformations: a series of five prenatally diagnosed cases. *Am J Med Genet* 2008; 146 (20): 2673–2680.
46. Milroy WF. An undescribed variety of hereditary oedema. *New York Med J* 1892; 56: 503.
47. Brice G, Child AH, Evans A et al. Milroy disease and the VEGFR3 mutation phenotype. *J Med Genet* 2005; 42: 98–102.
48. Carver C, Brice G, Mansour S et al. Three children with Milroy disease and de novo mutations in VEGFR3. *Clin Genet* 2007; 71: 187–189.
49. Ghalamkarpour A, Morlot S, Raas-Rothschild A et al. Hereditary lymphedema type I associated with VEGFR3 mutation: the first de novo case and atypical presentations. *Clin Genet* 2006; 70: 330–335.
50. Brice G, Mansour S, Bell R et al. Analysis of the phenotypic abnormalities in lymphoedema-distichiasis syndrome in 74 patients with FOXC2 mutations or linkage to 16q24. *J Med Genet* 2002; 39: 478–483.
51. Petrova TV, Karpanen T, Norrmén C et al. Defective valves and abnormal mural cell recruitment underlie lymphatic vascular failure in lymphedema distichiasis. *Nat Med* 2004; 10: 974–981.
52. Mellor RH, Brice G, Stanton AW, French J et al. Mutations in FOXC2 are strongly associated with primary valve failure in veins of the lower limb. *Circulation* 2007; 115: 1912–1920.
53. van Steensel MA, Damstra RJ, Heitink M et al. Novel missense mutations in the FOXC2 gene alter transcriptional activity. *Hum Mutat* 2009; 30 (12): E1002–E1009.
54. Rezaie T, Ghoroghchian R, Bell R et al. Primary non-syndromic lymphoedema (Meige disease) is not caused by mutations in FOXC2. *Eur J Hum Genet* 2008; 16: 300–304.

