

A Prospective Model of Care for Breast Cancer Rehabilitation: Postoperative and Postreconstructive Issues*

Margaret L. McNeely, PT, PhD¹; Jill M. Binkley, PT, MCISc, FAAOMPT, CLT²; Andrea L. Pusic, MD, MHS³; Kristin L. Campbell, PT, PhD⁴; Sheryl Gabram, MD, MBA, FACS⁵; and Peter W. Soballe, MD, CAPT⁶

Appropriate and timely rehabilitation is vital in the recovery from breast cancer surgeries, including breast conserving surgery, mastectomy, axillary lymph node dissection (ALND), and breast reconstruction. This article describes the incidence, prevalence, risk factors and time course for early postoperative effects and the role of prospective surveillance as a rehabilitation strategy to prevent and mitigate them. The most common early postoperative effects include wound issues such as cellulitis, flap necrosis, abscess, dehiscence, hematoma, and seroma. Appropriate treatment is necessary to avoid delay in wound healing that may increase the risk of long-term morbidity, unduly postpone systemic and radiation therapy, and delay rehabilitation. The presence of upper quarter dysfunction (UQD), defined as restricted upper quarter mobility, pain, lymphedema, and impaired sensation and strength, has been reported in over half of survivors after treatment for breast cancer. Moreover, evidence suggests that survivors who undergo breast reconstruction may be at higher risk of UQD. Ensuring the survivor's optimum functioning in the early postoperative time period is critical in the overall recovery from breast cancer. The formal collection of objective measures along with patient-reported outcome measures is recommended for the early detection of postoperative morbidity. Prospective surveillance, including preoperative assessment and structured surveillance, allows for early identification and timely rehabilitation. Early evidence supports a prospective approach to address and minimize postoperative effects. *Cancer* 2012;118(8 suppl):2226-36. © 2012 American Cancer Society.

KEYWORDS: breast cancer, mastectomy, lymph node excision, breast reconstruction, shoulder, quality of life, lymphedema, rehabilitation.

INTRODUCTION

Postoperative morbidity from breast or axillary procedures for breast cancer is reported to be as high as 30%.¹ Fortunately, the vast majority of these sequelae can be managed in the outpatient setting. Appropriate and timely rehabilitation is vital in the recovery from breast cancer surgeries, including breast conserving surgery, mastectomy, axillary lymph node dissection (ALND), and reconstruction.² This article describes the incidence, prevalence, risk factors, and time course for early postoperative effects and the role of prospective surveillance as a rehabilitation strategy to prevent and mitigate them.

The focus of this article is on acute postoperative effects occurring in survivors within the first 3 months after surgery. According to the National Coalition of Cancer Survivors, a cancer survivor is defined as an individual with cancer from the "point of diagnosis through the balance of life."³

ACUTE POSTOPERATIVE SEQUELAE AFTER BREAST CANCER SURGERY

The most common early sequelae after surgery for breast cancer include wound problems such as cellulitis, flap necrosis, abscess, dehiscence, and hematoma (Table 1).¹ Appropriate treatment for these sequelae varies depending on severity: from mild cellulitis to frank abscess, minimal necrosis at the margin to total flap loss, or slight swelling or bruising to painful collections of serum or symptomatic blood loss. These sequelae may increase the risk for long-term morbidity, unduly postpone systemic and radiation therapy, and delay rehabilitation.

Corresponding author: Margaret L. McNeely, PT, PhD, Department of Physical Therapy, University of Alberta & Cross Cancer Institute, 2-05 Corbett Hall, Edmonton, Alberta, Canada T6G 2G4; Fax: (780) 492-4429; mmcneely@ualberta.ca

¹Department of Physical Therapy and Oncology, University of Alberta and Cross Cancer Institute, Edmonton, Alberta, Canada; ²TurningPoint Women's Health Care, Atlanta, Georgia; ³Division of Plastic and Reconstructive Surgery, Memorial Sloan-Kettering Cancer Center, New York, New York; ⁴Department of Physical Therapy, Faculty of Medicine, University of British Columbia, Vancouver, British Columbia, Canada; ⁵Winship Cancer Institute of Emory University, Atlanta, Georgia; ⁶Department of Surgery, Naval Medical Center San Diego, San Diego, California

The articles in this supplement were commissioned based on presentations and deliberations at a *Roundtable Meeting on a Prospective Model of Care for Breast Cancer Rehabilitation*, held February 24-25, 2011, at the American Cancer Society National Home Office, in Atlanta, Georgia.

The opinions or views expressed in this supplement are those of the authors, and do not necessarily reflect the opinions or recommendations of the editors or the American Cancer Society.

*A *Prospective Surveillance Model for Rehabilitation for Women with Breast Cancer, Supplement to Cancer*

DOI: 10.1002/cncr.27468, **Received:** October 17, 2011; **Accepted:** November 7, 2011, **Published online** April 6, 2012 in Wiley Online Library (wileyonlinelibrary.com)

Table 1. Definition of Terms Associated with Postsurgical Sequelae

Term	Definition
Cellulitis	An acute, spreading infection of the deep tissues of the skin and muscle; causes the skin of the breast to become red-ened, warm, and tender and may also cause fever, chills, swollen lymph nodes, and blisters ⁷⁵
Flap	A portion of muscle, fat, and skin; its blood supply is moved from one part of the body to the chest to reconstruct the breast ⁷⁶
Necrosis	The death of living tissues such as fat, skin, and muscle ⁷⁵
Abscess	An enclosed collection of pus in tissues, organs, or confined spaces in the body; an abscess is a sign of infection, and the tissue affected is usually swollen and inflamed ⁷⁵
Dehiscence	A surgical complication wherein the surgical wound breaks open or splits along the sutured incision line ¹
Hematoma	A pool of clotted or partially clotted blood in the surgical wound ⁷⁵
Seroma	A collection of serous fluid that develops within the surgical site and usually presents under the skin in the axillary region, near the surgical incision ^{27,75}
Pneumothorax	An accumulation of air in the chest (pleural) cavity that causes the lung to collapse ⁷⁶
Brachial plexopathy	Impairment or damage to the network of nerves in the brachial plexus; if damage occurs, this condition presents as numbness, tingling, pain, weakness, or limited movement in the arm or hand ⁷⁷
Mondor's disease	A thrombophlebitis of the subcutaneous veins that commonly occurs below the breast on the anterolateral thoracoabdominal wall ⁷
Chylothorax	Damage to the thoracic duct (a major lymph vessel in the chest) that can cause leakage of chyle (fat-containing lymph fluid) into the space between the pleural membranes that cover the lungs and line the chest cavity ⁷⁶
Axillary web syndrome	Also referred to as axillary cording; presents as tight, fibrous cords in the axilla that can extend along the arm to the antecubital fossa and forearm ²⁷

Disruption of superficial and in-breast lymphatics may lead to a diffuse pattern of erythema mimicking cellulitis without an actual infectious process.¹ Such lymphatic congestion may be differentiated from infection by placing the survivor supine and observing; the erythema of lymphatic congestion will often dissipate within a few minutes. Mild cellulitis may be treated with an oral antibiotic; more severe and symptomatic cases will require parenteral antibiotics and, in the event of abscess formation, surgical drainage.⁴ Postoperative breast abscesses may sometimes be manageable with closed aspiration and antibiotics but usually require drainage, especially if a foreign body, such as an implant, is present. Limited skin necrosis can be treated with office debridement, but frank flap loss requires surgical revision.⁵

A seroma is a collection of serous fluid in a surgical cavity. Seroma may be avoided with closed-suction drains such as those routinely used after ALND, mastectomies, and oncologic procedures.¹ When drains have been removed or are not used, a seroma will form in the cavity. This is usually a desirable outcome, reducing the chance of breast concavity after resection. However, if a seroma becomes tense and painful, or if infection is suspected, decompression is indicated. In some cases this may be accomplished by simple aspiration, repeated as necessary, but formal placement of a closed-suction drain is often required.¹

Pneumothorax may rarely result from wire-localization of nonpalpable lesions for excision or from deep dissection in the intercostal space.¹ It may present as

shortness of breath or difficulty with ventilation under anesthesia or as subcutaneous emphysema with crepitus. Symptomatic pneumothorax is treated by re-expansion of the lung with a chest tube or catheter aspiration.

Brachial plexopathy, usually the result of operative positioning, is important to identify as early as possible during the postoperative course, because early physical therapy can result in complete and rapid recovery.^{1,6} The plexopathy usually involves paresis of the arm with sensory changes distinct from the usually minor paresthesias caused by the much more common injury to intercostal-brachial nerves during axillary surgery.⁶

Mondor's disease (thrombosis of the lateral thoracic and/or thoraco-epigastric veins) presents as a firm tender cord of tissue traversing the upper abdomen into the lower part of the breast.⁷ This condition may occur after any breast trauma or surgery and is generally self-limiting, resolving within 2-8 weeks. Heat and anti-inflammatory medications may help control symptoms and hasten recovery.⁸

Finally, a rare complication of ALND is chylothorax due to injury of the thoracic duct (left side) or other major lymphatic channel.⁹ Octreotide and closed-suction drainage have been recommended to control lymphorrhea,¹⁰ but surgical duct ligation is generally required.

Advancements in surgical technique and the transition from complete ALND to sentinel lymph node biopsy (SLNB) have greatly decreased the incidence of these postoperative sequelae. In a recent retrospective study involving 6847 survivors, overall rates of sequelae of 11.1%,

7.3%, and 2.6% were found after ALND, SLNB followed by ALND, and SLNB alone, respectively.¹¹ Although many sequelae have been reduced by SLNB, they have not been eliminated, and careful monitoring of these breast cancer survivors is still warranted.

SEQUELAE OF THE UPPER QUARTER

Upper quarter dysfunction (UQD) commonly occurs after surgery and radiotherapy for breast cancer. UQD is defined as restricted upper quarter mobility, pain, lymphedema, and impaired sensation and strength.^{12,13} UQD is a significant cause of disability¹⁴ and negatively impacts quality of life (QoL).^{13,15} A recent review of UQD found a widely reported variation in prevalence of impaired shoulder range of motion (ROM) (<1%-67%), arm weakness (9%-28%), shoulder/arm pain (9%-68%), and lymphedema (0%-34%).¹⁷ In the early postoperative period, UQD may be due to the operation itself or to pain, immobility, infection, or axillary web syndrome (AWS). Although UQD is reduced with newer techniques such as SLNB, it is still prevalent.^{16,17} Findings of a randomized controlled trial reported postoperative morbidity in 36% of survivors undergoing SLNB and in 66% of survivors undergoing ALND.¹⁶

Pain arising from soft tissue and neural injury is a major contributor to UQD.¹⁸ In a recent review, the prevalence of shoulder and/or arm pain was reported to be between 9% and 68%, and the prevalence of breast and/or scar pain was between 15% and 72% at 6-56 months after surgery.¹⁹ Damage to nerves can cause sensory disturbance such as numbness, pins and needles, and burning or prickling sensations.^{20,21} In particular, injury to the intercostal-brachial nerve leads to sensory disturbances and sometimes pain involving the chest wall, axilla, and medial upper arm.²² Arm motion will stress the surgical incision and may thereby increase discomfort and lead to localized muscle guarding.²³ Wound issues and infection may worsen and prolong incisional pain and cause restrictive scarring of underlying tissues in the chest wall.²³ Timely identification and treatment of acute postoperative pain may reduce the risk of development of a chronic pain state.¹⁸

AWS is a sequela of both ALND and SLNB that can further contribute to pain and UQD. It presents as a series of cordlike structures that are visible and palpable beneath the axillary skin. These cords often extend down the arm past the elbow into the forearm, sometimes as far as the wrist or thumb.^{24,25} In some cases, cords can be seen on the chest wall caudal to the axilla.²⁶ AWS may be due to disruption of lymphatic vessels and veins during axillary

surgery²⁷ and is similar in etiology to Mondor's disease.^{7,28} The incidence of AWS has been reported in a number of recent prospective studies and ranges widely among studies (Table 2). The reported incidence after SLNB is 20%²⁹ and after ALND ranges from 44% to 72%.^{24,26,29-31} AWS has been reported to occur more often in survivors who are younger and slimmer.^{29,31} AWS develops in the early weeks after surgery, often after an initially normal course of shoulder recovery. Typically, the survivor complains of insidious onset of intense pain accompanied by limitation in ROM, especially when the arm is abducted.²⁶ Although AWS is generally a benign, self-limiting condition, it is painful and can significantly limit ROM and function in the early postoperative weeks. Moreover, symptoms may occasionally persist for much longer periods. No preventive measures for AWS have been identified; however, early evidence supports physical therapy treatment to improve symptoms associated with AWS³⁰ and shorten the natural course of the condition.³¹ Additionally, evidence from a case series suggests that mild cases of localized cording in the axilla may resolve after a short course of treatment with anti-inflammatory agents.⁷

Survivors who undergo ALND or SLNB are also at risk of developing lymphedema as a result of damage to, or dysfunction of, the lymphatic system. In the early postoperative period, edema may arise in the axilla, chest wall, breast, or arm. This acute edema is most often transient.²² Cases of persistent or worsening edema should be investigated for causes such as wound infection or seroma²² or the onset of actual lymphedema. The estimated incidence of lymphedema is between 6% and 30%,¹⁷ with the majority of cases presenting within the first 6 months after surgery.³² Risk factors for lymphedema include total versus partial mastectomy, ALND, the presence of tumor-positive nodes, and postoperative infection.³³⁻³⁵ Lymphedema may be transient or persistent.³⁶ Transient or acute lymphedema is defined as a single episode of swelling that lasts <3 months and dissipates with or without treatment. Recurring episodes of transient lymphedema may be an early sign of lymphatic compromise and are therefore of concern. Lymphedema that lasts >3 months is considered persistent or chronic lymphedema.³⁶ In a cohort study involving 287 survivors, transient lymphedema was found to occur in 20% of survivors, and persistent lymphedema occurred in 13%.¹² Lymphedema creates considerable disability and has deleterious effects on QoL.¹⁵ Risk-reduction strategies and early identification and treatment have been shown to reduce the incidence of lymphedema.³⁷⁻³⁹ Thus, close monitoring for signs of lymphedema in the early postoperative period is warranted.

Table 2. Prospective Studies Reporting the Incidence of Axillary Web Syndrome

Study	Study Type	Sample Size	Lymph Node Dissection Procedure	Incidence/Prevalence Postoperatively	Incidence/Prevalence at 2-3 mo	Incidence/Prevalence at Later Follow-up
Johansson et al ²⁶	Prospective cohort	90	ALND	40/90 (44%) at 1 mo	21/90 (23%) unresolved at 2 mo	4% (4/90) reported at 6 mo
Leidenius et al ²⁹	Prospective cohort	85	SLNB, AC	SLNB: 10/49 (20%) at 2 wk; AC: 26/36 (72%) at 2 wk	1/49 (2%) at 3 mo; 1/36 (3%) at 3 mo	Not reported
Lauridsen et al ³⁰	Randomized controlled trial	139	ALND	79/139 (57%) at 7 wk	43/139 (31%) at 13-15 wk	15% at 6 mo; all resolved by 12-mo follow-up
Torres Lacomba et al ³¹	Prospective cohort	116	ALND	53/116 (46%) at 2 wk	2/116 (2%) at 3 mo	3% (3/116) had onset later than 3 mo; 3% (4/116) had recurrence of AWS at later date
Yang et al ⁶⁹	Prospective cohort	191	SLNB, ALND	Not assessed	1/191 (0.5%) at 3 mo	Only a few survivors complained of AWS over the 12-mo follow-up period

AC, axillary clearance; ALND, axillary lymph node dissection; AWS, axillary web syndrome; SLNB, sentinel lymph node biopsy.

SEQUELAE AFTER BREAST RECONSTRUCTION

Survivors are often offered immediate breast reconstruction after mastectomy, and these survivors may develop chronic pain and physical dysfunction. For survivors electing autologous reconstruction, this morbidity may involve not only the chest and upper body, but also the donor site from which tissue was harvested. Survivors who undergo implant reconstruction may experience increased breast pain compared with mastectomy survivors, and those who undergo transverse rectus abdominal myocutaneous (TRAM) reconstruction may experience persistent abdominal pain even 2 years after surgery.^{40,41} Donor site morbidity can include not only pain and parasthesia, but also weakness and abdominal bulging that may impair daily physical function. The impact of such functional problems may be subtle, but may nevertheless impact QoL.⁴²⁻⁴⁵ Unfortunately, a limited number of studies have examined the physical and functional effects of reconstruction. A summary of potential issues related to the various reconstructive methods is provided in Table 3.

The Relationship between Reconstruction, Chemotherapy and Radiation Therapy

Postmastectomy reconstruction may be performed either before or after adjuvant chemotherapy. There are only limited prospective data on the complications of postmastectomy reconstruction when associated with chemotherapy administration. In a prospective trial comparing 3 groups of survivors undergoing immediate postmastectomy reconstruction (neoadjuvant, adjuvant, and no chemotherapy), no differences were found in unplanned surgical procedures, implant/expander loss, nor donor site complications.⁴⁶ The highest infection rate (44%) was in the adjuvant group receiving reconstruction prior to chemotherapy. Infection rates for survivors receiving neoadjuvant chemotherapy or no chemotherapy were similar at 23% and 25%, respectively. Thus, survivors need to be made aware of the rates of infection in these settings, and an individual treatment plan established based on the survivor's understanding of potential sequelae and delays for adjuvant treatment and / or rehabilitation.

Some survivors require radiation therapy after immediate postmastectomy reconstruction, and this may lead to capsular contraction and fat necrosis/contracture of the reconstructed breast. There is significant debate in the literature on the best reconstructive approach for this group of survivors.⁴⁷ Options include delayed reconstruction until completion of all therapies, delayed-immediate reconstruction with skin sparing mastectomy and

Table 3. Physical and Functional Effects Related to Breast Reconstruction

Reconstruction Method	Description	Potential Complications
Implant-based reconstruction	Placement of an implant behind the pectoralis major muscle; implants may be comprised of a saline solution or silicone gel or combination ⁷⁶	Decreased extensibility and strength of pectoral muscle ⁷⁸
Pedicled TRAM flap	Transfer of fat, abdominal skin, and one or both rectus abdominus muscles, which are tunneled under the diaphragm ⁷⁶	Abdominal wall weakness with/without herniation ⁴⁹ Loss of trunk extensor strength ⁷⁹ Back pain/increases in back pain ⁸⁰
Free flap TRAM	Skin, fat, and a small portion of the lower rectus abdominus muscle is removed; microvascular surgery is performed to transplant the flap to the mastectomy site ⁷⁶	Pain: reconstructed breast, abdominal area, axilla, neck, and back ⁸¹
DIAP flap TRAM	Preserves the anterior rectus sheath and integrity of abdominal muscle. Removes only the lower abdominal skin and fat along with deep inferior epigastric vessels, an artery, and a vein at the bottom of the rectus abdominis muscle ⁷⁶	Abdominal weakness: less weakness than pedicled or free flap TRAM ⁷⁹
Latissimus flap reconstruction	Often combined with a tissue expander or implant; the latissimus muscle flap, with or without attached skin, is elevated off of the back and brought around to the front of the chest wall; the main thoracodorsal vessels remain attached to the body to ensure proper blood supply to the flap ⁷⁶	Shoulder pain ⁷³ Impairment in shoulder flexion ROM ⁸² Impairment in shoulder strength and function ⁸³ Difficulty with functional tasks (eg, reaching overhead) and athletic activities (eg, tennis, golf) ⁸⁴

DIAP, deep inferior epigastric artery perforation; ROM, range of motion; TRAM, transverse rectus abdominus muscle

temporary expander, or immediate reconstruction with tissue flaps with or without implant/expander. When the likelihood of postmastectomy radiation is not known, delayed-immediate reconstruction should be strongly considered. However, Cowen et al⁴⁸ identified 3 factors that predict a high rate of failure for survivors undergoing implant/tissue expander reconstruction with radiation: smoking, T3/T4 tumors, and axillary lymph node involvement. In the absence of all 3 of the above factors, reconstructive failure occurred in 7% of survivors. In the presence of 1, 2, or 3 factors, failures occurred in 15.7%, 48.3%, and 100% of survivors, respectively. Completely autologous reconstruction could potentially lower these rates.⁴⁹ For these reasons, preoperative assessment of risk and education of survivors by surgeons and other health care providers regarding potential reconstruction failures can improve survivors' decision making and minimize complication rates for those requiring radiation therapy to the chest wall.

Early Versus Delayed Reconstruction

Survivors who undergo mastectomy may elect to undergo delayed reconstruction. While immediate reconstruction is associated with a higher risk of early complications⁵⁰⁻⁵², delayed reconstruction means living without a breast for a period of time, which can significantly reduce QoL.^{42,45,53,54} Delay may also compromise cosmetic results, because the remaining breast skin is less supple and able to conform to the appearance of a natural breast. There is little evidence to suggest, however, that the

timing of reconstruction influences long-term physical morbidity. A recent large-scale, prospective survey in the United Kingdom noted that physical well-being at 18 months was not significantly different for delayed versus immediate breast reconstruction (<http://www.ic.nhs.uk/mbr>), a result also found in single-surgeon experiences.^{4,11,55,56}

THE CLINICAL IDENTIFICATION OF POSTOPERATIVE EFFECTS

Diagnosis of postoperative problems traditionally relies on clinical evaluation by the surgeon or oncologist. In a busy clinical practice, however, physicians may not thoroughly probe for new and existing problems, especially those related to UQD or reconstruction. Additionally, once survivors complete active treatment, the frequency of their medical interactions decreases, as do opportunities to express their concerns. Little effort has been made to standardize the assessment of UQD and other postoperative sequelae, especially after breast reconstruction, thus the evidence base to support efficient surveillance is weak.

The assessment of UQD in the early postoperative time period may be best served by a multidisciplinary team approach. New approaches to the detection of postoperative morbidity may involve formal collection of objective measures and patient-reported outcome (PRO) data by the health care team. Breast surgery-specific PRO measures, such as the BREAST-Q, have been developed using newer psychometric methods (Item Response

Theory and Rasch).⁵⁷ These psychometric methods facilitate development of PRO measures that can be considered sensitive, valid, and reliable not only for research, but also for clinical care. At Memorial Sloan Kettering Cancer Center, breast cancer survivors regularly complete the BREAST-Q (Figure 1), which evaluates chest, upper body, and, for TRAM recipients, abdomen and trunk dysfunction. Reports and a graphic display are transmitted to the electronic medical record. Surgeons and other health care providers may thus efficiently review survivor reports of symptoms. This type of clinical surveillance facilitates more timely therapeutic interventions.

Objective measurements, similar to those used in a standard upper quarter evaluation, are used in conjunction with a standard clinical examination to evaluate UQD. Baseline measurements should be performed preoperatively. They include assessment of shoulder ROM using a universal goniometer for active and passive forward flexion, abduction, internal rotation, external rotation, and horizontal abduction.⁵⁸ Upper extremity strength is assessed by manual muscle testing, isokinetic dynamometry, or through the repetition maximum method.⁵⁹ Arm function is assessed using a PRO measure such as the Disabilities of the Arm, Shoulder and Hand scale⁶⁰ or Upper Extremity Functional Index.⁶¹ These outcome measures are addressed in more detail elsewhere in this issue.⁶²

Limb girth, water displacement volumetry, optoelectric perometry, and bioelectrical impedance are all valid and reliable methods to quantify upper limb volume and identify lymphedema.⁶³⁻⁶⁶ Preoperative measurement of limb volumes is important to define any pre-existing differences due to arm dominance or activity level and to permit earlier identification of subclinical lymphedema.³⁷

The evaluation of the survivor's self-report of pain type, location, intensity, and pattern (ie, factors that alleviate or worsen pain) are critical components of the baseline and subsequent evaluations.²⁷ Pain may be assessed using a visual analogue scale, pain questionnaire, or a PRO measure such as the BREAST-Q. Adequacy of pain relief should be re-evaluated regularly.

TREATMENT APPROACHES FOR UQD

A study by Box et al⁶⁷ demonstrated the efficacy of a comprehensive physiotherapy management care plan for UQD that involves pre- and postoperative assessments of shoulder ROM with a progressive exercise program, lymphedema awareness, and individualized treatment. Moreover, a comprehensive review by Harris et al²⁷ provides a

summary and specific rehabilitation goals for addressing postoperative UQD. A recent prospective study has reinforced the importance of preoperative assessment and structured follow-up in identifying and treating UQD.⁶⁸ In 94 survivors with newly diagnosed breast cancer (stage I-III), a physical therapist completed an assessment of upper extremity ROM and strength, as well as volume and circumferences, preoperatively and at 1, 3-6, and 12 months. All participants were given an exercise program and education. The study used structured surveillance to identify survivors who would benefit from referral for additional physical therapy for UQD. At the 1-month visit, ROM, strength, and function were significantly reduced from preoperative values; but most survivors returned to baseline levels at 1-year with this approach.

Treatments for UQD in the postoperative period include therapeutic exercise as well as manual therapy techniques for AWS and limitations in tissue extensibility. A recent study by Torres Lacomba et al³⁹ compared physiotherapy intervention initiated between 3 and 5 days postoperatively with a control group that received education only. The intervention included manual lymph drainage, stretching, resisted exercise, and treatment for AWS when applicable. The results of this study were suggestive of a relationship between AWS and increased risk of lymphedema and a possible preventative effect of the intervention related to lymphedema. Further work is needed to identify the components of the intervention that were responsible for the treatment effect and the benefit of manual therapy approaches in the early postoperative period.

Upper extremity exercise is a key component of current postoperative care to address UQD. There is ongoing debate, however, regarding the relative benefits and harms of early versus delayed postoperative upper extremity exercise as well as differing perspectives on treatment in terms of supervision and exercise progression. The next section will focus on the evidence from research examining postoperative exercise regimens.

Postoperative Exercise

In the early postoperative days, exercise precautions may be necessary, especially after breast reconstruction.² Prolonged immobility, however, may increase the risk of UQD.^{31,69} Although initial declines in upper extremity ROM and strength usually improve, recovery is often incomplete.⁷⁰ In a Cochrane review of 10 studies, introduction of upper extremity exercise as early as postoperative day 1 after ALND showed clear short-term benefit over delayed exercise (day 5-7 postoperatively) for shoulder ROM. However, early exercise resulted in

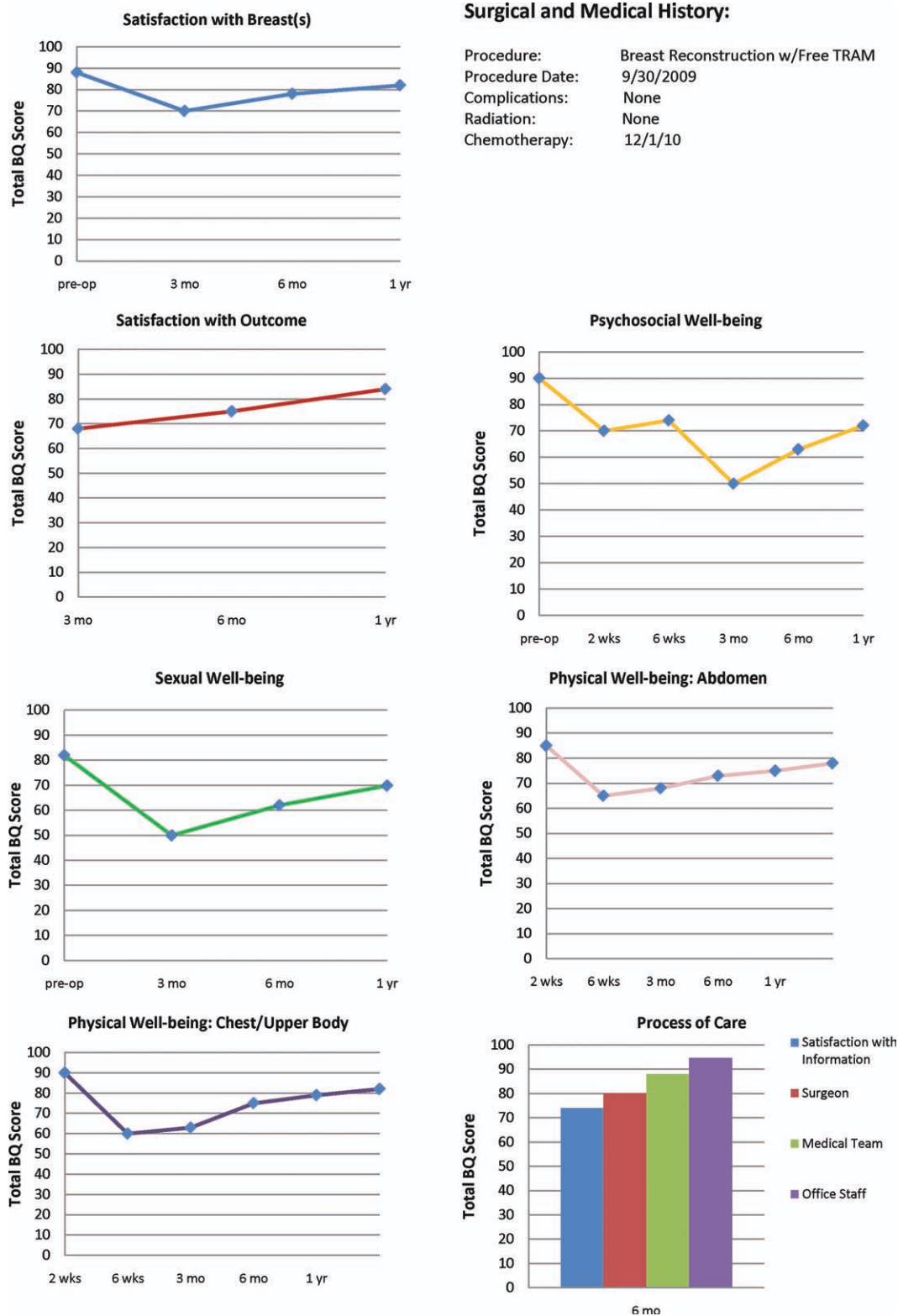


Figure 1. Patient example using the Breast Q outcome measure (higher scores reflect better functioning/ quality of life): This patient underwent immediate TRAM flap reconstruction. Surgery was uncomplicated. She began chemotherapy 2 months after surgery. Note the diminution in physical and sexual well being following surgery. Also, note that Psychosocial Well-being decreased at the start of chemotherapy. At one year after surgery, these parameters have improved and are close to her pre-operative levels.

Table 4. Risk Factors Associated With Sequelae After Breast and Axillary Surgical Procedures

Risk Factors	Wound Complications ^a	Hematoma	Seroma	Comments
Increased age	Yes	—	—	Elderly women undergoing breast surgery may be at increased risk for wound issues; preoperative education to maintain healthy nutrition prior to surgery and awareness of the increased risk of wound issues are important points to discuss with family and care takers
Diabetes and obesity (increased BMI)	Yes	—	—	Diabetes and increased BMI are risk factors for wound issues for individuals undergoing any surgical procedure
Smoking	Yes	—	—	Smoking can increase pulmonary complications postoperatively but also hinders optimal wound healing especially when plastic reconstructive surgery is performed in conjunction with the breast surgical oncology procedure
ASA, NSAIDs	—	Yes	—	It is important for surgeons and other health care providers to emphasize discontinuation of medications that increase bleeding at least 10 d to 2 wk before the procedure
Herbal supplements	—	Yes	—	Some herbal and vitamin substances such as ginseng, ginkgo biloba, garlic, and vitamin E increase bleeding and should be discontinued at least 10 d to 2 wk before the procedure
Neoadjuvant bevacizumab	Yes	Yes	—	This drug may result in delayed wound healing, wound dehiscence, bruising, surgical site bleeding, and infection—for these reasons, in the neoadjuvant setting, surgery should be scheduled 6-8 weeks after the last infusion; in the adjuvant setting, postoperative initiation of this drug is held at least 30 days to minimize complications
Excessive ROM	—	—	Yes	Limiting extensive ROM in the early postoperative setting can help to minimize drainage output
Hypertension	—	—	Yes	Hypertension has been suggested as a contributing factor in continued seroma (or lymphocele) collections and lymphedema

Abbreviations: ASA, acetylsalicylic acid; BMI, body mass index; NSAIDs, nonsteroidal anti-inflammatory drugs; ROM: range of motion.

^a Infection/cellulitis, skin necrosis, dehiscence, flap loss.

increased wound drainage requiring surgical drains to remain approximately 1 additional day. No long-term difference in shoulder ROM was found.

Although much of the literature focuses on the timing of upper extremity exercise after surgery, the intensity and rate of progression may be even more important to achieve a balance between restoring ROM and reducing wound drainage and seroma formation. The same Cochrane review examined the role of structured postoperative exercise programs, such as physical therapy, compared with usual care (eg, an exercise pamphlet).⁷¹ Structured programs significantly improved shoulder flexion ROM both in the short and long term. When the 3 studies that focused on physical therapy were analyzed separately, clear benefits in shoulder flexion and abduction were noted at 6 months, suggesting that a structured exercise program with follow-up by a physical therapist improves postoperative ROM and shoulder dysfunction. There was no difference between groups in incidence of seroma, drain volume, pain, lymphedema, or arm volume. A common thread in these studies was a structured and progressive approach to

postoperative exercise. Results suggest that upper extremity exercise with defined limits on the extent of shoulder ROM and gradual progression may restore function while minimizing sequelae in survivors undergoing lymph node dissection.

The effect of exercise after breast reconstruction was examined in 2 prospective studies. The first examined the effect of latissimus flap reconstruction on recovery of shoulder ROM.⁷² ROM was assessed preoperatively and then weekly for the first 4 weeks after mastectomy alone ($n = 46$) or mastectomy with latissimus-dorsi reconstruction ($n = 41$). All subjects had physical therapy 3 times per week for 3 weeks that included 19 exercises starting within the first 48 hours. There was no significant difference in the rate of recovery of motion. Factors associated with poorer ROM and slower recovery included the extent of axillary node dissection, current smoker, and the presence of AWS.⁷²

Shoulder ROM, strength, function, neural glide, and pain were assessed in 22 subjects with latissimus dorsi muscle flap reconstruction preoperatively and at 6 weeks, 6 months, and 6 years.⁷³ All subjects were instructed in

shoulder exercises to begin 48 hours postoperatively and were provided written information about their exercise program and recovery. At 6 weeks, there was a mean reduction in flexion ROM of 17°, minor loss of strength as measured by a spring balance and increased pain (VAS scale). These measures were found to return to presurgical levels by 6 months and were maintained at subsequent follow-up visits.

PROSPECTIVE SURVEILLANCE MODEL

Preoperative Rehabilitation Visit

The preoperative rehabilitation visit allows for the establishment of baseline measures of key outcomes including ROM, pain, strength, and upper extremity volume. This visit also provides an opportunity to evaluate pre-morbid conditions and risk factors related to surgical effects and sequelae. Individual risk factors associated with common postoperative breast or axillary procedures can be tabulated and survivors appropriately counseled (Table 4). While some risk factors cannot be altered (age and body mass index), survivors can be educated to ensure that diabetes and hypertension are under control, they have stopped smoking, they have stopped anticoagulants, and that they can adhere to specific postoperative restrictions. The visit also provides an opportunity to educate survivors regarding local effects after surgery (eg, pain and sensation loss), and to provide basic education about lymphedema risk reduction. Finally, the preoperative visit allows for instruction in the postoperative upper extremity exercise program.

Early Postoperative Rehabilitation Re-assessment

An early postoperative rehabilitation visit should be scheduled prior to initiation of adjuvant treatments.^{37,68} This serves to evaluate progress in recovery and identify any issues such as decreased ROM, AWS, weakness, pain, or donor site issues requiring rehabilitation. Moreover, this visit provides an opportunity for the survivor to ask questions and express concerns, and for the health care team to provide ongoing education, including exercise counseling. The need for ongoing rehabilitation surveillance can then be decided with survivor input and consideration of current clinical status, individual risk factors for morbidity, and the overall cancer treatment plan.

Ongoing Surveillance

Ongoing surveillance after surgery is needed to evaluate the effects of additional reconstructive phases and the interplay of adjuvant systemic therapies and radiation. Some of the sequelae of surgery (such as lymphedema) are

latent, and ongoing surveillance is critical for early identification and management.³⁷ This topic is addressed in more detail elsewhere in this issue.⁷⁴

CONCLUSIONS

There are a number of common effects associated with the surgical treatment of breast cancer. Ensuring the survivor's optimum functioning in the early postoperative time period is critical to overall recovery from breast cancer. Prospective surveillance offers the opportunity to address and minimize postoperative effects and improve outcomes associated with breast cancer.

FUNDING SOURCES

Support for this meeting and supplement was provided by the American Cancer Society through The Longaberger Company®, a direct selling company offering home products including handcrafted baskets made in Ohio, and the Longaberger Horizon of Hope® Campaign, which provided a grant to the American Cancer Society for breast cancer research and education.

CONFLICT OF INTEREST

Andrea L. Pusic is a codeveloper of the BREAST-Q patient-reported outcome measure.

REFERENCES

1. Vitug AF, Newman LA. Complications in breast surgery. *Surg Clin North Am.* 2007;87:431-451.
2. Tuohy S, Savodnik A. Postsurgical rehabilitation in cancer. In: Stubblefield M, O'Dell M, eds. *Cancer Rehabilitation: Principles and Practice.* New York, NY: Demos Medical; 2009:813-824.
3. Hewitt JA, ed. *From Cancer Patient to Cancer Survivor—Lost in Transition: An American Society of Clinical Oncology and Institute of Medicine Symposium.* Washington, DC: Institute of Medicine and National Research Council; 2006.
4. Throckmorton AD, Boughey JC, Boostrom SY, et al. Postoperative prophylactic antibiotics and surgical site infection rates in breast surgery patients. *Ann Surg Oncol.* 2009;16:2464-2469.
5. Chapman DD, Moore S. Breast cancer. In: Yarbrow HC, Frogge MH, Goodman M, eds. *Cancer Nursing: Principles and Practice.* 6th ed. Sudbury, MA: Jones and Bartlett; 2005:1022-1137.
6. American Society of Anesthesiologists Task Force on Prevention of Perioperative Peripheral Neuropathies. Practice advisory for the prevention of perioperative peripheral neuropathies: an updated report by the American Society of Anesthesiologists Task Force on prevention of perioperative peripheral neuropathies. *Anesthesiology.* 2011; 114:741-754.
7. Pappo I, Wasserman I, Stahl-Kent V, Sandbank J, Halevy A. Mondor's disease of the axilla: a rare complication of sentinel node biopsy. *Breast J.* 2004;10:253-255.
8. Pugh CM, DeWitty RL. Mondor's disease. *J Nat Med Assoc.* 1996; 88:359-363.
9. Caluwe GLF, Christiaens MRGS. Chylous leak: a rare complication after axillary lymph node dissection. *Acta Chir Belg.* 2003;103:217-218.
10. Carcoforo P, Soliani G, Maestroni U, et al. Octreotide in the treatment of lymphorrhea after axillary node dissection: a prospective randomized controlled trial. *J Am Coll Surgeons.* 2003;196:365-369.
11. Bafford A, Gadd M, Gu X, Lipsitz S, Golshan M. Diminishing morbidity with the increased use of sentinel node biopsy in breast carcinoma. *Am J Surg.* 2010;200:374-377.

12. Hayes SC, Janda M, Cornish B, Battistutta D, Newman B. Lymphedema after breast cancer: incidence, risk factors, and effect on upper body function. *J Clin Oncol*. 2008;26:3536-3542.
13. Nesvold I-L, Fossa SD, Holm I, Naume B, Dahl AA. Arm/shoulder problems in breast cancer survivors are associated with reduced health and poorer physical quality of life. *Acta Oncol*. 2010;49:347-353.
14. Thomas-Maclean RL, Hack T, Kwan W, Towers A, Miedema B, Tilley A. Arm morbidity and disability after breast cancer: new directions for care. *Oncol Nurs Forum*. 2008;35:65-71.
15. Ahmed RL, Prizment A, Lazovich D, Schmitz KH, Folsom AR. Lymphedema and quality of life in breast cancer survivors: the Iowa Women's Health Study. *J Clin Oncol*. 2008;26:5689-5696.
16. Langer I, Guller U, Berclaz G, et al. Morbidity of sentinel lymph node biopsy (SLN) alone versus SLN and completion axillary lymph node dissection after breast cancer surgery: a prospective Swiss multicenter study on 659 patients. *Ann Surg*. 2007;245:452-461.
17. Sclafani LM, Baron RH. Sentinel lymph node biopsy and axillary dissection: added morbidity of the arm, shoulder and chest wall after mastectomy and reconstruction. *Cancer J*. 2008;14:216-222.
18. Vadivelu N, Schreck M, Lopez J, Kodumudi G, Narayan D. Pain after mastectomy and breast reconstruction. *Am Surgeon*. 2008;74:285-296.
19. Lee TS, Kilbreath SL, Refshauge KM, Herbert RD, Beith JM. Prognosis of the upper limb following surgery and radiation for breast cancer. *Breast Cancer Res Treat*. 2008;110:19-37.
20. Torres Lacomba M, Mayoral del Moral O, Coperias Zazo JL, Gerwin RD, Goni AZ. Incidence of myofascial pain syndrome in breast cancer surgery: a prospective study. *Clin J Pain*. 2010;26:320-325.
21. Chevillat AL, Tchou J. Barriers to rehabilitation following surgery for primary breast cancer. *J Surg Oncol*. 2007;95:409-418.
22. Stubblefield MD, Custodio CM. Upper-extremity pain disorders in breast cancer. *Arch Phys Med Rehabil*. 2006;87(3 Suppl 1):S96-S99.
23. Kisner C, Colby L. Management of vascular disorders of the extremities. In: Kisner C, Colby L, eds. *Therapeutic Exercise: Foundations and Techniques*. Philadelphia, PA: F.A. Davis Company; 2007:825-850.
24. Moskovitz AH, Anderson BO, Yeung RS, Byrd DR, Lawton TJ, Moe RE. Axillary web syndrome after axillary dissection. *Am J Surg*. 2001;181:434-439.
25. Caban ME, Yadav R. Rehabilitation of breast cancer-related functional deficits. *Crit Rev Phys Rehabil Med*. 2008;20:1-23.
26. Johansson K, Ingvar C, Albertsson M, Ekdahl C. Arm lymphoedema, shoulder mobility and muscle strength after breast cancer treatment—a prospective 2-year study. *Adv Physiother*. 2001;3:55-66.
27. Harris SR, Campbell KL, McNeely ML. Upper extremity rehabilitation for women who have been treated for breast cancer. *Physiother Can*. 2004;56:202-214.
28. Craythorne E, Benton E, Macfarlane S. Axillary web syndrome or cording, a variant of monod disease, following axillary surgery. *Arch Dermatol*. 2009;145:1199-1200.
29. Leidenius M, Leppanen E, Krogerus L, von Smitten K. Motion restriction and axillary web syndrome after sentinel node biopsy and axillary clearance in breast cancer. *Am J Surg*. 2003;185:127-130.
30. Lauridsen MC, Christiansen P, Hessov I. The effect of physiotherapy on shoulder function in patients surgically treated for breast cancer: a randomized study. *Acta Oncol*. 2005;44:449-457.
31. Torres Lacomba M, Mayoral Del Moral O, Coperias Zazo JL, Yuste Sanchez MJ, Ferrandez J-C, Zapico Goni A. Axillary web syndrome after axillary dissection in breast cancer: a prospective study. *Breast Cancer Res Treat*. 2009;117:625-630.
32. Clark B, Sitzia J, Harlow W. Incidence and risk of arm oedema following treatment for breast cancer: a three-year follow-up study. *Quart J Med*. 2005;98:343-348.
33. Hack TF, Kwan WB, Thomas-Maclean RL, et al. Predictors of arm morbidity following breast cancer surgery. *Psychooncology*. 2010;19:1205-1212.
34. Ewertz M, Jensen AB. Late effects of breast cancer treatment and potentials for rehabilitation. *Acta Oncol*. 2011;50:187-193.
35. Tsai RJ, Dennis LK, Lynch CF, Snetselaar LG, Zamba GK, Scott-Conner C. The risk of developing arm lymphedema among breast cancer survivors: a meta-analysis of treatment factors. *Ann Surg Oncol*. 2009;16:1959-1972.
36. Chevillat AL, McGarvey CL, Petrek JA, Russo SA, Thiadens SRJ, Taylor ME. The grading of lymphedema in oncology clinical trials. *Sem Rad Oncol*. 2003;13:214-225.
37. Stout Gergich NL, Pflazer LA, McGarvey C, Springer B, Gerber LH, Soballe P. Preoperative assessment enables the early diagnosis and successful treatment of lymphedema. *Cancer*. 2008;112:2809-2819.
38. Box RC, Reul-Hirche HM, Bullock-Saxton JE, Furnival CM. Physiotherapy after breast cancer surgery: results of a randomised controlled study to minimise lymphoedema. *Breast Cancer Res Treat*. 2002;75:51-64.
39. Torres Lacomba M, Yuste Sanchez MJ, Zapico Goni A, et al. Effectiveness of early physiotherapy to prevent lymphoedema after surgery for breast cancer: randomised, single blinded, clinical trial. *BMJ* 2010;340:b5396.
40. Chatzidaki P, Mellos C, Briese V, Mylonas I. Perioperative complications of breast cancer surgery in elderly women (>80 years). *Ann Surg Oncol*. 2011;18:923-931.
41. Roth RS, Lowery JC, Davis J, Wilkins EG. Persistent pain following postmastectomy breast reconstruction: long-term effects of type and timing of surgery. *Ann Plastic Surg*. 2007;58:371-376.
42. Lee C, Sunu C, Pignone M. Patient-reported outcomes of breast reconstruction after mastectomy: a systematic review. *J Am Coll Surg*. 2009;209:123-133.
43. Davies K, Allan L, Roblin P, Ross D, Farhadi J. Factors affecting post-operative complications following skin sparing mastectomy with immediate breast reconstruction. *Breast*. 2011;20:21-25.
44. Dulin WA, Avila RA, Verheyden CN, Grossman L. Evaluation of abdominal wall strength after TRAM flap surgery. *Plast Reconstr Surg*. 2004;113:1662-1665; discussion 66-67.
45. Winters ZE, Benson JR, Pusic AL. A systematic review of the clinical evidence to guide treatment recommendations in breast reconstruction based on patient-reported outcome measures and health-related quality of life. *Ann Surg*. 2010;252:929-942.
46. Warren Peled A, Itakura K, Foster RD, et al. Impact of chemotherapy on postoperative complications after mastectomy and immediate breast reconstruction. *Arch Surg*. 2010;145:880-885.
47. Kronowitz SJ, Robb GL. Radiation therapy and breast reconstruction: a critical review of the literature. *Plast Reconstr Surg*. 2009;124:395-408.
48. Cowen D, Gross E, Rouannet P, et al. Immediate post-mastectomy breast reconstruction followed by radiotherapy: risk factors for complications. *Breast Cancer Res Treat*. 2010;121:627-634.
49. Disa JJ, McCarthy CM. Principles of breast reconstruction in cancer. In: Stubblefield MD, O'Dell MW, eds. *Cancer Rehabilitation: Principles and Practice*. New York, NY: Demos Medical; 2009:115-122.
50. Alderman AK, Wilkins EG, Kim HM, Lowery JC. Complications in postmastectomy breast reconstruction: two-year results of the Michigan Breast Reconstruction Outcome Study. *Plast Reconstr Surg*. 2002;109:2265-2274.
51. Meeske KA, Sullivan-Halley J, Smith AW, et al. Risk factors for arm lymphedema following breast cancer diagnosis in black women and white women. *Breast Cancer Res Treat*. 2009;113:383-391.
52. Alderman AK, Wilkins EG, Kim HM, Lowery JC. Complications in postmastectomy breast reconstruction: two-year results of the Michigan Breast Reconstruction Outcome Study. *Plast Reconstr Surg*. 2002;109:2265-2274.
53. Ang-Lee MK, Moss J, Yuan CS. Herbal medicines and perioperative care. *JAMA*. 2001;286:208-216.
54. Gordon CR, Rojavin Y, Patel M, et al. A review on bevacizumab and surgical wound healing: an important warning to all surgeons. *Ann Plast Surg*. 2009;62:707-709.
55. Gui GPH, Kadayaprath G, Tan S-M, et al. Long-term quality-of-life assessment following one-stage immediate breast reconstruction using biodimensional expander implants: the patient's perspective. *Plast Reconstr Surg*. 2008;121:17-24.

56. Cordeiro PG. Breast reconstruction after surgery for breast cancer. *N Engl J Med*. 2008;359:1590-1601.
57. Pusic AL, Klassen AF, Scott AM, Klok JA, Cordeiro PG, Cano SJ. Development of a new patient-reported outcome measure for breast surgery: The BREAST-Q. *Plast Reconstr Surg*. 2009;124:345-353.
58. Norkin CN, White DJ. Measurement of Joint Motion: A Guide to Goniometry. Philadelphia, PA: F.A. Davis Company; 1995.
59. Hall C, Brody L. Impairment in muscle performance. In: Hall C, Brody L, eds. *Therapeutic Exercise: Moving Towards Function*. Baltimore, MD: Lippincott Williams & Wilkins; 2005:57-86.
60. Beaton DE, Katz JN, Fossel AH, Wright JG, Tarasuk V, Bombardier C. Measuring the whole or the parts? Validity, reliability, and responsiveness of the disabilities of the arm, shoulder and hand outcome measure in different regions of the upper extremity. *J Hand Ther*. 2001;14:128-146.
61. Stratford P, Binkley J, Stratford D. Development and initial validation of the upper extremity functional index. *Physiother Can*. 2001; 53:259-267.
62. Campbell KL, Pusic AL, Zucker DS, et al. A prospective model of care for breast cancer rehabilitation: function. *Cancer*. 2012;118(suppl 8): 2300-2311.
63. Czerniec SA, Ward LC, Refshauge KM, et al. Assessment of breast cancer-related arm lymphedema—comparison of physical measurement methods and self-report. *Cancer Invest*. 2010;28:54-62.
64. Ward LC, Czerniec S, Kilbreath SL. Quantitative bioimpedance spectroscopy for the assessment of lymphoedema. *Breast Cancer Res Treat*. 2009;117:541-547.
65. McKinnon JG, Wong V, Temple WJ, et al. Measurement of limb volume: laser scanning versus volume displacement. *J Surg Oncol*. 2007;96:381-388.
66. Ridner SH, Montgomery LD, Hepworth JT, Stewart BR, Armer JM. Comparison of upper limb volume measurement techniques and arm symptoms between healthy volunteers and individuals with known lymphedema. *Lymphology*. 2007;40:35-46.
67. Box RC, Reul-Hirche HM, Bullock-Saxton JE, Furnival CM. Shoulder movement after breast cancer surgery: results of a randomised controlled study of postoperative physiotherapy. *Breast Cancer Res Treat*. 2002;75:35-50.
68. Springer BA, Levy E, McGarvey C, et al. Pre-operative assessment enables early diagnosis and recovery of shoulder function in patients with breast cancer. *Breast Cancer Res Treat*. 2010;120:135-147.
69. Yang EJ, Park W-B, Seo KS, Kim S-W, Heo C-Y, Lim J-Y. Longitudinal change of treatment-related upper limb dysfunction and its impact on late dysfunction in breast cancer survivors: a prospective cohort study. *J Surg Oncol*. 2010;101:84-91.
70. Kootstra JJ, Hoekstra-Weebers JEHM, Rietman JS, et al. A longitudinal comparison of arm morbidity in stage I-II breast cancer patients treated with sentinel lymph node biopsy, sentinel lymph node biopsy followed by completion lymph node dissection, or axillary lymph node dissection. *Ann Surg Oncol*. 2010;17:2384-2394.
71. McNeely ML, Campbell K, Ospina M, et al. Exercise interventions for upper-limb dysfunction due to breast cancer treatment. *Cochrane Database of Systematic Reviews* 2010:CD005211.
72. de Oliveira RR, Pinto e Silva MP, Gurgel MSC, Pastori-Filho L, Sar-ian LO. Immediate breast reconstruction with transverse latissimus dorsi flap does not affect the short-term recovery of shoulder range of motion after mastectomy. *Ann Plast Surg*. 2010;64:402-408.
73. Glassey N, Perks GB, McCulley SJ. A prospective assessment of shoulder morbidity and recovery time scales following latissimus dorsi breast reconstruction. *Plast Reconstr Surg* 2008;122:1334-1340.
74. Hayes SC, Johansson K, Stout NL, et al. Upper-body morbidity following breast cancer: incidence and evidence for evaluation, prevention and management within a prospective surveillance model of rehabilitation. *Cancer*. 2012;118(suppl 8):2237-2249.
75. National Cancer Institute. Dictionary of Cancer Terms. Available at: <http://www.cancer.gov/dictionary>. Accessed July 24, 2011.
76. Canadian Cancer Society. Canadian Cancer Encyclopedia. Available at: <http://info.cancer.ca/cce-ecc>. Accessed July 24, 2011.
77. Bentzen SM, Sische S. Morbidity related to axillary irradiation in the treatment of breast cancer. *Acta Oncol*. 2000;39:337-347.
78. de Haan A, Toor A, Hage JJ, Veeger HE, Woerdeman LA. Function of the pectoralis major muscle after combined skin-sparing mastectomy and immediate reconstruction by subpectoral implantation of a prosthesis. *Ann Plast Surg*. 2007;59:605-610.
79. Atisha D, Alderman AK. A systematic review of abdominal wall function following abdominal flaps for postmastectomy breast reconstruction. *Ann Plastic Surg*. 2009;63:222-230.
80. Simon AM, Bouwense CL, McMillan S, Lamb S, Hammond DC. Comparison of unipedicled and bipedicled TRAM flap breast reconstructions: assessment of physical function and patient satisfaction. *Plast Reconstr Surg*. 2004;113:136-140.
81. Dell DD, Weaver C, Kozempel J, Barsevick A. Recovery after transverse rectus abdominis myocutaneous flap breast reconstruction surgery. *Oncol Nurs Forum*. 2008;35:189-196.
82. de Oliveira RR, Pinto e Silva MP, Gurgel MS, Pastori-Filho L, Sar-ian LO. Immediate breast reconstruction with transverse latissimus dorsi flap does not affect the short-term recovery of shoulder range of motion after mastectomy. *Ann Plastic Surg*. 2010;64:402-408.
83. Forthomme B, Heymans O, Jacquemin D, et al. Shoulder function after latissimus dorsi transfer in breast reconstruction. *Clin Physiol Funct Imag*. 2010;30:406-412.
84. Adams WP Jr, Lipschitz AH, Ansari M, Kenkel JM, Rohrich RJ. Functional donor site morbidity following latissimus dorsi muscle flap transfer. *Ann Plast Surg*. 2004;53:6-11.