

Lymphedema Treatment for the Head and Neck Oncology Patient

Heidi Miranda-Walsh
OTR, CHT, CLT/LANA
May 2, 2019



Objectives

- Understand cancer as a cause of head & neck lymphedema.
- Understand how treatment of the disease (surgery, chemotherapy and radiation therapy) affect:
 - Tissues
 - Pathways of lymph flow
 - Normal function
 - **Whole person**



Objectives

- Assist in assessing and evaluating the head and neck oncology patient.
- Assist with the treatment plan to treat the head and neck oncology patient.
- Assist in gaining more confidence in the ability to apply therapeutic techniques.



Carcinoma of the Head & Neck

Medical treatment of the disease has far-reaching consequences:

- Treatment can be very invasive and debilitating.
- It can change the cosmetic appearance, affecting body image
- It can affect the most basic functions of life; respiration, swallowing, speech, hearing
- Changes in motor functioning of the face, neck and shoulder
- It can affect their weight - muscle mass
- It has a huge psychological impact
- **QA** is significantly affected, not only of the patient, but also of the family
- **Quality of life**



Everyone involved in the care of these patients needs to consider and be aware of the many factors affecting them.

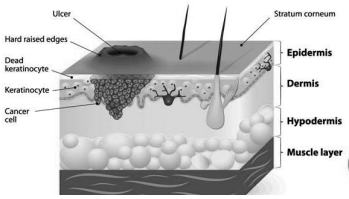


Head & Neck Cancer


- 80% are squamous cell carcinomas
 - 20% are other cancers, Melanoma, Merkle cell.
 - Thyroid cancer is treated as a separate cancer.
- Constitute 3% to 4% of all cancers in the U.S. depending on the year (3% in 2017)
 - Occurs more in men than in women
 - Usually diagnosed after age 50



Squamous-cell carcinoma



Early squamous cell carcinoma of the tongue



- This cancer begins in the flat squamous cells that make up the thin layer of tissue on the surface of the skin on the structures in the head and neck.
- Beneath the epithelium, there is a layer of moist tissue, called the mucosal surface of the upper aero-digestive track.
- If a cancer is only found in the squamous layer of cells, it is called carcinoma in situ.
- If the cancer has grown beyond this cell layer and moved into the deeper tissue, then it is called invasive squamous cell carcinoma.



Causes - Behavioral

Tobacco

- Increases the risk of developing multiple primary lesions for head & neck, lung, and of the esophagus
 - Risk ↑ with amount and duration of tobacco use
 - Takes 15–30 years of abstinence to match the lower risk of non-smokers
- **Marijuana:** Causative agent for squamous cell cancer



DRINKING ALCOHOL

- Risk increases with greater consumption
- Risk is higher if combined with smoking



Causes Occupational

- Wood workers
- Leather workers
- Metal workers and processors
- Asbestos and textile fiber processors



Causes- Viral

- Recurrent Viral Infections
- Human papilloma virus (HPV)-16
 - of patients who do *not* smoke/drink. Most oropharyngeal Ca in USA are HPV +
 - Present in 40 to 50% of patients who smoke/drink
 - **Better prognosis if it is caused by HPV**
- **Other virus:** Epstein-Barr virus (EBV), also known as human herpes virus 4, is a member of the herpes virus family. It is one of the most common human viruses. EBV is found all over the world, causes mononucleosis.



Presenting Symptoms

- Surface lesion; erythema (redness); slightly elevated; smooth or rough mucosa
- Hoarseness
- Referred pain to the ear
- Difficulty swallowing and eating
- Biting of tongue
- Bleeding
- Swollen neck nodes



The American Joint Committee on Cancer establishes a common language that is important for staging, treatment planning, and prognosis”.



TNM

- **Category**
Describes the three main anatomic components of staging
 - **T-level tumor extension**
 - Based on tumor diameter in cm (T1 tumor is 1cm)
 - T4 is defined by invasion of surrounding and number of anatomical structures involved (muscle, bone, nerve, veins, and/or arteries)
 - **N-level:** Refers to lymph nodal involvement
 - **M-level:** Refers to metastases



- TX Primary tumor cannot be assessed
- T0 No evidence of primary tumor
- Tis Carcinoma in situ
- T1 Tumor 2 cm or less in greatest dimension
- T2 Tumor > 2 cm but not more than 4 cm in greatest dimension
- T3 Tumor > 4 cm in greatest dimension
 - Moderately advanced local disease Lip - Tumor invades through cortical bone, inferior alveolar nerve, floor of mouth, or skin of face
 - Oral cavity - Tumor invades adjacent structures (eg, through cortical bone into deep extrinsic muscle of the tongue, maxillary sinus, or skin of face)
 - Very advanced local disease Tumor invades masticator space, pterygoid plates, or skull base and/or encases internal carotid artery



The best treatment is usually multi-modal. With a team approach, the patient benefits from the different skills and attributes of each member. The team may include:

- Head & neck surgeon
- Radiation Oncologist
- Medical oncologist
- Plastic surgeon
- Oral surgeon/prosthodontist
- Specialty nurse
- Speech pathologist
- Social worker
- Dietician
- **Certified lymphedema therapist**
- Other specialties as needed
- **Patient. *Most important member!***



Cancer Treatment

Surgical: Removal of the diseased tissues. Currently an emphasis on less invasive procedures and reconstruction has resulted in improved quality of life.

Radiation Therapy: Causes destruction of neoplastic disease at the primary site, plus microscopic extensions.

Chemotherapy: Done to control metastasis.

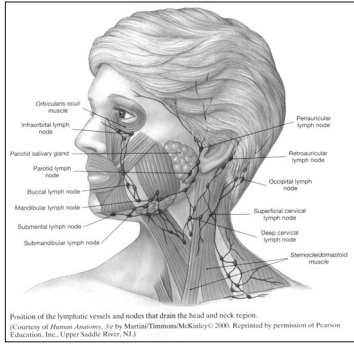
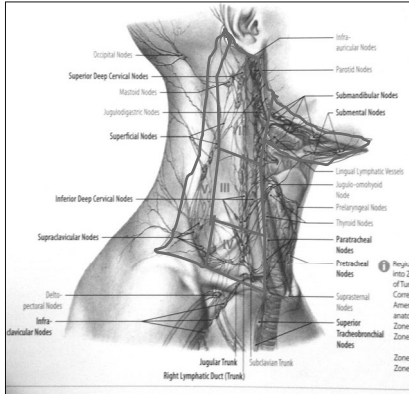


Surgical Treatment

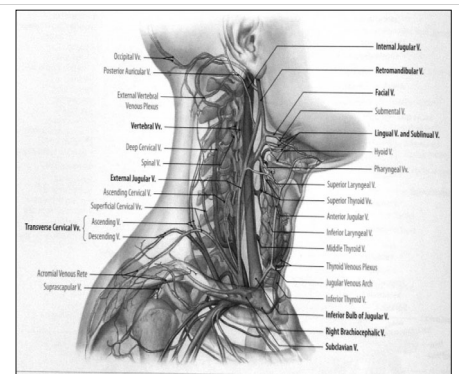
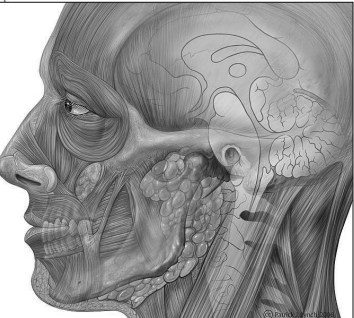
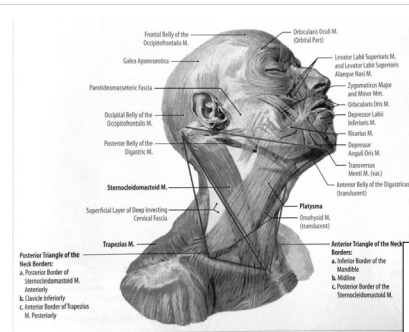
Ipsilateral standard radical neck dissection: Removal of superficial and deep fascia; I, II, III, IV, and V nodes centers; SCM and omohyoid muscles; submandibular salivary gland; the internal and external jugular veins; and the spinal accessory nerve

- Zone I**
Submandibular and submental nodes.
- Zone II and III**
Superior deep cervical nodes.
- Zone IV**
Inferior deep cervical nodes
- Zone V**
Superior nodes in the posterior triangle.





Ipsilateral standard radical neck dissection: Removal of superficial and deep fascia; I, II, III, IV, and V nodes centers; SCM and Omohyoid muscles; submandibular salivary gland; the internal and external jugular veins; and the spinal accessory nerve



Ipsilateral standard radical neck dissection Removal of superficial and deep fascia; I, II, III, IV, and V nodes centers; SCM and Omohyoid muscles; submandibular salivary gland; the internal and external jugular veins; and the spinal accessory nerve

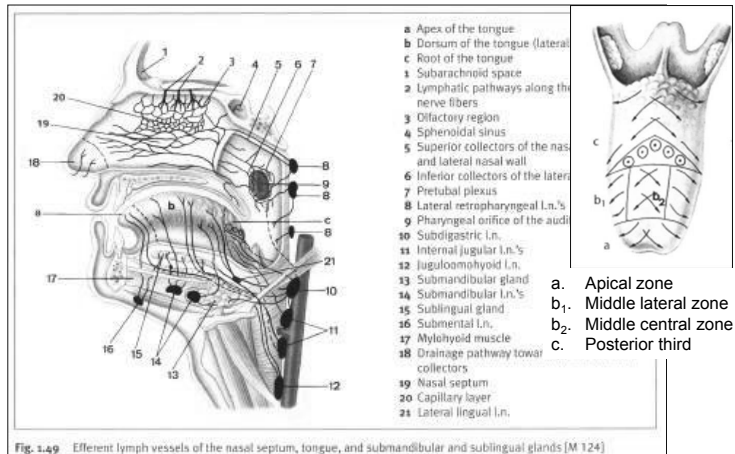
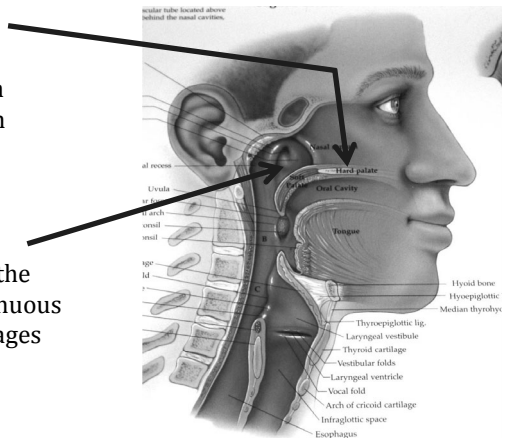


Fig. 1.49 Effluent lymph vessels of the nasal septum, tongue, and submandibular and sublingual glands [M 124]

Lips
Buccal mucosa
Floor of mouth
Oral tongue
Hard palate

Upper part of the pharynx continuous w/ nasal passages

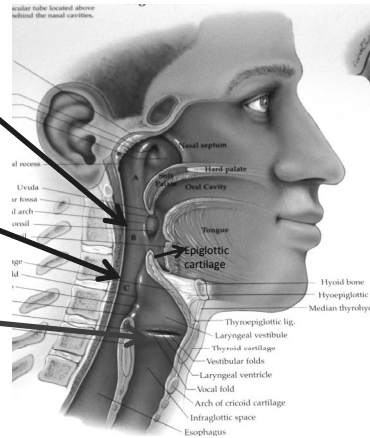


Published by Anatomical Chart Company Skokie, Illinois.

Soft palate
Tonsil
Tongue base
Pharyngeal wall

Ends at the
esophagus

Supraglottis
Glottis
Subglottis



Published by Anatomical Chart Company
Skokie, Illinois.



Nasopharynx
Palais dur
Palais mou
Luette
Oropharynx
Épiglotte
Laryngopharynx
Larynx
Sphincter œsophagien supérieur
Œsophage

Boil alimentaire
Langue

a) Position des structures avant la déglutition

b) Durant l'étape pharyngienne de la déglutition



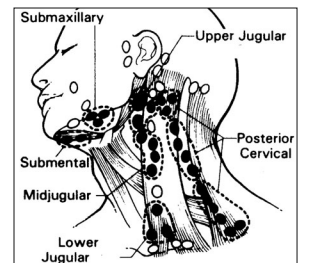
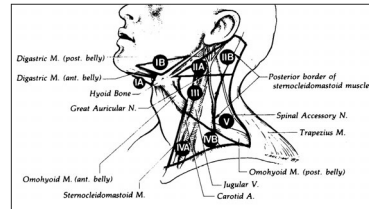
Changes in the anatomy or physiology at any area of the swallowing mechanism have significant consequences in the ability to swallow normally.

- Abnormalities of the oral cavity and/or the pharynx may lead to oropharyngeal dysphagia.
- Abnormalities of the esophagus may lead to esophageal dysphagia.



Surgical Treatment

- CNS edema is due to ligation of lymphatic and venous systems
- Facial edema



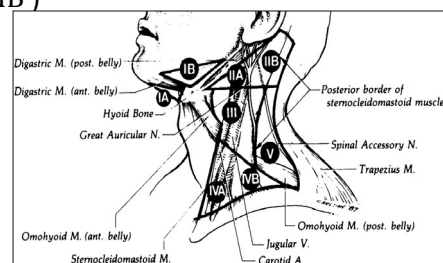
H&N Ca Surgical Treatment

- **Modified radical neck dissection**
 - Sparing of spinal accessory nerve
- **Modified neck dissection**
 - Sparing of internal and external jugular veins
- **Functional neck dissection**
 - Type I - Sparing of SAN
 - Type II - Sparing of IJV and SAN
 - Type III - Sparing of SCM muscle, IJV and SAN



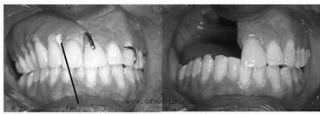Surgical Treatment

- **Selective neck dissection**
 - Submental triangle dissection (removal of IA)
 - Submandibular triangle dissection (removal of IB)



Surgery

- Surgical reconstruction is done to improve quality of life
 - A variety of reconstruction options, including free flaps and autogenous (fibular) bone flaps, are available to restore mandibular defects.
- An obturator prosthesis can be used to remedy palatal defects. Surgery



Obturator after maxillectomy



Surgical Effects

Scar adhesions

Hyper-sensitive scars

Nerve damage

- SAN - shoulder dysfunction
- Great auricular nerve
- Facial nerves

Swelling

Loss of fascia, deep and superficial

Loss of muscle, usually at anterior neck, sometimes posterior neck

- SCM
- Omohyoid
- Tongue
- Donor site (forearm)

Trismus / TMJ

Pain

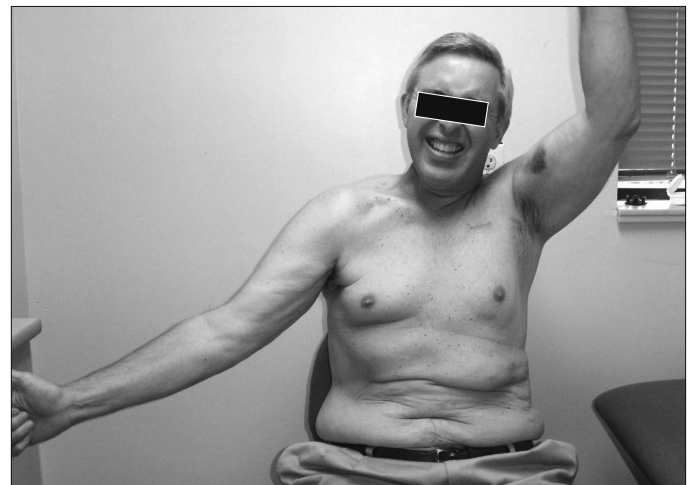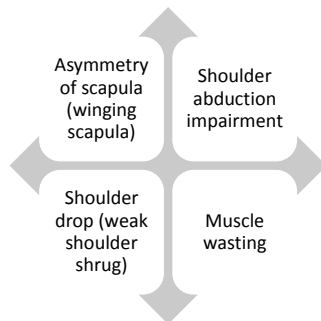
Disuse



Surgery Effect:

Spinal Accessory Nerve Palsy

- Can be permanent or temporary
- Palsy or weakness of trapezium (6 mo. or more)
- Great impact on shoulder dynamics



Facial Nerve Damage

- Loss of facial expression
- Loss of eye lid function
- Loss of movement at the corner of the mouth
- Loss of ability to firmly close the mouth



Radiation Treatment

Definitive (cure):

- Ca. in situ of larynx T1, Ca. of oral cavity, lips, T1 of nasopharynx

Post-surgical (to prevent recurrence)

- T3 and worse
- Positive margins
- Nodes metastasis

Pre-surgical to diminish tumor size to decrease pain



Types of Radiation

- External beam, fractionated radiation therapy. Can be done with conventional fractionation or accelerated fractionation
- Intensity modulated radiation therapy (IMRT)- delivers a high dose of radiation directly to the tumor, sparing or minimizing the impact to surrounding tissues.
- Stereotactic radiosurgery (SRS) is a highly precise form of radiation therapy. Initially developed to treat small brain tumors and functional abnormalities of the brain.
- Brachy therapy
 - Radiation seeds
 - Pod




Chemotherapy and Radiation

Concurrent chemotherapy and radiation therapy has made possible better organ preservation for advanced head & neck SCC, Stages 3 & 4.



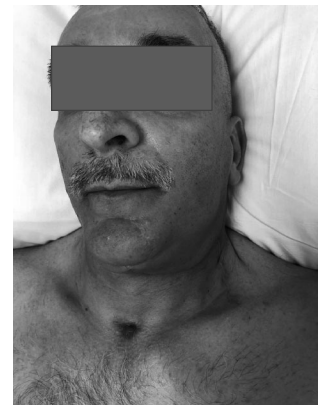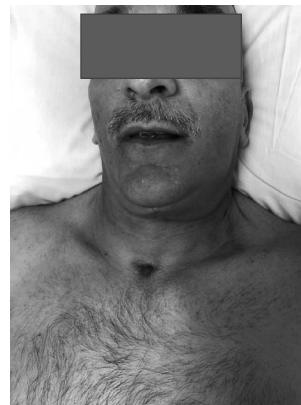Radiation Therapy



- Very important to have total patient immobilization and treatment set-up reproducibility
- Patients are immobilized with the use of custom made mask and frame
- Set up using a laser light to assure the proper position



Patient during Radiation



Effects of Radiation Treatment

Radiation therapy complications are dose-related and range from mild to debilitating.

Temporary

- Mucositis
- Xerostomia
- Alteration of taste
- Trismus/ TMJ
- Skin changes
- Epilation
- Hypo-alimentation
- Infection

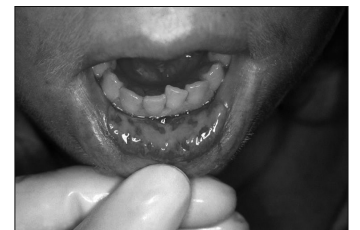Permanent

- Xerostomia
- Bad taste/ Dysgeusia
- Increased dental cavity rate
- Osteonecrosis
- Poor healing
- Fibrosis
- Stenosis of esophagus, stoma, larynx.
- Fistula, strictures



Mucositis

- Erythema (redness) with small white/yellowish patches
- Inflammation
- Ulceration
- Infection is a complication (fungal)
- Appears within 2 weeks of RT
- Dissipates 3–6 weeks after RT
- May be helped by: Magic Swizel and Biotene; mixture of Lidocaine 2% and antacid (numbs the mucosa); chlorhexidine/salt water/chamomile tea – for swish and gargle.



Xerostomia- dry mouth

Saliva is produced by **parotid glands** (oily), **salivary glands** (watery), and **sublingual glands**.

- The rapidly proliferating cells of these sites are extremely vulnerable to radiation damage which can reduce their output by as much as 90%.
- The pH of the remaining saliva is often altered and its viscosity increases.
- Some patients regain normal salivary cell function within 12 to 18 months after radiation therapy is discontinued
- But some patients may never recover pre-radiation salivary flow levels.

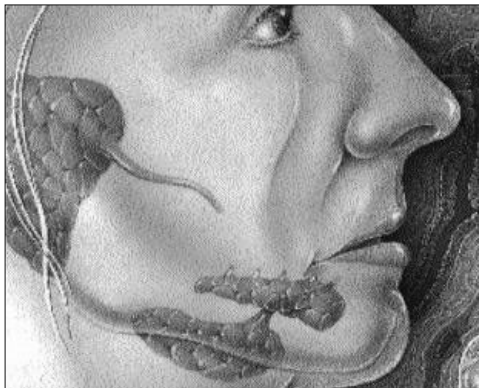


Xerostomia

- Quantity and quality of saliva are altered
 - Saliva is thick, ropy, sticky
 - Causes difficulty swallowing
- Decreases control of oral microbial growth
 - Causes cavities, periodontal disease, oral infections

Can be helped by:

- Acupuncture
- Frequent water sipping
- Room humidifier
- Salagen tablets @
- **Parotid gland transfer** - Dr. Seikaly & Dr. Jha at Cross Cancer Institute in Alberta, Canada

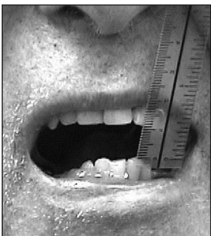

Alteration of Taste

- Appears within 1 week into RT
- Loss of appetite which causes poor nutrition and loss of weight
- Taste is recovered in 4 months s/p RT



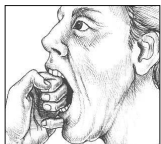Trismus



Limited aperture of the mouth / lock jaw

Present in almost 80% of the patients that have neck dissection and radiation.

- Caused by scarring, fibrosis, and disuse
- Causes pain and difficulties with eating, opening the mouth to take food, chewing
- Requires proactive intervention
- After it has developed, longer treatment is needed



Normal aperture



Skin Changes

- Erythema
- Pigmentation
- Peeling
- Dryness, itching
- Tightness
- Radiation burn, moist
- Epilation - loss of hair/ beard 3 weeks into RT
- Sweat and sebaceous glands cease to function

Dissipates gradually 2–3 weeks after RT.



Hypo-Alimentation

- About 50% of patients with head and neck cancer who have concurrent chemo and radiation experience severe dysphagia and mucositis
 - The proximity of this cancer to the oral and esophageal mucosa results in increase toxicity in these areas.
 - The combination of mucositis, xerostomia, trismus, loss of taste, and difficulty swallowing causes poor nutrition.
- Many medical center perform a percutaneous endoscopic gastrostomy; a PEG tube is placed prior to therapy to provide nutrition during the period of toxicity. Case by case basis



Effects of Radiation Treatment

Radiation therapy complications are dose-related and range from mild to debilitating.

Temporary

- Mucositis
- Xerostomia
- Alteration of taste
- Trismus/ TMJ
- Skin changes
- Epilation
- Hypo-alimentation
- Infection

Permanent

- Xerostomia
- Bad taste/ Dysgeusia
- Increased dental cavity rate
- Osteonecrosis
- Poor healing
- Fibrosis
- Stenosis of esophagus, stoma, larynx.
- Fistula, strictures



Why the Swelling/ Lymphedema?

Surgery

- Removal of lymph nodes
- Removal and cutting of lymph vessels
- Scar formation and adhesions

Radiation Therapy

- Decreases the number and size of the lymph vessels
- Causes fibrosis or hardening of the tissues which results in a lack of elasticity
- Causes adhesions not allowing anastomoses

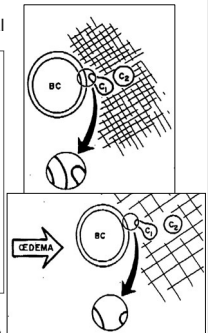


Stagnated fluid will result in:

- Poor oxygenation and nutrition of cells
- Reduced tissue macrophage activity
- Hardening of tissues due to excess protein

Stagnated proteins cause a low-level inflammatory process which leads to an overgrowth of interstitial connective tissue/fibrosis.

Normal



Abnormal



Pain

- Due to surgery and radiation
- Due to disuse
- Nerve pain and referred pain

In follow-up studies for quality of life after head and neck cancer treatment, shoulder pain and dysfunction and dry mouth were the most common complaints.



Patient Presentation

- Cosmetic disfigurement
- Edema of face and neck
- Pain and limited range for neck, face, and shoulder motions
 - Will turn whole body, not the head
 - Lack of facial expression
 - Pain and limited opening of the mouth
 - Shoulder function impairment



Patient Presentation

- Difficulties managing dry mouth and ropy saliva
- Pain due to mouth lesions
- Hypersensitive scars (also at the donor site)
- Nerve pain and referred pain
- Not able to eat by mouth (difficulties with chewing and swallowing)
 - In danger of aspirating
 - Not able to cough
- Communication problems




Patient Presentation

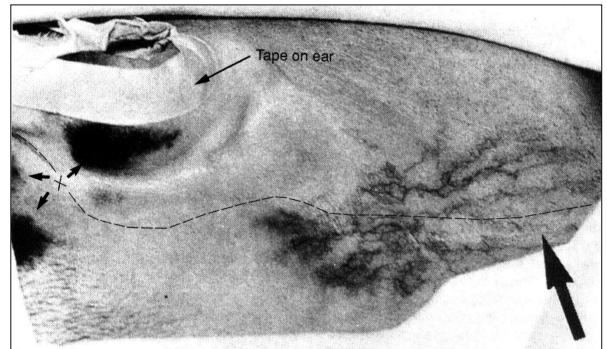
Weight loss and loss of lean-body mass despite no change in their caloric intake.

- Physical and functional decline
- Elevated cytokines (systemic inflammatory response)

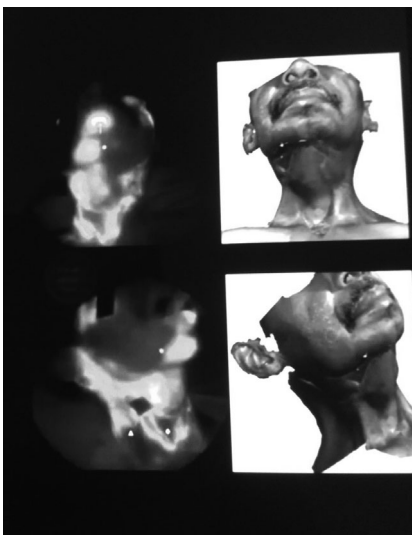
Heidi Silver, PhD
Mary S Dietrich, PhD
Barbara Murphy, MD



Retroauricular injection of Patent Blue dye 3 years after a bilateral neck dissection. The dye is picked up by the dermal lymphatics and carried towards the submandibular area. The dermal lymphatic vessels have re-grown across the scar.



Fisch U Lymphography of the cervical lymphatic system. Philadelphia, WB Saunders, 1968:47-146



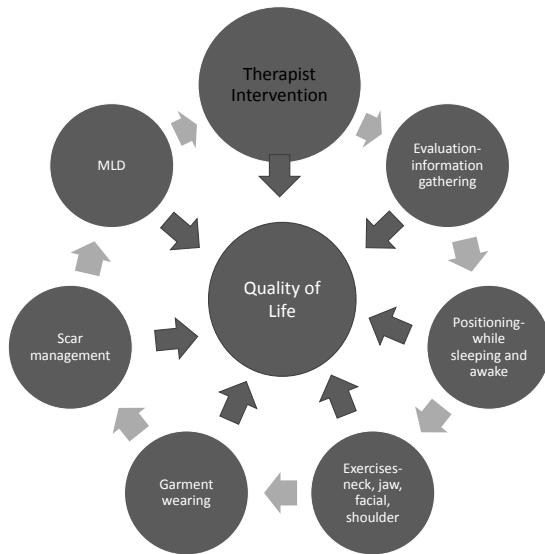
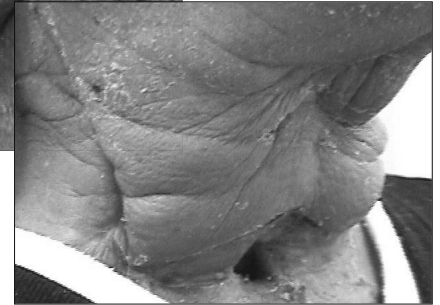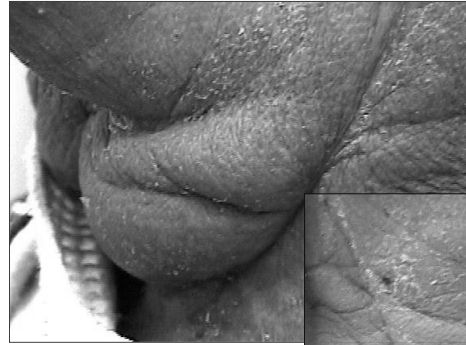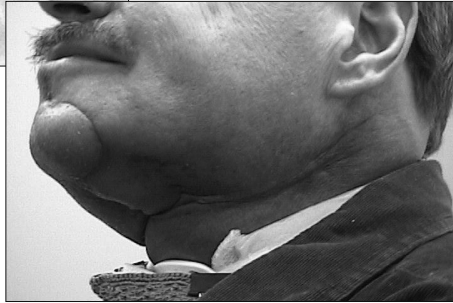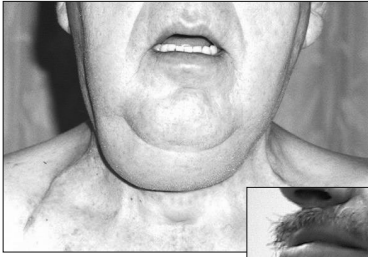
NIRF
Indocyanine green
Fluoroscopy



Fisch at the University of Zurich demonstrated:

- Subcutaneous diversion of flow anteriorly towards the submandibular area (bag of fluid called a wattle)
- Diversion of the lymph flow to the contralateral side through the submental area
- Re-growth of dermal lymphatic vessels across the scar
- No obvious diversion to the posterior neck





Evaluation

- Posture
- Color and temperature
- Sensation changes
- Hardening of the tissues; texture and tension
- Scar adhesions and their effect on movement and lymph flow



Shoulder Evaluation

- Muscle wasting
- Goniometry of active and passive ROM for all shoulder motions, especially abduction
- Strength test for shoulder motions
- Check for trigger points and referred pain
- Functional test



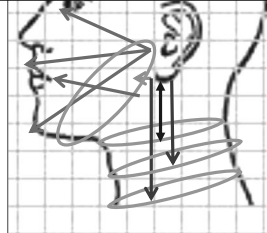
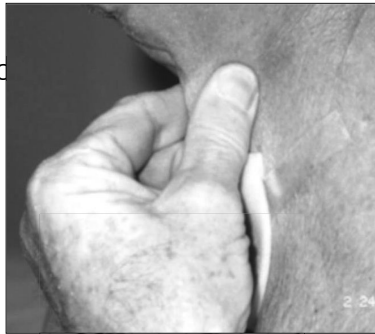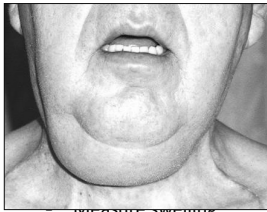
Subjective Evaluation

- Pain/discomfort
 - What does it feel like?
 - What makes it better? What makes it worse?
- Emotional response to the condition
 - Listen to subjective descriptions and complaints.
 - Listen to what is important to the person and the family.

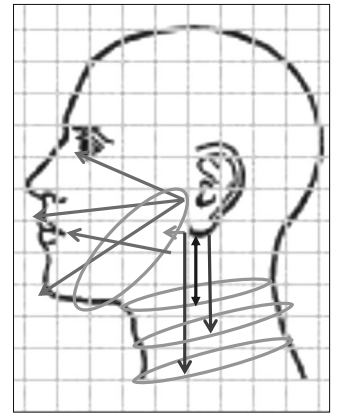
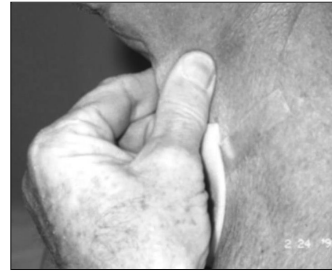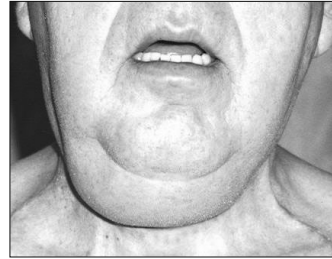


Evaluation

- Minimal
- Mild
- Moderate
- Severe



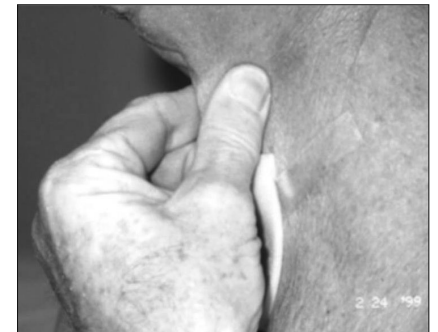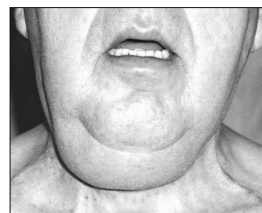
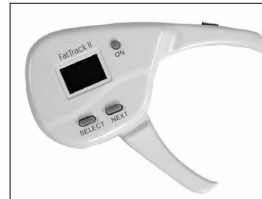- Measure swelling (in cm)
 - Neck
 - Submental
 - Facial, cheek



Evaluate Type of Swelling

- **Stage I** Dissipate during the day, worse at night
- **Stage II-** Does not dissipate during the day
 - Can present with pitted with some hard areas
- **Stage III-** Usually is mixed swelling
 - some pitted areas and mostly hard swelling

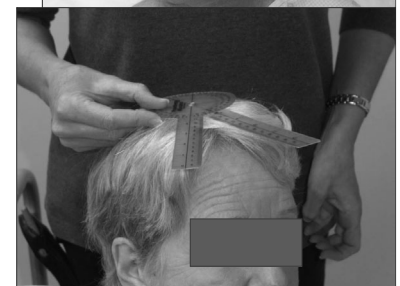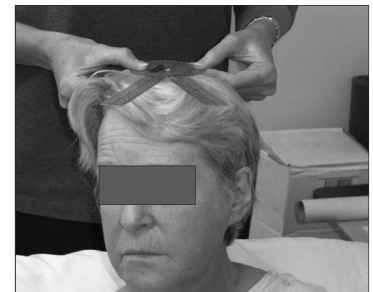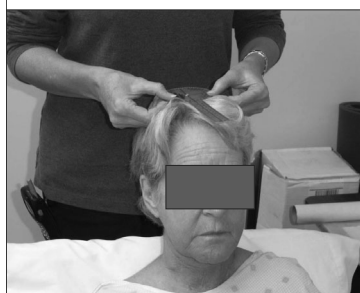- **Type of swelling:**
 - Pitted-
 - Soft
 - Hard
 - Mixed



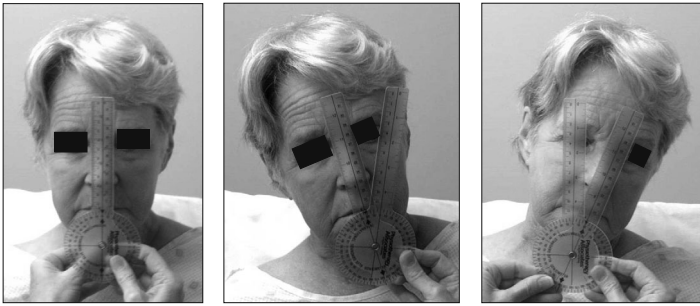Measuring Fibrosis

- Is subjective, using the caliper or the pinch test
 - Measured in mm. of tissue pinched
- Can be subjectively classified as;
 - Minimal
 - Mild
 - Moderate
 - Severe
 - Sometimes when fibrosis is severe it can not be pinched (woody neck)

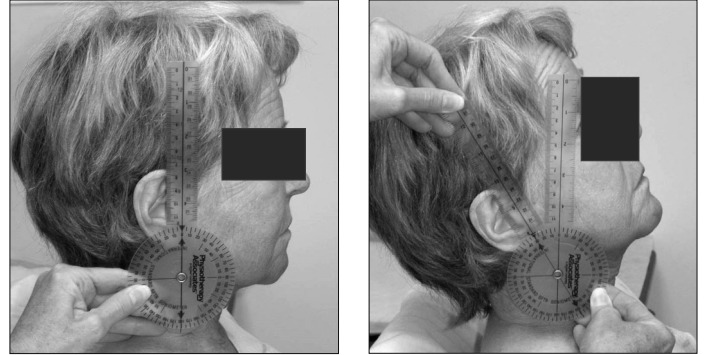
NECK ROTATION



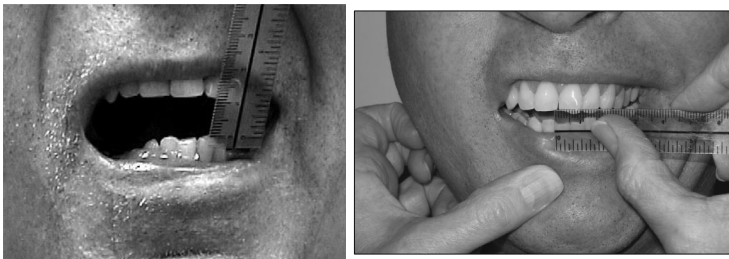LATERAL FLEXION



EXTENSION



ASSESSING FOR TRISMUS

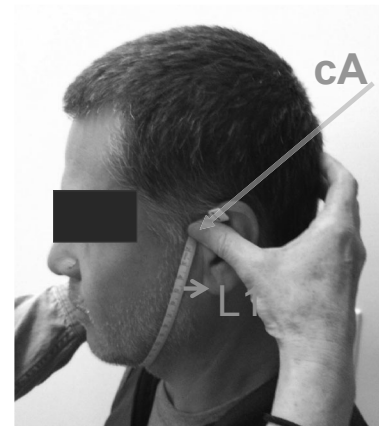


Measure the mouth aperture (in mm) from the top of the lower teeth (or gum if teeth are not present) to the top of the upper teeth (or gum).

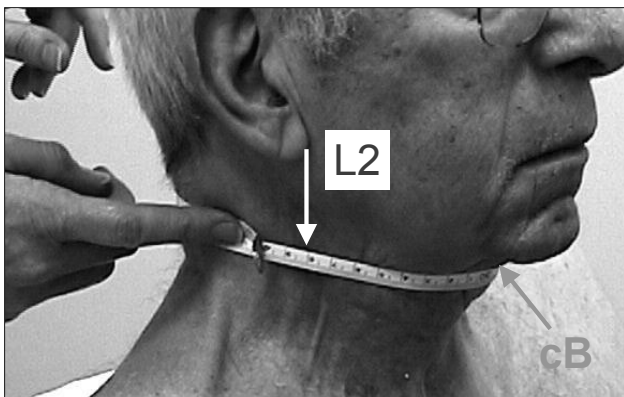
Jaw translation, side to side



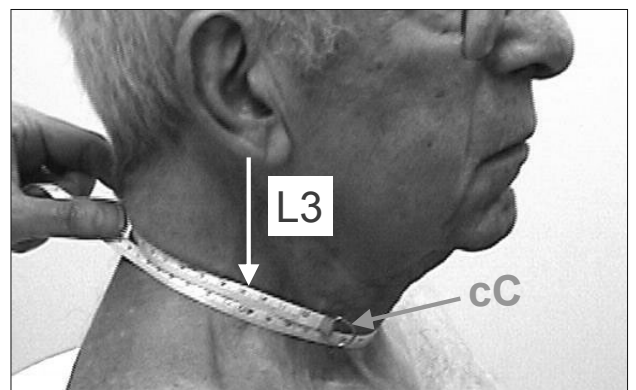
Chin-to-Tragus Circumferential



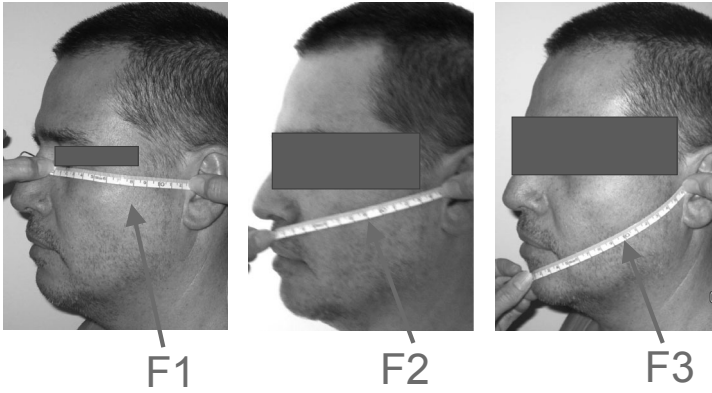
UPPER-NECK CIRCUMFERENTIAL



LOWER-NECK CIRCUMFERENTIAL



FACIAL SWELLING



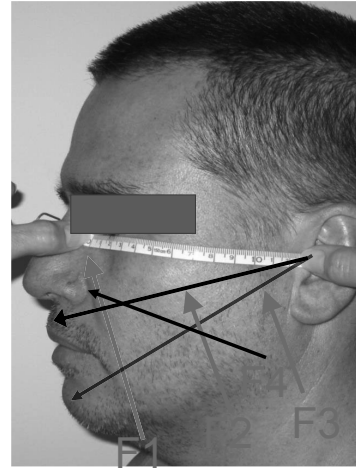
F1

F2

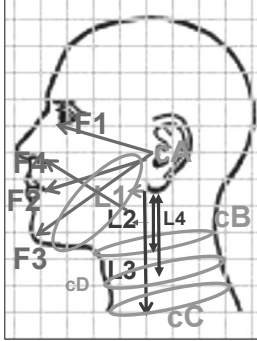
F3



FACIAL SWELLING



SWELLING ASSESSMENT		Date:	
Tragus to tragus at the waddle		cA	
SIDE		R	L
Distance Ear lobe to tape for tragus to tragus L1	L1	L1	
Circumference: Upper neck : cB	cB		
Circumference: Lower neck: cC	cC		
Circumference: Mid neck: : cD	cD		
SIDE		R	L
Distance: Earlobe to upper neck L2	L2	L2	
Distance: Earlobe to lower neck L3	L3	L3	
Distance: optional Earlobe to mid neck L4	L4	L4	



NECK ROM		Date:	
Neck flexion/extension		/	
SIDE		R	L
Neck lateral flexion			
Neck rotation			

SHOULDER ROM		Date:	
SIDE		R	L
Flexion	/10		
Abduction	/10		
Internal rotation/external rotation	/ /	/10	/10

FACIAL SWELLING		Date:	
TMJ, Tragus to inner eye corner F1	F1	Rt: Lt:	
TMJ, Tragus to corner of mouth F2	F2	Rt: Lt:	
TMJ, Tragus to mid chin F3	F3	Rt: Lt:	
Angle of the jaw to nostril F4	F4	Rt: Lt:	

FIBROSIS		Date:	
Fibrosis: Anterior upper neck			
Fibrosis: Mid anterior neck			
Fibrosis: Lower anterior neck			
SIDE		R	
Fibrosis: Side of neck			

TRISMUS		Date:	
Mouth Aperture:		Translation to Rt:	
		Translation to Lt:	

Evaluation

Add the circumference measurements.

- cA
- cB
- cC
- cD (mid neck if needed)
- cE

Subtotal=

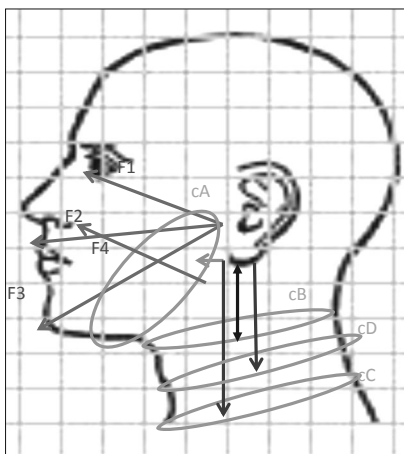
Add facial measurements.

- F1 right and left
- F2 right and left
- F3 right and left
- F4 right and left

Subtotal=

Total= C+F (comparing measurements over time provides an indication of reduction in swelling)

NOTE: Next re-evaluation, repeat and compare the results of the total and the individual measurements .



Treatment

1. Proper positioning while sleeping and proper posture while awake
2. Exercises
3. Compression garment(s)
4. Scar management
5. Manual lymph drainage
6. Education on skin care and dental care
7. Prevention of frozen shoulder and protection of this joint during the muscle imbalance

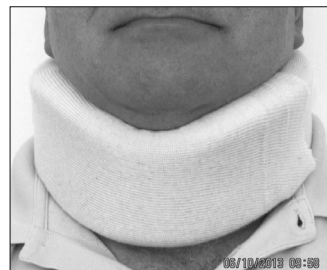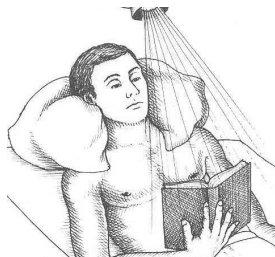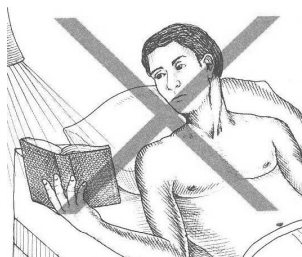
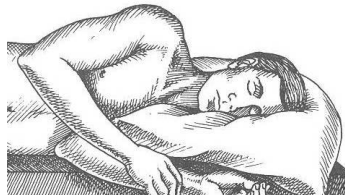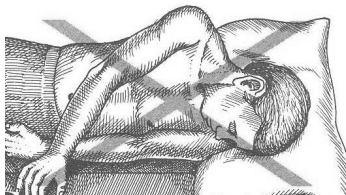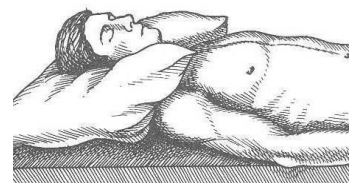
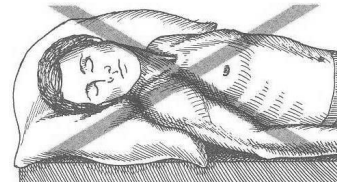


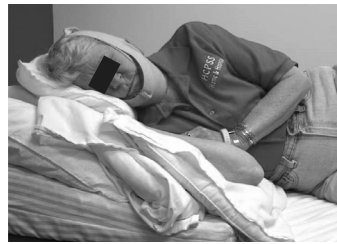Positioning and Posture

- Sleep in a reclined position (about 35°)-to promote lymph flow and venous return
- Support the head while sleeping
- Increase awareness of the head and neck position during the day, i.e. while reading, watching TV, napping.

“ The Position of Comfort is the Position of Contracture”

- Posture in general
 - Correct scapular retraction: strengthen rhomboid and serrator muscles



Treatment

1. Proper positioning while sleeping and proper posture while awake
2. Exercises
3. Compression garment(s)
4. Scar management
5. Manual lymph drainage
6. Education on skin care and dental care
7. Prevention of frozen shoulder and protection of this joint during the muscle imbalance



Take Home message

- Exercises have a significant effect with the head and Neck Lymphedema
- Contraction of muscles helps pump the fluids away from the swollen area.
- Improves tissue gliding which affects adhesions and promotes lymph anastomoses
 - Improves active motion of the neck, shoulder, face.
 - Improves function

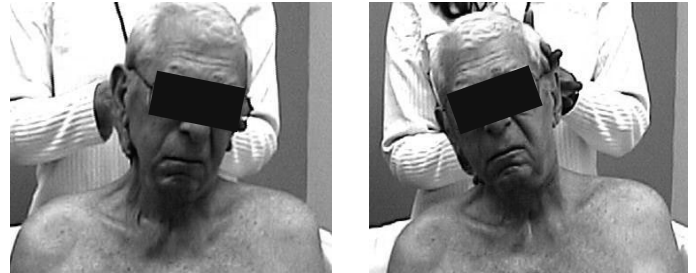


Treatment Exercises

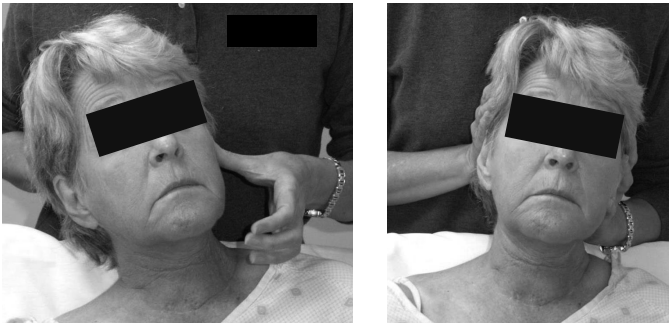- Neck ROM exercises: rotation, side flexion, flexion and extension.
- Facial exercises
- Jaw exercises
- Tongue exercises



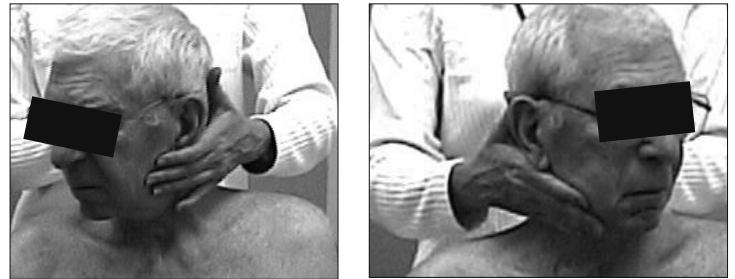
Neck Lateral Flexion



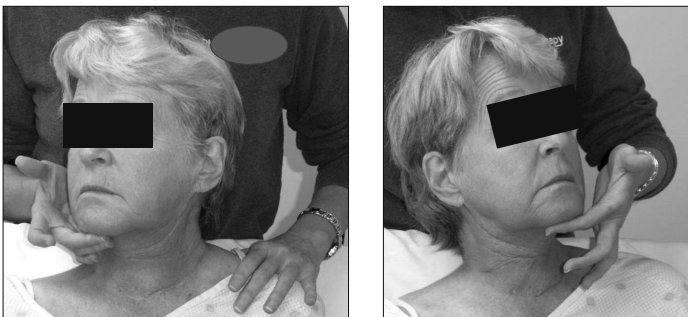Neck Lateral Flexion



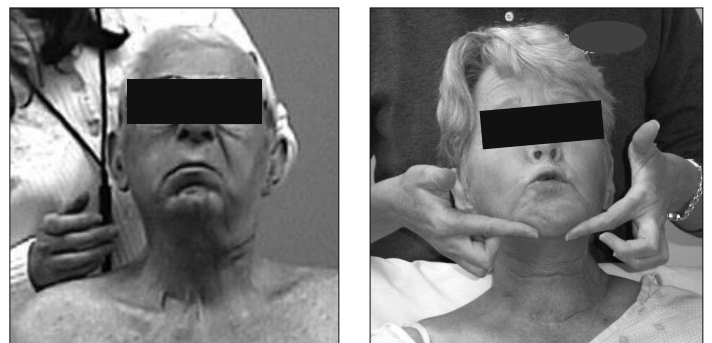Neck Rotation



Neck Rotation



Neck Extension



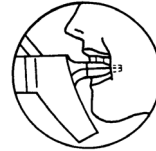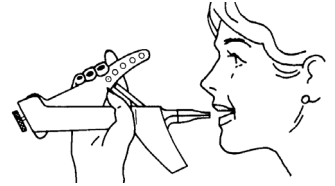
Facial Exercises

- To improve facial movements
- To improve mastication (chewing)
- To improve the ability to open the mouth



Treatment for Trismus

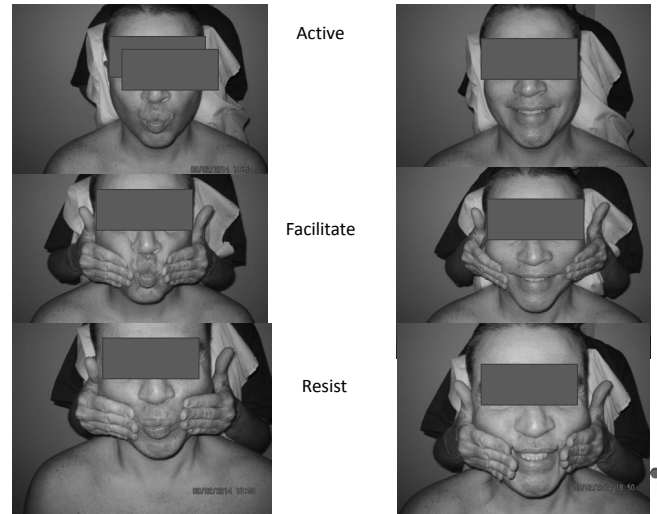
- Manual Therapy (myofascial techniques)
- Therapeutic exercises for jaw and neck
- Prolonged, low stretch performed frequently using devices such as the Therabite or Dynasplint



Therabite Jaw Motion Rehabilitation System



Muscle Testing: Techniques of Manual Examination. Lucille Daniels, M.A. and Catherine Worthingham, Ph.D.



Muscle Testing: Techniques of Manual Examination. Lucille Daniels, M.A. and Catherine Worthingham, Ph.D.



Muscle Testing: Techniques of Manual Examination. Lucille Daniels, M.A. and Catherine Worthingham, Ph.D.



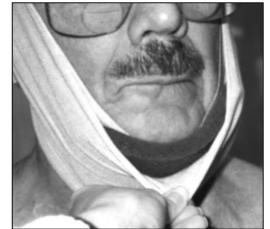
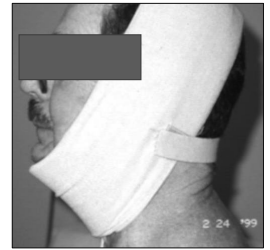Treatment

1. Proper positioning while sleeping and proper posture while awake
2. Exercises
3. **Compression garment(s)**
4. Scar management
5. Manual lymph drainage
6. Education on skin care and dental care
7. Prevention of frozen shoulder and protection of this joint during the muscle imbalance

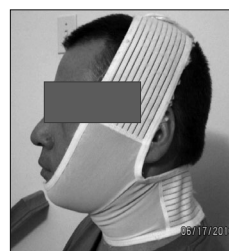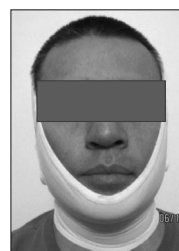

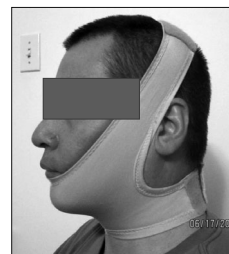
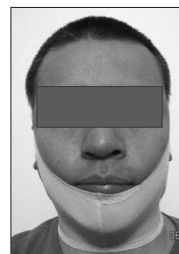
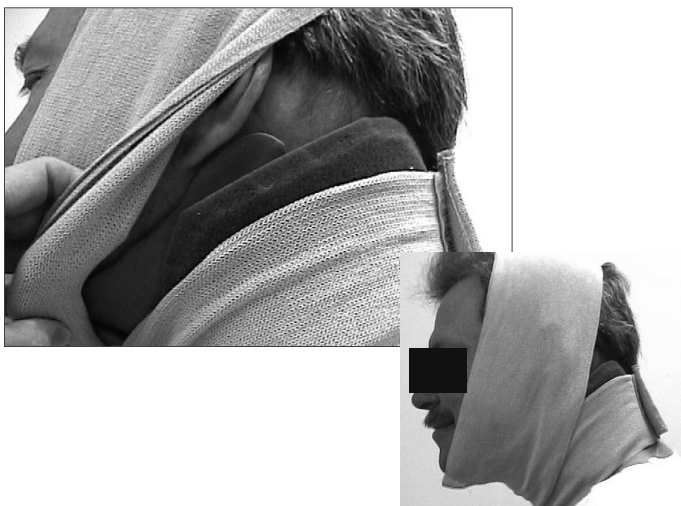
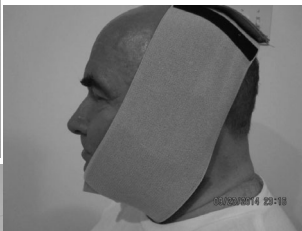Treatment

- Prevents the re-accumulation of fluid
- Helps break down the hard tissues
- Applies even compression because of the garment's low-elastic material
- **Garments worn at night and during the day before and after self MLD**

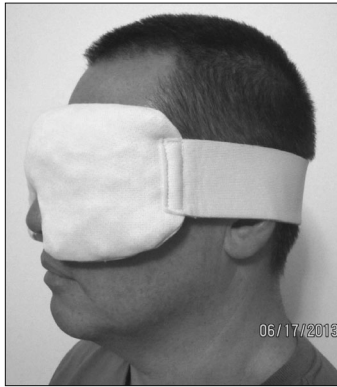
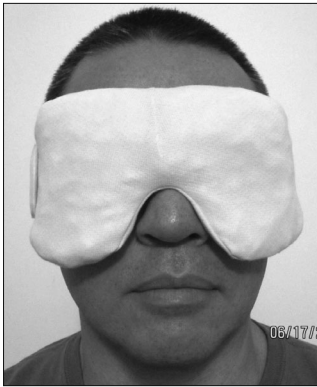
Garment Making


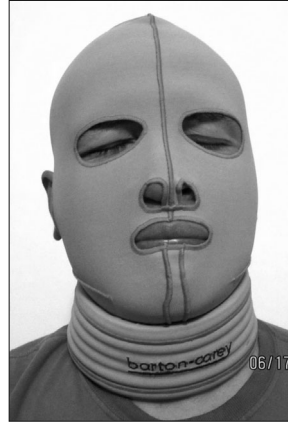


**Epstein
Facioplasty
Support by Jobst**

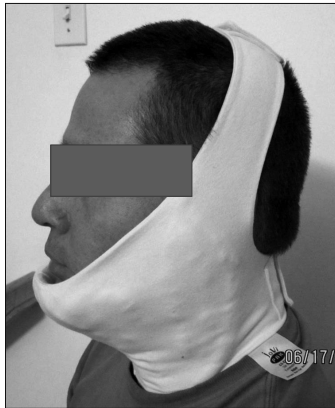
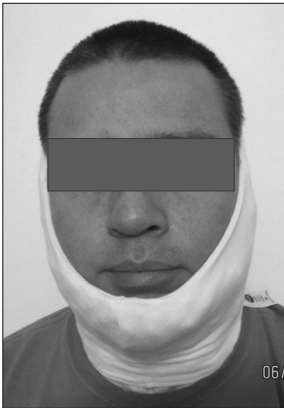


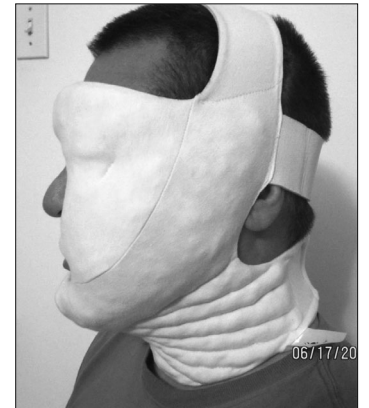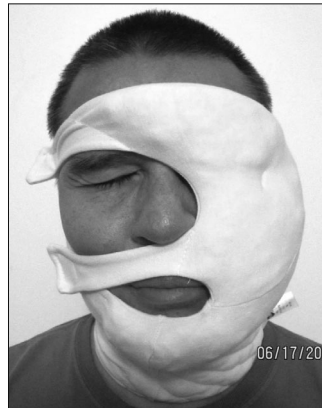Eye Compression Garment by JOVI



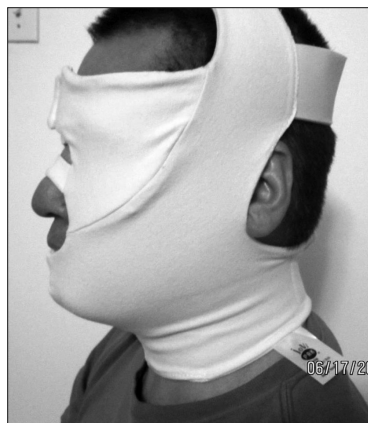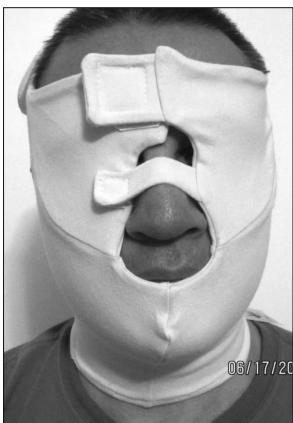
Face mask and neck collar custom made by Barton Carey



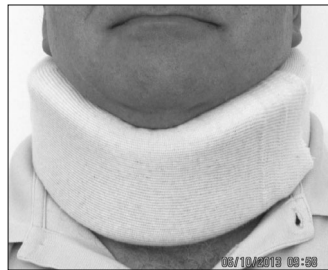Extended Chin Strap with Peri-Auricular Neck Pad by JoVi



Half Face and Neck Mask by JoViPak



Full Face and Neck Mask by JoViPak



Treatment

1. Proper positioning while sleeping and proper posture while awake
2. Exercises
3. Compression garment(s)
4. **Scar management**
5. Manual lymph drainage
6. Education on skin care and dental care
7. Prevention of frozen shoulder and protection of this joint during the muscle imbalance



Scar Management

- Historically we have been told that we need to avoid and go around scars.
- With this patient population we must treat the scar to improve the lymphatic flow
- **“ The Position of Comfort is the Position of Contracture”**



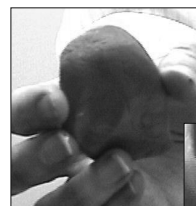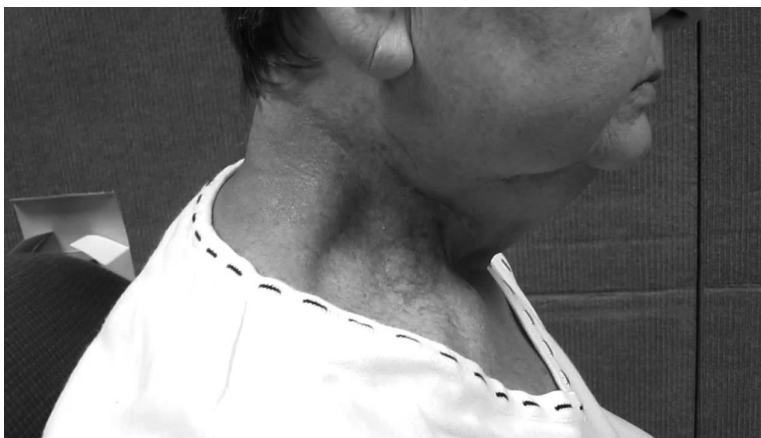Scar and Fibrosis Management

- Soft tissue mobilization / scar mobilization
- Compression
 - Compression garments
 - Use of foam pieces
 - Use of elastomer molds under the garment
 - Use of foam chips pillows
 - Use of silicone strips

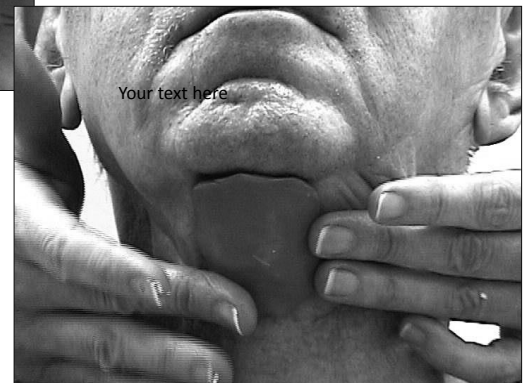


Scar Massage

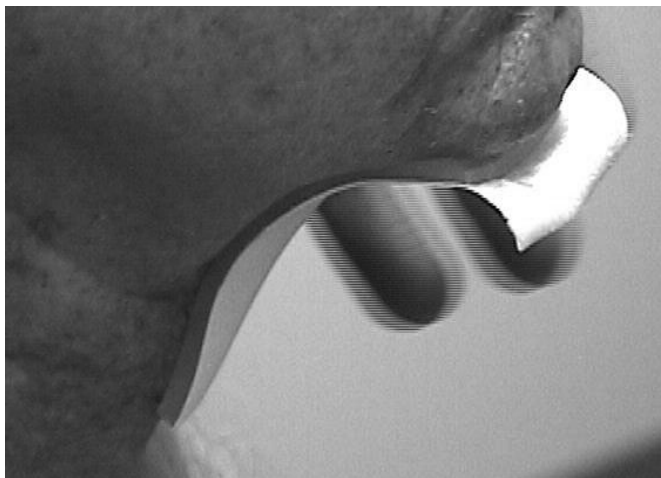
- Evaluate the integrity of the scarred and radiated tissues every visit
- Also evaluate how the tissues are responding to the scar and fibrosis massage as you are performing it
- This tissue is very fragile and could tear easily
- Start always very gently and observe
- Do not rely on pain or discomfort from the patient, because sensation may not be normal



Elastomer Mold



Silicone Sheets



Treatment

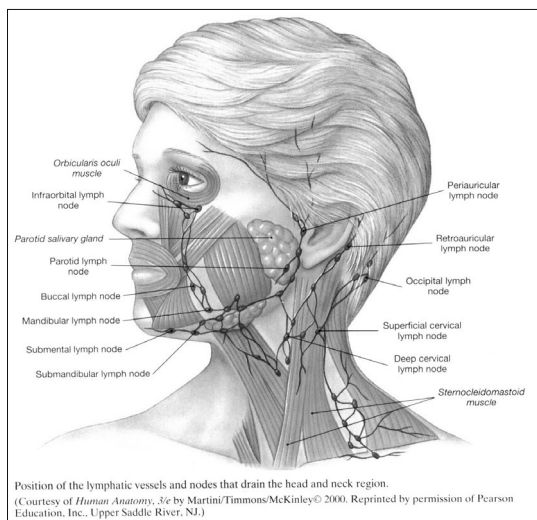
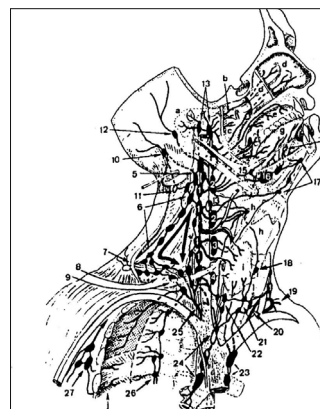
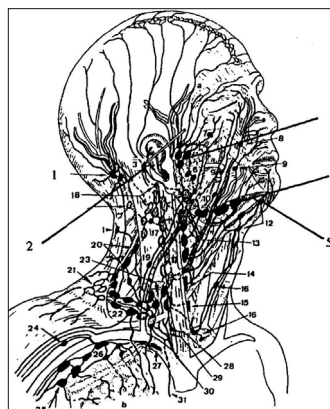
1. Proper positioning while sleeping and proper posture while awake
2. Exercises
3. Compression garment(s)
4. Scar management
5. **Manual lymph drainage**
6. Education on skin care and dental care
7. Prevention of frozen shoulder and protection of this joint during the muscle imbalance



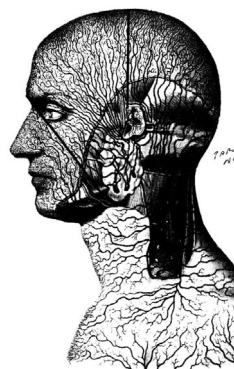Manual Lymph Drainage (MLD)

Skin and Intra-oral

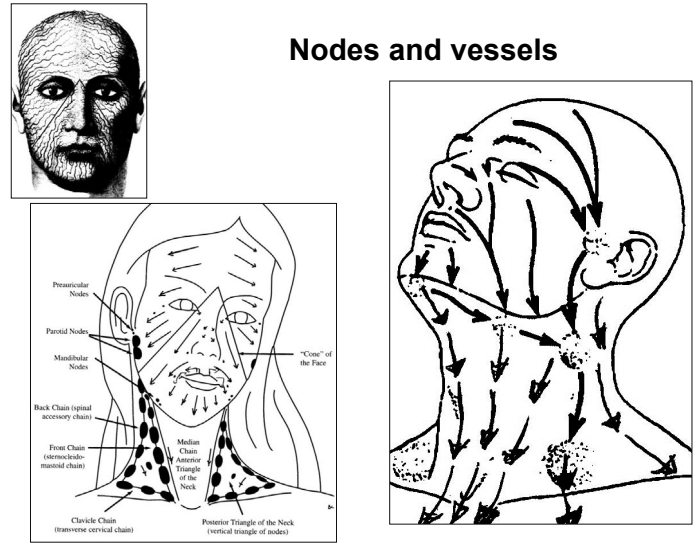
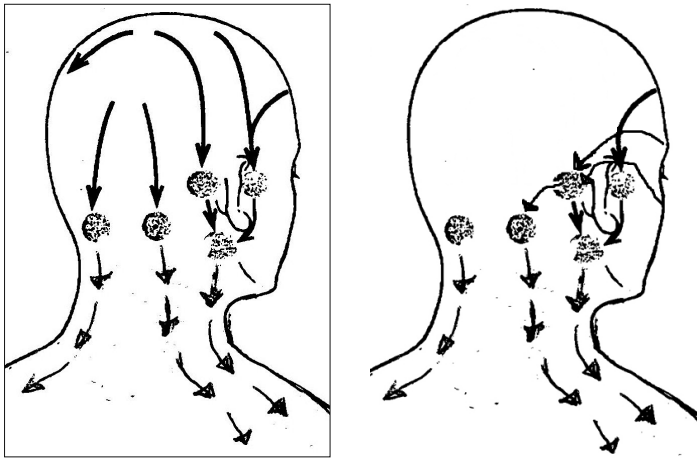
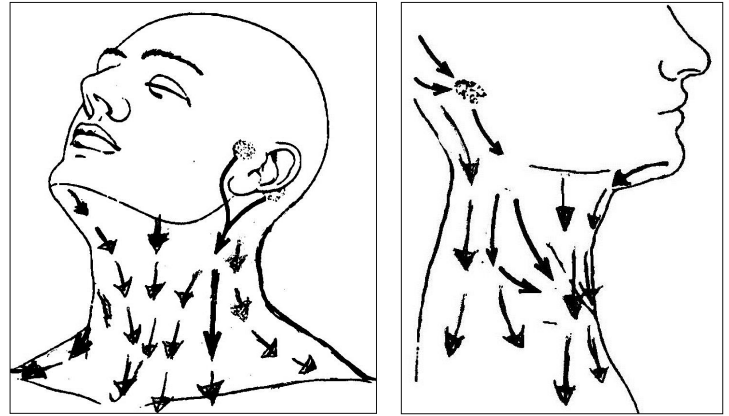
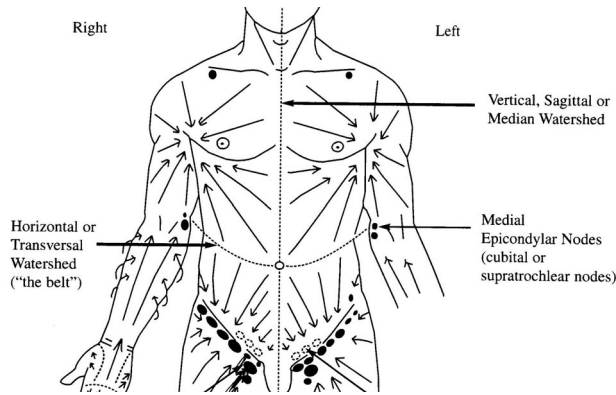
- Gentle, rhythmic stretching of the skin to stimulate the lymph capillaries and vessel contractibility
- Facilitates a directional flow of fluid towards healthy, functioning lymphatics
 - Utilizes subcutaneous lymph vessels
 - Utilizes lymphatic anastomoses and existing lymphovenous anastomoses
- Breaks down fibrosis



SUPERFICIAL LYMPH CIRCULATION FACE



Lymph Circulation Anterior Aspect



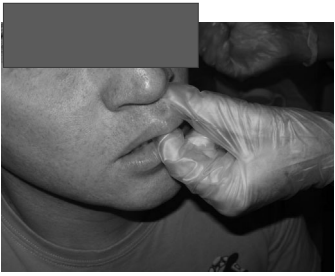Intra-oral Manual Lymph Drainage

- Indications- when swelling of lips, palate, tongue and inside cheeks.
- Contraindications-

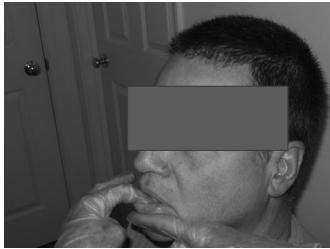Intra-oral Manual Lymph Drainage

- Upper lip
- Lower lip
- Palate soft and hard
- Floor of mouth
- Between gum and cheek
- Tongue under side (both sides, right and left)
- Cheeks, low, middle, upper

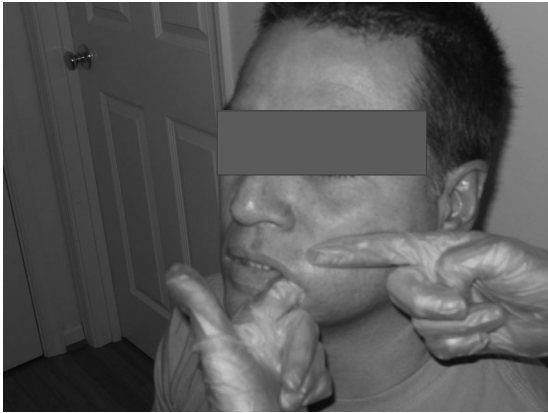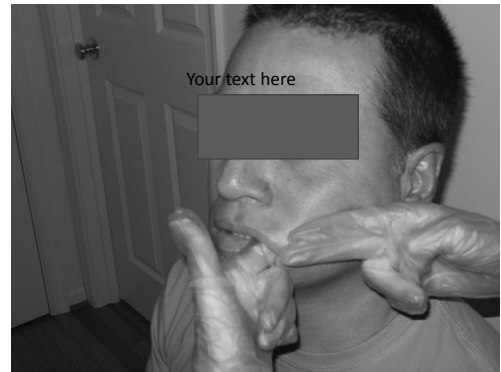Upper Lip



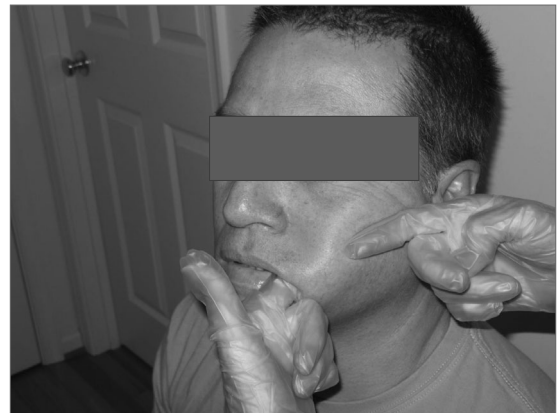Lower Lip



Lower Cheek



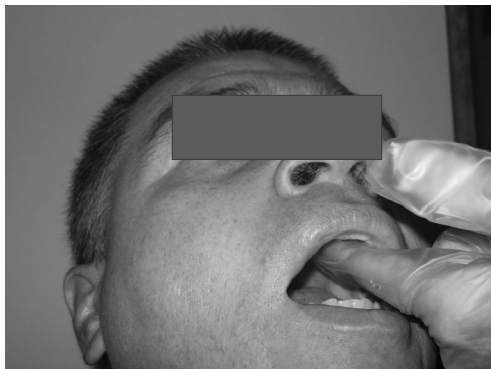Mid cheek



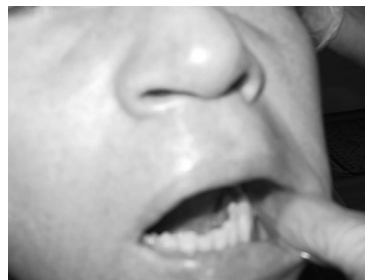
Upper cheek



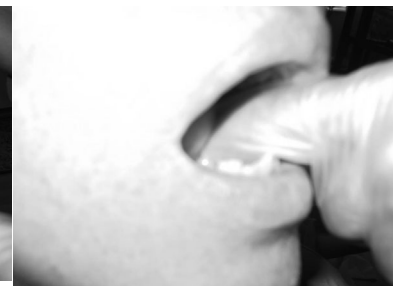Roof of Mouth, Hard and Soft Palate



Outer side of teeth gum line floor

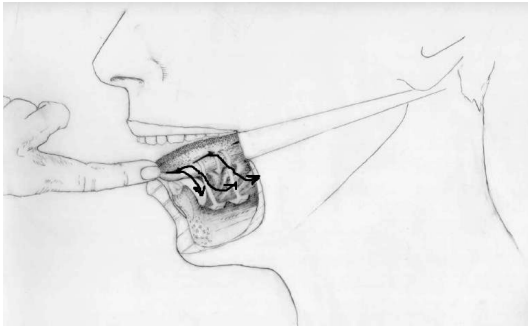


Inner side of teeth, gum line floor of mouth

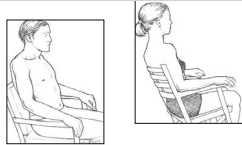
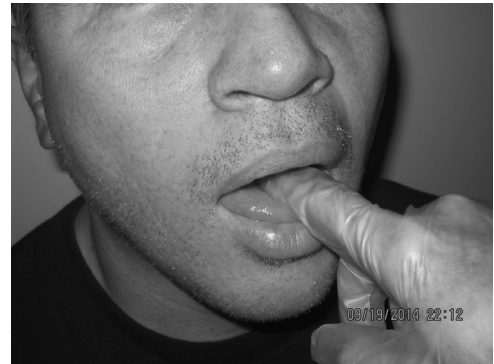

Tongue Sides

Start at the top edge of the side of the tongue, follow down the side to the base rolling your finger back and down to floor of mouth.



Apply pressure and stroke on top of tongue



- Protect the shoulder joint: Support the arm; prevent hanging the arm
- Maintain the integrity of the glenohumeral joint
 - Passive and/or active assistive ROM (pulley exercises)
 - Joint mobilization if joint capsule is tight
 - Soft-tissue mobilization
 - Contract/relax techniques
 - Strengthening of the other scapular muscles (rhomboid, serratus, levator scapulae)



Other treatments: Nerve Pain/Referred Pain

- Desensitization techniques
 - Manual Lymph Drainage
- Myofascial and trigger point release techniques



Myofascial Techniques

- This patient population benefits from myofascial release techniques
 - They usually have areas of tissue tension/tightness
 - Due to scarring from surgical procedure or radiation
- From maintaining guarded posture
 - Fear of the of pain
- Lack of normal movement, very sedentary life style
 - Disuse



Early Intervention

After surgery, begin intervention as soon as surgical wounds are healed to...

- Soften scars
- Prevent adhesions
- Dissipate swelling
- Promote lymph vessel re-growth
- Prevent disuse



Early Intervention

Intervention should continue during and after radiation therapy to...

- Prevent adhesions
- Soften scars
- Soften fibrosis
- Promote lymph vessel re-growth
- Prevent disuse



Benefits of Early Intervention

Better cosmetic appearance

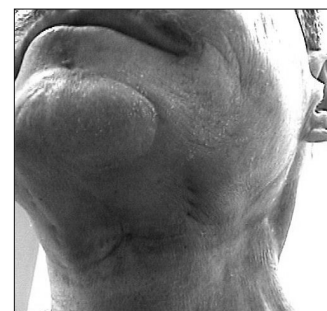
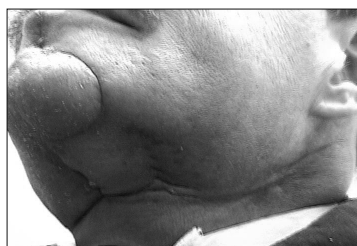
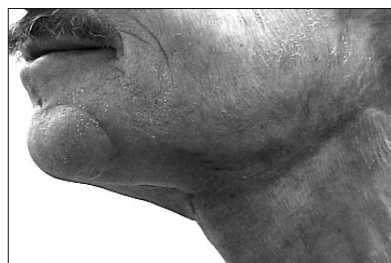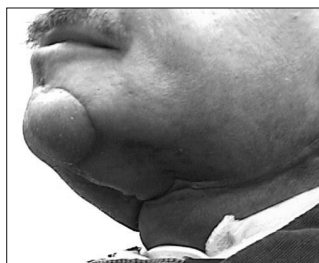
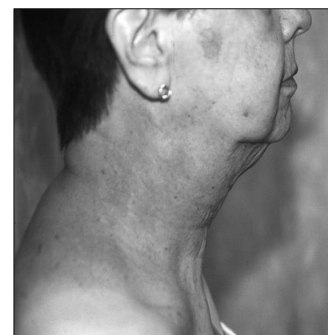
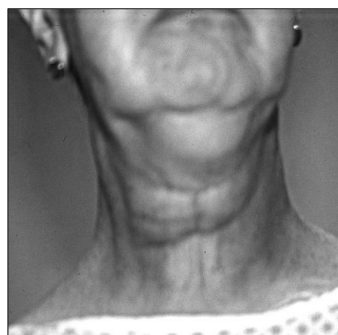
- Improved self-image
- Improved self-esteem

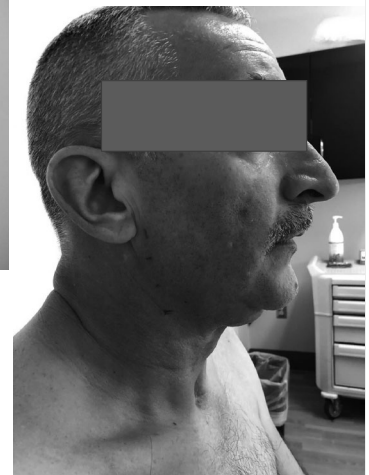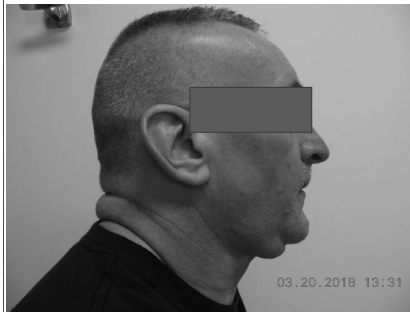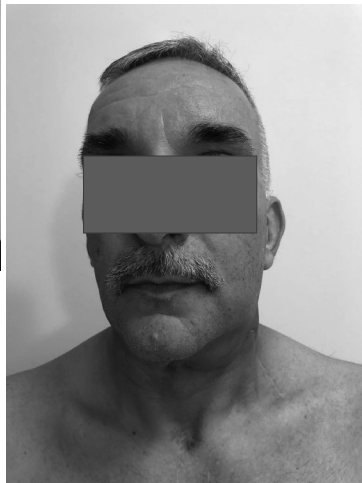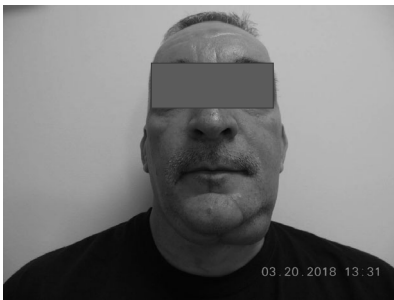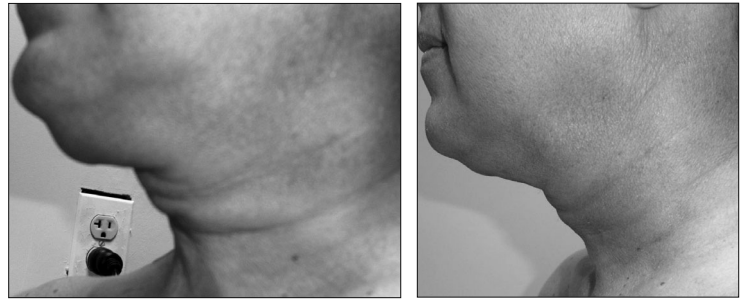
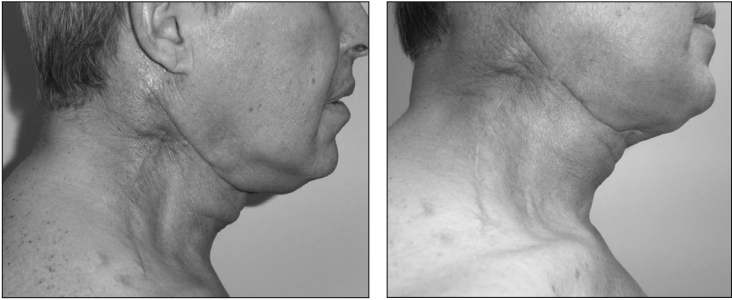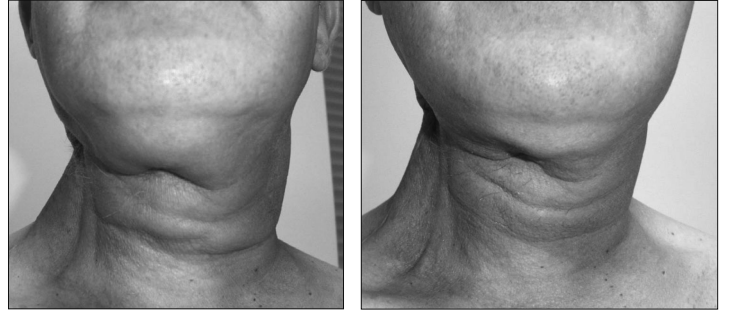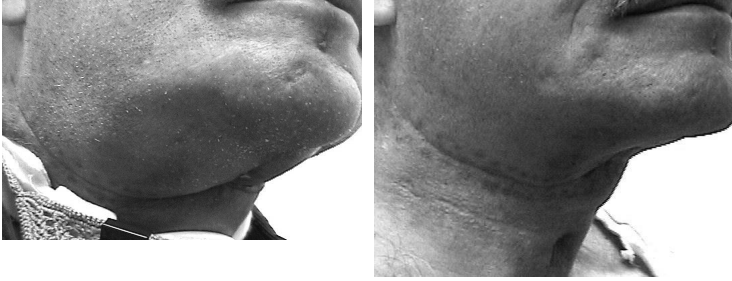Earlier improvement of function

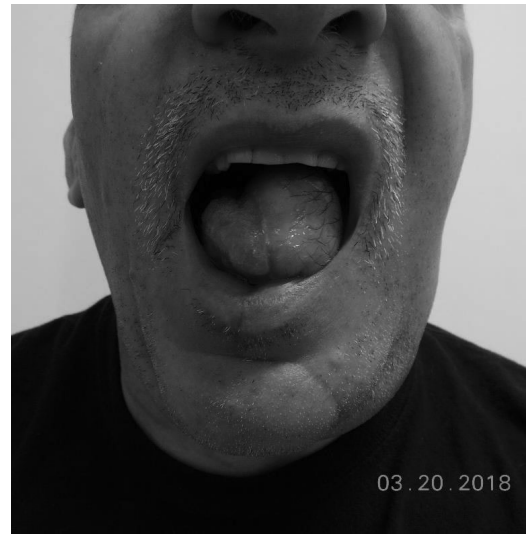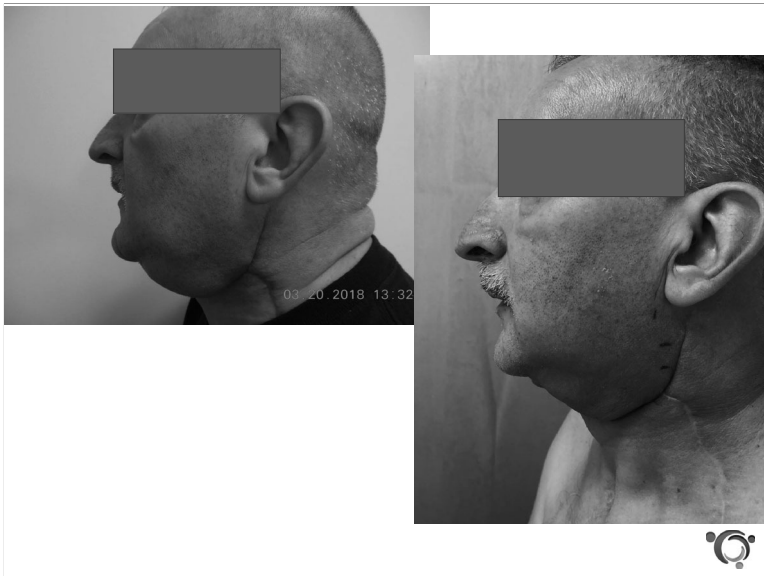- Movement of the neck, face, and mouth
- Indirectly affects swallowing by improving tissue glide and reducing swelling
- Protects the shoulder joint; prevents and reduces pain and improves shoulder function



Quality of Life Improvement”







“Quality of Life Improvement
is the Ultimate Goal”

References

- Donatelli R, ed. 1996. *Physical Therapy of the Shoulder*, 3rd edition. Churchill Livingstone, 499 pp.
- Million R, Cassisi N. 1984. *Management of Head and Neck Cancer: A Multidisciplinary Approach*. J. B. Lippincott Co. 649 pp. Philadelphia, PA, 1984
- Peters PM, Dichtel WJ. 1995. *The Source for Laryngectomy*. East Moline (Illinois): Lingui Systems, Inc. 175 pp.
- Piso DU, Eckardt A, Lieberman A, Gutenbrunner C, Schaffer P, Gehrke A. Early Rehabilitation of Head and Neck Edema after Curative Surgery for Orofacial Tumors. *American Journal of Physical Medicine and Rehabilitation*. 80(4): 261-9.
- Shapshay SM, Ossoff RH, eds. *Squamous Cell Cancer of the Head and Neck*. *Otolaryngology Clinics of North America* 18:367-624, 1985.

References (cont.)

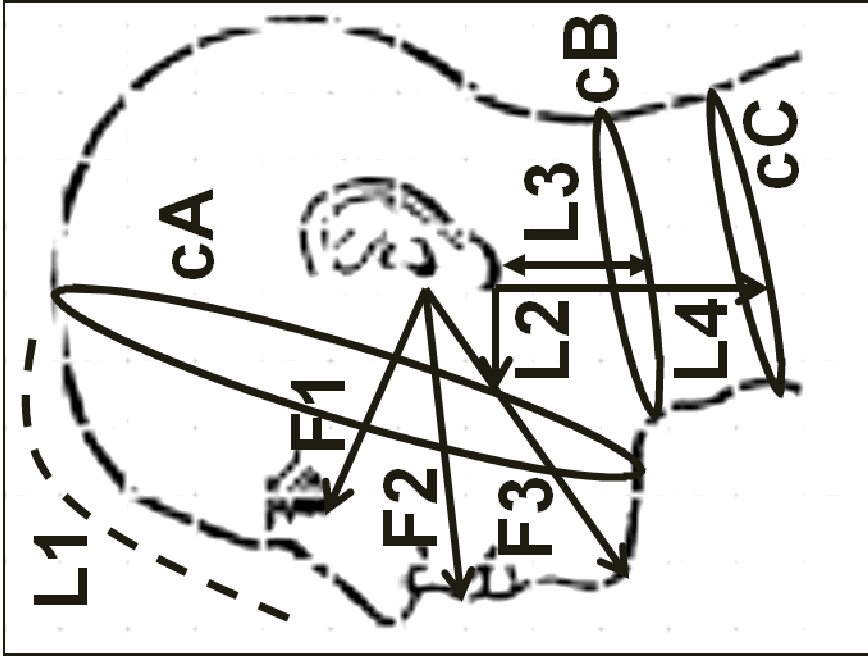
- Silver H, Dietrich M, Murphy B. Changes in Body Mass, Energy Balance, Physical Function, and Inflammatory State in Patients with Locally Advanced Head and Neck Cancer Treated with Concurrent Chemo-Radiation after Low-dose Induction Chemotherapy. *Head & Neck* 29(10): 893-900.
- Zimmerman T, Leonhardt H, Kersting S, Albrecht S, Range U, Eckelt U. Reduction of Postoperative Lymphedema after Oral Tumor Surgery with Sodium Selenite. *Biological Trace Element Research* 106(3): 193-203.

Acknowledgements

- Pictures from *Muscle Testing Techniques of Manual Examination*. Lucille Daniels, M.A., Catherine Worthingham, Ph.D.
- Pictures from *Klose Training & Consulting Lymphedema Therapy Certification Course Manual*
- Pictures from *Myofascial Pain and Dysfunction: The Trigger Point Manual*. Janet G Travell, M.D, David G Simmons, M.D.
- Pictures from *Physical Therapy of the Shoulder*. Robert Donatelli, ed.

Swelling Assessment for the Head and Neck

SWELLING ASSESSMENT	Date	
	R	L
Circumference: Chin to apex/head cA		
Apex to between eyebrows L1		
SIDE	R	L
Earlobe to tape for chin to head L2		
Circumference: Upper neck cB		
Circumference: Lower neck cC		
SIDE	R	L
Distance: Earlobe to upper neck L3		
Distance: Earlobe to lower neck L4		



FACIAL SWELLING	Date
TMJ to eye corner F1	
TMJ to base of nose F2	
TMJ to mid chin F3	

NECK ROM	Date	
Neck flexion/extension		
SIDE	R	L
Neck lateral flexion		
Neck rotation		

SHOULDER ROM	Date		
SIDE	R	Pain	L
Flexion			
Abduction			
Internal rotation/external rotation			

FIBROSIS	Date	
Fibrosis: Anterior upper neck		
Fibrosis: Mid anterior neck		
Fibrosis: Lower anterior neck		
SIDE	R	L
Fibrosis: Side of neck		