

# ANATOMY AND PHYSIOLOGY IN RELATION TO COMPRESSION OF THE UPPER LIMB AND THORAX

Colin Carati, Bren Gannon, Neil Piller

An understanding of arterial, venous and lymphatic flow in the upper body in normal limbs and those at risk of, or with lymphoedema will greatly improve patient outcomes. However, there is much we do not know in this area, including the effects of compression upon lymphatic flow and drainage. Imaging and measuring capabilities are improving in this respect, but are often expensive and time-consuming. This, coupled with the unknown effects of individual, diurnal and seasonal variances on compression efficacy, means that future research should focus upon ways to monitor the pressure delivered by a garment, and its effects upon the fluids we are trying to control.

## Key words

Anatomy  
Physiology  
Lymphatics  
Compression

Little evidence exists to support the use of compression garments in the treatment of lymphoedema, particularly in relation to the upper body and limbs. There is much we do not know about the finer details of arterial, venous and lymphatic flow in normal, at risk and lymphoedematous limbs, and how this is affected by the application of compression. However, despite this, the use of compression garments is a widely accepted and important part of treatment (Partsch and Junger, 2006).

Colin Carati, Associate Professor; Bren Gannon, Associate Professor, Department of Anatomy/Physiology; Neil Piller, Professor, Director Lymphoedema Assessment Clinic, Department of Surgery, School of Medicine, Flinders University and Medical Centre, Bedford Park, South Australia

More is known about the possible effects of compression on the pathophysiology of lymphoedema when used on the lower limbs (Partsch and Junger, 2006). While some of these principles can be applied to guide the use of compression on the upper body, it is important that the practitioner is knowledgeable about the anatomy and physiology of the upper limb, axilla and thorax, and of the anatomical and vascular differences that exist between the upper and lower limb, so that the effects of these differences can be considered when using compression garments.

## Box 1

### Lymphatic drainage of the axilla

It is difficult to get optimum pressure, if any, into the axillary/medial proximal upper arm area using compression garments. This, combined with a likely annulus of often inappropriate pressure on the shoulder and lateral chest provided by the wearer's bra (in the case of a woman), means that there are often very significant issues of fluid accumulation (initially) and fibre (later) in this area.

This paper will describe the vascular anatomy of the upper limb and axilla, and will outline current understanding of normal and abnormal lymph drainage. It will also explain the mechanism of action of compression garments and will detail the effects of compression on fluid movement.

### Vascular drainage of the upper limb

It is helpful to have an understanding of the vascular drainage of the upper limb, since the lymphatic drainage follows a similar course (*Figure 1*). The venous system of the upper limb consists of superficial and deep systems, with numerous 'perforating' veins (so-called because they pierce the deep fascia separating the skin from the muscles and bones) joining the two systems (Moore and Dailey, 2006).

The superficial system arises from the capillary networks of the skin and subcutaneous tissue, which drain into two major vessels. The anterolateral tissue of the upper limb drains into the cephalic vein. This vein originates from the lateral dorsum of the hand and travels via the lateral border of the wrist and forearm, passing through the lateral aspect of the cubital fossa (where it communicates with the basilic vein via

the median cubital vein), and ascending the arm to pass into the axillary region between the deltoid and pectoralis major muscles. The basilic vein drains the postero-medial aspect of the dorsum of the hand, travels superficially up the antero-medial aspect of the forearm, medially through the cubital fossa and about one-third of the way up the arm, before piercing the deep fascia to then accompany the brachial artery into the axillary region. Both veins connect to the axillary vein, and then the subclavian veins en route to the superior vena cava. Many perforating veins are evident in the anterior aspect of the forearm, coalescing into the median vein of the forearm, which then joins the basilic and/or the cephalic veins (Figure 1).

The lymphatic drainage of the torso does not follow the venous drainage of the torso as closely as in the arm. However, the venous drainage of the torso also enters the axillary, subclavian, or brachiocephalic veins en route to the superior vena cava, and hence may be relevant to the venous drainage of the arm. The anterior wall of the torso and the breast drains mainly into the axillary vein, and to a lesser extent the internal thoracic veins. The ribcage is drained via intercostal and subcostal veins that drain the ribcage posteriorly into the azygous/hemiazygous venous system, or anteriorly into the internal thoracic veins. The posterior wall of the thorax also drains into the azygous/hemiazygous system, which drains directly into the superior vena cava.

### Lymphatic drainage of the upper limb

The lymphatic drainage of the upper limb also consists of superficial and deep systems, which follow similar paths to that of the vascular system. There are four major patterns of lymphatic drainage which are based on early cadaver; lymphography and lymphoscintigraphic investigation (Foeldi et al, 2003).

The superficial lymphatic drainage vessels arise as a plexus within the skin of the upper limb. Vessels drain from the hand mainly along its palmar surface into larger lymphatic vessels that converge towards the veins draining the forearm, especially the basilic vein (Moore and Dailey, 2006), acquiring new vessels from the skin as they travel up the limb (Figure 1).

The lymphatic vessels draining the antero-lateral territory of the arm traverse the upper part of the arm and the anterior aspect of the shoulder; draining into the uppermost (apical) lymph nodes of the axillary lymphatic system (Figure 2). Lymph drainage from the postero-medial aspect of the forearm passes through nodes in the medial cubital region, proximal to the medial epicondyle of the elbow, and then into lateral (humeral) lymph nodes of the axilla.

The deep lymphatic drainage originates from the deeper soft tissue, such as muscles and nerves, joints and the periosteum of the bones. Vessels converge and travel close to the deep veins of the upper limb, occasionally passing through a few lymph nodes, before arriving at the lateral (humeral) axillary lymph nodes (Figure 2) (Moore and Dailey, 2006).

The cutaneous venous drainage of the upper back (thorax) is via dorsal perforating (posterior) cutaneous branches of the posterior intercostal veins and thence to the azygous/hemiazygous system to superior vena cava.

Venous drainage of the skin and dermis of the chest anterior to the mid-axillary line is largely via the thoraco-epigastric vein network, to the axillary vein (via the lateral thoracic vein — the superior part of the thoraco-epigastric

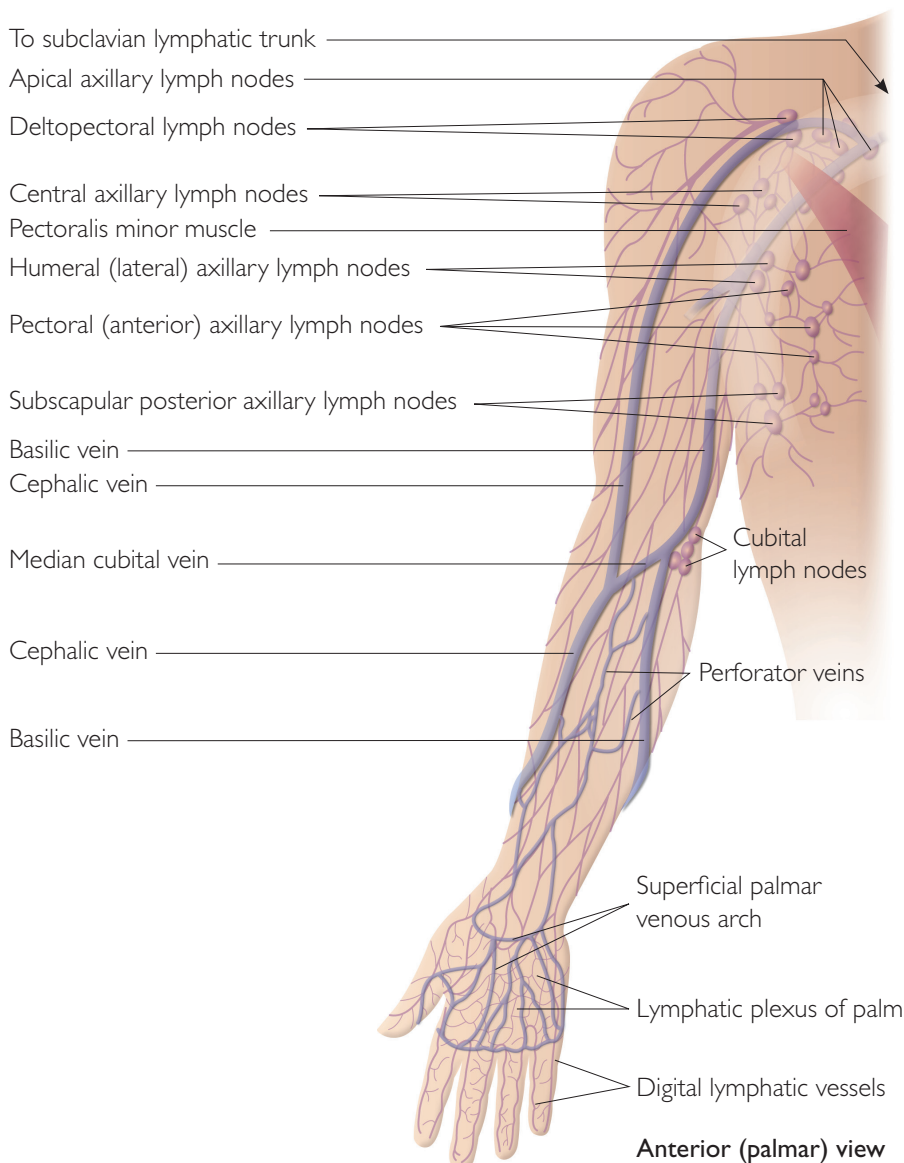
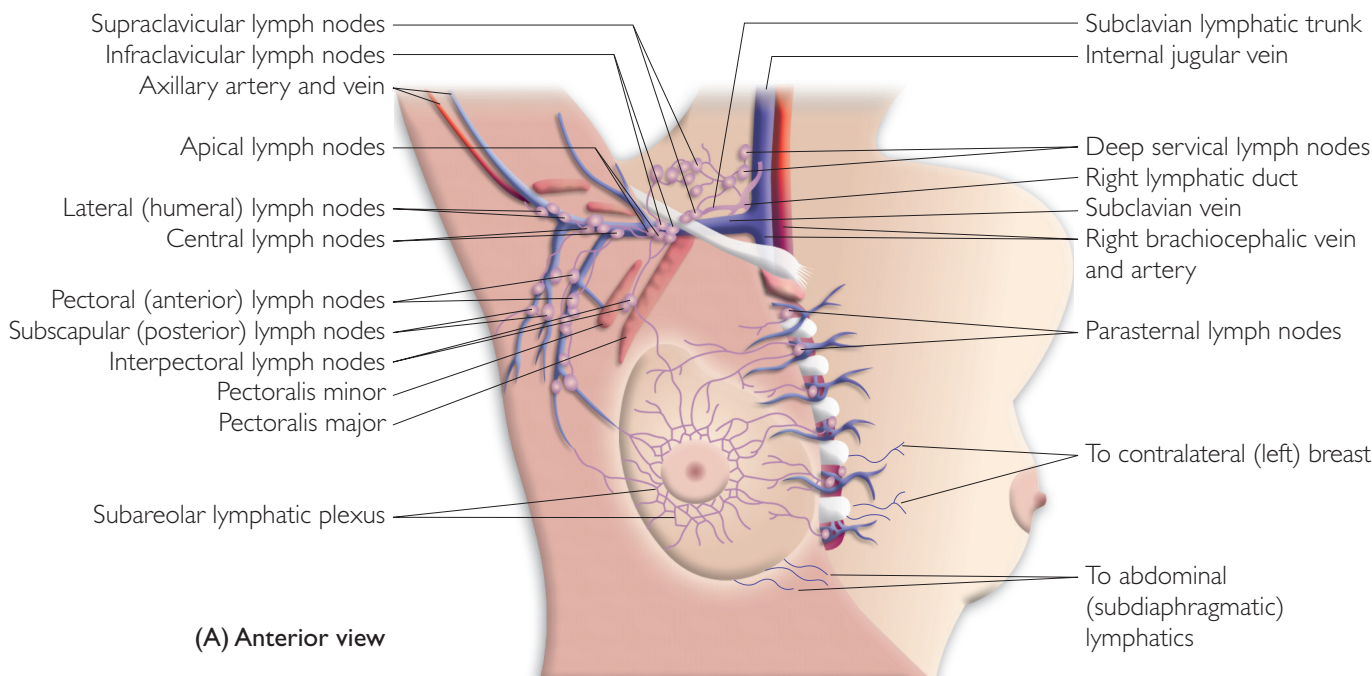


Figure 1. Venous and lymphatic systems of the hand and arm.



**Figure 2. The lymph nodes of the axilla.**

venous network). Venous drainage of the female breast is largely via the lateral thoracic vein to the axillary vein, but the more medial superficial aspects of the breast drain to the paired internal thoracic venae comitantes, then to subclavian vein and on to the superior vena cava. Much of the deepest tissue of the breast drains via perforating veins through the deep fascia to the anterior intercostal veins, and then to the internal thoracic veins.

The venous drainage of the skin and dermis of the chest mainly enters the axillary, subclavian, or brachiocephalic veins en route to the superior vena cava, and hence may be relevant to the venous drainage of the arm.

### Lymphatic drainage of the thorax

The lymphatic drainage of the torso does not follow the venous drainage of the torso as closely as these systems do in the arm. Superficial lymph drainage from the back of the thorax is mainly via a network of superficial lymphatics, which converge to the subscapular (posterior) nodes of the axilla (Figure 2). However, there is the possibility that the more medial back drains via perforating lymphatic connections to the posterior intercostal lymphatics en route to paravertebral nodes (Iyer and Libshitz, 1995).

Lymph drainage of the skin and dermis of the front of the thorax (chest) anterior to the mid-axillary line is largely from individually variable regions (lymphotomes) to particular axillary nodes (i.e. the sentinel node for each region; Suami et al, 2008). The area medial to the nipple in both sexes drains to the parasternal (internal mammary) node chain (Figure 3).

Drainage of the well developed lymphatic network of the female breast, including the dense sub-areola network, is largely via laterally or superiorly directed lymphatics, which pass to pectoral axillary nodes, or to lateral axillary nodes (Suami et al, 2008) (Figure 2). The superficial

aspects of the breast medial to the areola, drain medially to para-mammary and para-sternal nodes (Schuenke et al, 2006), then to the right or left lymph duct or thoracic duct to the subclavian vein, and on to the superior vena cava. Sentinel node tracing from non-palpable (deep) breast tumours (Tanis et al, 2005) suggests that much of the deepest tissue of the breast is likely to drain via the deep lymphatics, which perforate through the deep fascia to join the anterior intercostal lymphatics, passing then to the internal mammary lymph trunk and chain of nodes.

### Lymphatic drainage to the axilla

The lymphatic drainage of the upper limb is intimately related to that of the anterior and posterior regions of the thorax, especially the breast, all of which drain through the axillary region. The axillary region contains five clusters of nodes, arranged in a pyramid pattern dictated by the shape of the axillary region, with three clusters at the base of the axilla, one at its apex and one in the middle (Figure 2) (Moore and Dailey, 2006). These nodes are embedded in the axillary fat, external to the axillary sheath that contains the axillary artery and vein. The majority of the lymphatic fluid associated with the antero-lateral lymphatic territory drains into four to six lateral (humeral) nodes, while that

### Box 2

#### Lymphatic drainage paths

Studies have indicated that lymph drainage of the upper arm travels into the mammary nodes in some individuals with lymphoedema. These drainage patterns also indicate the need to pay attention to the potential effect of clothing (particularly bras) on lymph drainage to the internal mammary, as well as the contralateral axillary nodes.

of the postero-medial territory drains into the apical nodes. The pectoral and subscapular nodes drain the anterior and posterior thoracic wall, respectively, and along with the humeral nodes drain through the central, then the apical nodes en route to the subclavian lymphatic trunk and ultimately the venous system. The consequence of this arrangement is that lymphatic drainage of the upper limb is directly affected by both the drainage of the upper torso and the state of the central lymphatic system.

As is the case with the groin area, it is difficult to get optimum pressures, or any pressure at all, into the axillary/medial proximal upper arm area and this, combined with a likely annulus of often inappropriate pressure on the shoulder and lateral chest provided by the wearer's bra (in the case of a woman), means that there are often very significant issues of fluid accumulation (initially) and fibre (later) in this area.

### Lymphatic drainage paths

Studies have indicated that lymph drainage of the upper arm travels into the mammary nodes in some individuals with lymphoedema. Kawase et al (2006) reviewed lymphoscintigraphy results from 1,201 clinically node-negative patients with invasive breast cancer who underwent preoperative labial salivary gland (LSG) and axillary sentinel lymph node (SLN) biopsy. They reported a range of lymphatic drainage patterns, and almost 25% of patients had drainage to extra-axillary lymph nodes, especially the internal mammary ones (Figure 3). This has also been confirmed by Ferrandez et al (1996) who after a session of manual lymphatic drainage (MLD) found Tc-labeled tracers moved to the internal mammary nodes in 8% of patients with lymphoedema (n=47), as well as to the contralateral nodes in 20% (Figure 4). What this means for the end results of compression is that not only must we consider the compression level and its gradient in the limb, but also the gradient across the truncal area. These drainage patterns also indicate the need to pay attention to the potential effect of clothing (particularly bras) on lymph drainage to the internal mammary, as well as the contralateral axillary nodes (Figure 3).

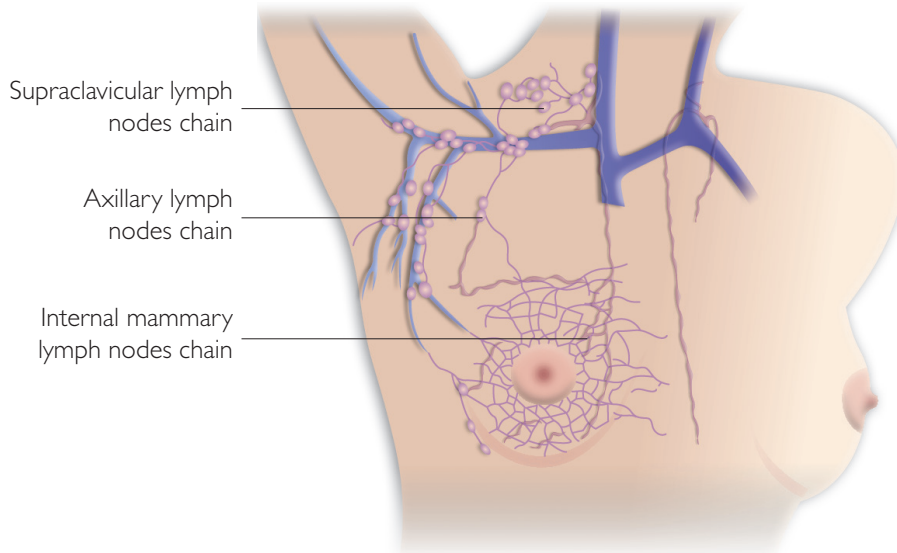


Figure 3. Drainage into mammary lymph nodes.

### Lymphatic cutaneous networks

It is known that there is a greater density of lymphatic vessels in patients with lymphoedema compared to those with normal healthy limbs.

Mellor et al (2000) used fluorescence microlymphography to examine the dermal lymphatic capillaries of the forearm in 16 women with oedema following treatment for breast cancer. They reported that the superficial lymphatic density and total length of capillaries was greater in the swollen limb compared to the control arm. Importantly, the distance travelled by the relatively superficial lymph contents before draining to the sub-fascial system was longer in the swollen limb compared to the normal limb. Furthermore, there was no evidence of lymphatic dilation in the swollen limb. These findings suggest that there is a local re-routing of superficial lymph and possibly lymphangiogenesis in the limbs of patients with lymphoedema. Since the work of others has shown blood capillary

#### Box 3

### Lymphatic cutaneous networks

There is a greater density of lymphatic vessels in patients with lymphoedema compared to those with normal healthy limbs.

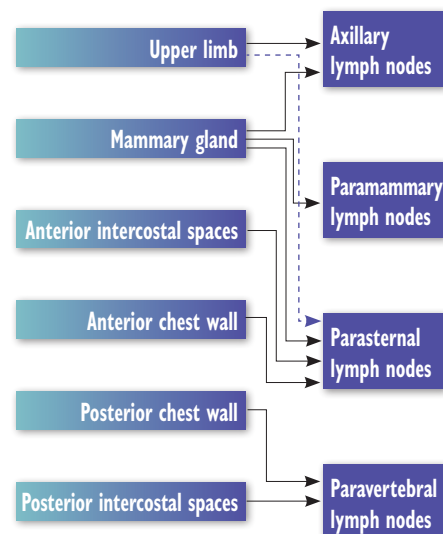


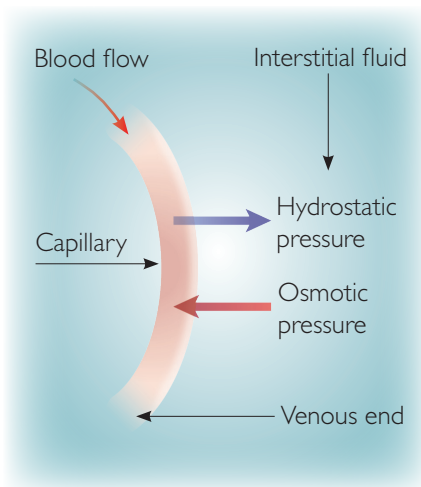
Figure 4. Normal drainage pathways of upper limb and thoracic tissues to the lymph nodes. Note drainage from a breast can be to either the ipsilateral nodes (more commonly) or to the contralateral nodes (less commonly).

angiogenesis in swollen limbs, Mellor et al (2000) hypothesised that the increased number (length) of lymphatic capillaries would possibly help to maintain the ratio of drainage capacity to filtration capacity. The impact of external compression on this change is possibly minor, but the longer travel distance of the lymph in the superficial lymph collectors may mean that the establishment and maintenance of a pressure gradient along the limb is very important.

### Tissue structure of the arm

The upper arm contains deep and





**Figure 5. Diagram of the hydrostatic and oncotic pressures acting across the capillary wall, affecting transendothelial exudation of fluid from plasma to the interstitium.**

epifascial fat layers. The deep fat layer found in the posterior and deltoid region of the arm is thin. In normal limbs the epifascial fat layer is circumferential, but can hypertrophy in the proximal posterior one third of the arm. In lymphoedematous limbs this hypertrophy is marked and not only has an influence on lymph load, but also on lymph drainage, as the additional tissue pressure of the adiposites on the delicate walls of the lymph collectors constrains them from their optimal contraction. Chamosa et al (2005) found that in normal arms, the anterior and distal third of the upper arm tended to have less thick adipose tissue. Occasionally, a specific lipodystrophic zone can be found on the posterior-external area of the normal arm, located between the proximal and medial thirds. Relatively speaking, the skin of the medial aspect of the normal arm is generally thin, devoid of hair follicles, and prone to sag. Overall, the skin is mobile and overlies loose, nonfibrous fat. However, as lymphoedema develops, there are a range of significant epifascial tissue changes which occur (mainly to the amount of fat and fibre, as there is a thickening of the deep fascia and the fascia between the lobules of adiposites). These will have significant effects on the outcome of external compression in terms of its transmittance into the tissues and to the vascular and lymphatic systems within it. Of particular importance is the increase in the thickness of the deep

fascia and its impact on the interchange of fluids between the deep and superficial lymphatics. We will not go into these pathophysiological changes here, since they are well documented and in mainstream literature (Foeldi et al, 2003; Weissleder and Schuchhardt, 2008).

Reduced epifascial depth, most often associated with a lesser amount of fat directly above the deep fascia means that the lymph collectors (which are normally lying above the deep fascia) are more superficial than those which are covered with a greater depth of fat, thus generally requiring a lower compression pressure.

### Physiological factors affecting lymphatic drainage

Both normal and abnormal patterns of lymphatic drainage help to demonstrate how fluid flows through tissues, so it is important to understand both previous and current theories of lymph formation and movement.

In the healthy individual, the vascular system runs into the capillaries, which are small vessels that are bathed in interstitial fluid. The capillaries have thin, semi-permeable walls made up of a single layer of endothelial cells that allow the transfer of oxygen and nutrients from the blood into the tissues, and the transfer of waste products such as CO<sub>2</sub> and urea from the tissues into the blood.

Fluid movement across the capillary wall behaves according to the principles first outlined by Starling (1896), whereby the blood's hydrostatic pressure forces fluid from the capillaries down a substantial pressure gradient into the tissues, while the colloid osmotic pressure of the blood 'sucks' fluid back into the capillary 'up' a

substantial osmotic gradient (Figure 5). The balance of these forces results in a net fluid flux into the tissue under normal circumstances, which is then drained away by the lymphatic system.

It is important, however, to be aware that the current textbook version of this process has fluid being filtered from the arterial end of the capillary, and resorbed at the venular end (e.g. Marieb et al, 2007), as the hydrostatic pressure decreases along the capillary (due to frictional losses or resistance), and the balance of the so-called Starling forces shift from favouring filtration to favouring resorption along the capillary. This view is now being replaced by the opinion that, at least in most capillaries in normal circumstances, there is no resorption of fluid, and the net flux is solely into the tissue from where it is cleared by the lymphatics (Michel, 1997; Levick, 2004; 2009).

During this fluid movement, most plasma proteins of the blood are retained in the vascular system as they do not cross the capillary membrane in most tissues. The emerging consensus is that the 'barrier' to the transcapillary flux of plasma proteins and larger lipophobic solutes lies at the glycocalyx, a complex luminal layer of anionic polysaccharides and glycoproteins secreted by, and attached to, probably all capillary endothelial cells. The glycocalyx acts as a fine fibre filter hindering larger molecule transit by steric exclusion in a size-dependent manner (Squire et al, 2001; Zhang et al, 2006). The physical path for fluid leakage lies beyond the glycocalyx, at infrequent short breaks in junctional membrane strands along inter-endothelial cell junctions, which elsewhere seal junctions tight (Adamson et al, 2004; Curry, 2005). The net result of this arrangement is that fluid resorption at the capillary is unlikely under normal conditions, and requires larger breaks in endothelial integrity, such as those occurring during inflammation. A corollary of this is that fluid fluxes through the lymphatic system are likely to be larger than previously thought, since there is no venular resorption of fluid under normal physiological conditions. For this reason, improved knowledge of the impact of compression on the superficial lymphatic flow is essential.

#### Box 4

##### Factors affecting lymph drainage

There is no resorption of fluid, and the net flux is solely into the tissue from where it is cleared by the lymphatics. Thus, fluid fluxes through the lymphatic system are likely to be larger than previously thought.

A further corollary is that increasing interstitial pressure will reduce the pressure gradient forcing fluid out of the capillaries, and will thus reduce fluid fluxes into the tissue. Conversely, increased colloid osmotic pressure of the interstitial fluid would increase fluid fluxes, since the colloid osmotic gradient withholding fluid in the plasma would be reduced in this circumstance (Levick, 2009). Such a situation may arise if there is accumulated interstitial protein due to increased transcapillary protein leakage into the tissue, increased interstitial proteolysis (such as that occurring during inflammation), or reduced drainage of interstitial protein due to poor lymphatic drainage. Each of these factors will be affected by compression of the limb, and can lead to reduced fluid influx into the tissues. The role of compression on the limb, therefore, may well be to prevent fluid accumulation, rather than to encourage lymphatic drainage, as is often suggested.

Blood and lymphatic drainage from the arm is also influenced by movements and contractions of skeletal muscle and intrathoracic pressure, as well as by positional changes.

### Lymphatic and vascular changes after surgery and radiotherapy

The main cause of upper body lymphoedema arises from cancer of varying causes, especially breast cancer, which is often treated by surgery and radiotherapy. It is clear that lymphoedema following surgery and/or radiotherapy starts with an obstruction of the drainage in the axillary area, but the exact pathophysiology of the following sequelae in the lymph vessels (and surrounding tissues) is not well known (Pain et al, 2005). Furthermore, there are some important haemodynamic aspects of the arm following surgery (+/- radiotherapy) which are poorly understood.

#### Arterial inflow

There is some evidence that arterial inflow is increased in lymphoedematous arms following treatment for breast cancer (Dennis, 2008). Using a variety of techniques, the blood flow into the lymphoedematous arm has been reported to be increased by 42–68%

compared to unaffected arms (Jacobsson, 1967; Svensson et al, 1994a; Martin and Foldi, 1996; Yildirim et al, 2000). Jacobsson (1967) reported this increase was mainly in the skin and subcutaneous tissues. In contrast, Stanton et al (1998) found that the blood flow was the same between affected and unaffected arms, although the per unit volume of blood flow was actually reduced in affected arms since it was of larger volume. The reasons for this change in blood flow in lymphoedematous arms is not clear, although there clearly are structural changes in the affected limb that might cause increased blood flow. On the other hand, an increased arterial inflow may serve to increase fluid filtration into the tissue, and thus increase the risk of developing lymphoedema; such an increase in arterial flow may result from damage to the autonomic innervation to the limb due to surgery and/or radiation (Kuhl and Molls, 1995).

#### Venous outflow

Venous outflow may also be compromised in lymphoedematous limbs (Dennis, 2008). Significant venous obstruction was reported in 57% of 81 patients assessed by Svensson et al (1994b) using colour Doppler ultrasound imaging. Szuba et al (2002) reported a lower but still significant 4.6% prevalence of venous obstruction of lymphoedematous upper limbs. There are several other lines of evidence that indicate that there is an association between venous dysfunction and lymphoedema, especially in the lower limbs (Dennis, 2008), and this should be considered carefully when contemplating compression treatment of the upper limb. Any factors that compromise venous outflow will significantly increase capillary hydrostatic pressures and result in increased fluid filtration into the tissues, leading to larger lymphatic loads.

#### Lymph outflow

There are few reports on surgery and/or radiotherapy for breast cancer and their effects on lymphatic flow through the arm and torso. Perbeck et al (2006) studied lymph clearance using <sup>99</sup>Tc-nanocolloid clearance in breast tissues 2.5 years after surgery and/or radiotherapy for breast cancer. They reported a 4.0-fold

increase in lymph flow after lumpectomy plus radiotherapy, 2.5-fold increase in the contralateral (non-operated) breast and a 1.5-fold increase in the operated non-irradiated breast, indicating long-term changes in basal lymphatic flow of breast tissues. Stanton et al (2009) measured muscle and subcutis lymphatic drainage of the arm after axillary surgery for breast cancer in 36 women, using lymphoscintigraphy. They reported that muscle lymph drainage always exceeded that of subcutis drainage, and subcutis drainage was higher in women who subsequently went on to develop lymphoedema. They concluded that women with higher filtration rates and therefore higher lymph flows through the axilla, were at greater risk of developing lymphoedema after axillary surgery, presumably because they had less lymphatic reserve to deal with additional fluid loads following surgery.

### Mechanisms of action of compression garments

In the management of lymphoedema the term 'compression therapy' covers a range of treatment modalities including multilayer inelastic lymphoedema bandaging and compression garments (Partsch and Junger, 2006). Compression garments are used for the prophylaxis, treatment and long-term management of lymphoedema and may work by:

- ▶▶ Increasing interstitial pressure
- ▶▶ Improving tissue fluid drainage
- ▶▶ Stimulating lymphatic contractions
- ▶▶ Breaking down fibrosclerotic tissue.

#### Increasing interstitial pressure

Externally applied pressure is transmitted into the tissue, although not always in a linear fashion. Pressure up to 200mmHg increased interstitial tissue pressure to within 65–75% of the externally applied pressure in normal pig limbs, and up to 100% when the limb was oedematous and less compliant (Reddy et al, 1981). The pressures generated (and measured) by compression garments are likely to depend on the measurement technique, the nature (knit/elasticity) and fit of the garment, and the compliance of the limb tissue being compressed. Pressures of 8–38mmHg have been measured under garments applied to burns patients using

standardised protocols (Mann et al, 1997), but there was wide variation within and between measurement sites; for example, mean pressure over the anterior thigh was significantly less (8mmHg) than that over the posterior thigh (15mmHg), presumably due to radial and circumferential differences (as per the law of Laplace) by the same garment applied at these sites. Custom-made compression garments increased sub-dermal pressure in burns applications, over a range of 9–90mmHg, but measurements of the pressures under garments over-estimated the pressure transmitted into 'soft' tissues (e.g. muscle) by up to 50%, and under-estimated the pressure transmitted into 'bony' sites by a similar amount (Giele et al, 1997). Thus, measurements taken at the garment-skin interface may not always be representative of pressures transmitted into the tissues, and should be interpreted with care.

Increased interstitial pressure will affect fluid exchange from the blood into the interstitium, so as to prevent interstitial fluid (oedema) accumulation. In addition, interstitial pressures greater than capillary or arterial pressures (>40mmHg) are likely to reduce blood flow, further preventing fluid accumulation. To our knowledge, the contribution of these factors to compression therapy has never been assessed in large trials, although the work of Abu-Own et al (1994) is informative and Partsch and Partsch (2005) give some indications of the impact of position on pressures required, although these relate to the lower limb.

#### Improved tissue fluid drainage

External compression improves tissue fluid drainage through the lymphatic system up to a point. Clearance of a radioactively labelled colloid in dog hind limbs increased exponentially (to a maximum of three-fold) with increasing externally applied pressure up to 60mmHg. Above 60mmHg, clearance decreased to almost nothing (Miller and Seale, 1981). Similar results were reported in human lower limbs, except that the pressure at which maximum clearance occurred varied with posture, being 30mmHg supine compared with 60mmHg sitting (Chant, 1972). In a more clinical setting, below-knee stockings (ankle pressure 30mmHg) doubled

veno-lymphatic drainage of intradermally injected sodium-fluorescein solution in both normal limbs and those with venous insufficiency (Lentner and Wienert, 1996). Most convincingly of all, however, is the general observation that compression therapies can acutely reduce limb (fluid) volume when appropriately used to treat lymphoedema.

The observation that compression garments enhance tissue fluid clearance is at odds with reports that the lymphatic system is a low-pressure system. The lateral pressure in human (and many other) lymphatics reaches 15–40mmHg during movement, but is much lower under resting conditions (1–12mmHg) (Aukland and Reed, 1993). Thus, compression garments, which induce interstitial pressures of, for example, 10–40mmHg on the arm, are likely to be collapsing lymphatic vessels under many circumstances. One can only conclude that compression therapy is unlikely to simply increase drainage through the (often compromised) lymphatic system, but is likely to affect tissue fluid exchange through other, possibly inter-related, mechanisms, such as decreasing fluid influx into the limb.

#### Stimulation of lymphatic contraction

Lymphatic drainage is dependent upon the spontaneous contraction of valved lymph vessels creating a pumping force. The application of a compression garment results in constant pressure on the skin when the limb is at rest (resting pressure). When the muscles contract, expand and then relax (e.g. during exercise), they transiently press against the resisting garment and so the tissue pressure in the limb increases temporarily. This transiently increased interstitial pressure compresses the adjacent dermal lymphatics and because the collecting and larger lymphatics are valved, these vessels pump passively so that lymph flows up the arm without the lymphatics having to contract. The influence of muscle movement and of different external pressures (and of their transmittance to underlying tissue) depends on the elastic property of the garment material and the compression pressure applied. There is no evidence to suggest that there is increased lymphatic contraction under compression.

### Key points

- ▶▶ There is a lack of knowledge regarding the finer details of the vascular and lymphatic systems for those at risk of, or with lymphoedema.
- ▶▶ Compression is unlikely to simply entice fluid removal through the often compromised lymphatic system.
- ▶▶ Compression therapy may have a significant effect on decreasing fluid influx in the limb.

#### Breakdown of fibrosclerotic tissue

There are two major strategies to break down fibrotic tissue, but for both the number and breadth of the studies are limited. One strategy is through frictional massage and the other through the use of low level laser therapy. There have been some reasonable studies of the latter, using tonometry as a means of detecting changes in epifascial fibrosis as measured by the resistance of the tissues to compression. When low level handheld or scanning laser is used there is a slow, although general softening of the indurated tissues, presumably aiding in the passage of extracellular fluid and allowing a stronger contraction of the lymphangions since they are less constrained. The softening is most often accompanied by limb size changes and subjective improvement (Piller and Thelander, 1998; Carati et al, 2003).

#### Optimising the effects of compression garments

In order to achieve optimal effectiveness when using compression to treat patients with lymphoedema, it is claimed that ideally garments should be custom made and flat-knitted; however, large scale trials are required to support these claims. Of the utmost importance is accurate measurement of the garment, accounting for changes in the limb volume with position (elevated or in dependent positions), and whether the limb is likely to

be active or inactive, which depends on the patient's occupational status. However, little is known regarding the effect of the above variables on garment pressure gradients and on undergarment pressures. In the interim, however, we can extrapolate our knowledge of how lymphoedematous and oedematous legs respond (at least in the dependent position), as this may help to guide research into the impact of compression on the arm. In addition to these measurement and biological parameters, information about garment characteristics, such as dynamic stiffness index, static stiffness index, multi-component materials, and inelastic bandaging is important (Partsch et al, 2008; Mosti et al, 2008). There are some recent advances in the burns field in the design of pressure garments which exert a specific and known pressure (Macintyre, 2007), but it is the accuracy of the measurement for the garment that is the prime determinant of an excellent, good or adverse outcome for the limb. Newer pressure-sensing materials may help to partially overcome poor measurement, although these must not be used as an excuse for inaccuracy.

### Anatomical differences between arms and legs

When applied to the upper limb the compression bandage or garment used is less likely to be completely in a dependent position in all its parts; the depth of the deep fascia is often less than a similar position on a leg, the depth of the often closely adherent lymph collectors is less (meaning a more marked effect of external pressure application), the lymph collectors are often of smaller diameter, (having less strong flow and reduced intra-lymphatic pressures). Combined, these factors mean that externally applied pressure, such as from compression bandages or garments or clothing, is likely to have a more profound effect. However, this relative superficiality of vessels means it must be realised that too high a pressure may be counterproductive (Modi et al, 2007) and may cause vessels to collapse, which may manifest as swelling in the arm and/or hand.

The shape variation of the arm over its length is often greater than that of a leg, meaning the impact of the various radii of the different parts of the arm result in the

application of often significantly different pressures at each circumferential point. This is in concordance with the law of Laplace, the outcomes of which often necessitate the use of a range of limb padding strategies to ensure some modicum of lengthwise pressure (a gradient) over the length of the limb, rather than just across a given cross-section of the limb.

### Conclusion

There is much we do not know with respect to accurate details of the arterial flow into and the lymphatic and venous outflow from normal, at risk and lymphoedematous limbs. Specifically, we do not know enough about the effects of compression on venous and lymphatic flow and drainage. In terms of the upper body, the contributory impact of variations in intra-thoracic pressure on proximal arm clearance, a patient's garments and the impact of the varying circumference of the chest with respiratory cycles is relatively unclear and most likely to significantly vary, not only between clients, but also in a client from day to day and hour to hour depending on their activity, body position and the activity level of their limb.

Knowing more about the anatomy, physiology, pathophysiology of the tissues and structures of the upper body will help us gain better outcomes for the client at risk of, and with, lymphoedema. However, it would seem that the best way forward is to acknowledge individuality, diurnal and seasonal variances and to develop better means to monitor the pressure effect of the prescribed garment on the fluids we are trying to control.

Perhaps for the majority of patients this is an easier, more cost-effective option than attempting a range of tests on all patients to determine the anatomy, physiology and pathophysiology of the correct function (or otherwise) of the patient's blood, tissue and lymph systems. Knowing the latter will, however, also help achieve the overall goal of holistic patient care. **JL**

*This paper first appeared in the Template for Practice: Compression hosiery in upper body lymphoedema. 2009. HealthComm UK Ltd, Aberdeen. To download the full document please go online to: [www.wounds-uk.com](http://www.wounds-uk.com)*

### Associate Professor Bren Gannon

Bren recently died of complications after heart surgery. He was an esteemed and much-loved colleague. Bren was a walking encyclopedia. He always had an answer for every question, be it anatomical or clinical. Bren will be remembered for his fantastic contribution to medicine, to the university community and to the staff and students. He lived life to the full, being an enthusiastic fisherman, a dedicated colleague and most of all a friend to all who met him. *Vale Bren.*

### References

- Abu-Own A, Shami SK, Chittenden SJ, Farrah J, Scurr JH, Smith PD (1994) Microangiopathy of the skin and the effect of leg compression in patients with chronic venous insufficiency. *J Vasc Surg* 19(6): 1074–83
- Adamson RH, Lenz JF Zhang X, Adamson GN, Weinbaum S, Curry FE (2004) Oncotic pressure opposing filtration across non-fenestrated rat microvessels. *J Physiol* 557: 889–907
- Aukland K, Reed R (1993) Interstitial-lymphatic mechanisms in the control of extracellular fluid. *Physiol Rev* 73: 1–78
- Calbet J, Holmberg H, Rosdahl H, van Hall G, Jensen-Urstad M, Saltin B (2005) Why do arms extract less oxygen than legs during exercise? *Am J Physiol Regul Integr Comp Physiol* 289(5): 1448–58
- Carati, C, Anderson S, Gannon B, Piller N (2003) Treatment of post mastectomy lymphoedema with low level laser therapy. Results of double blind placebo controlled trial. *Cancer* 98(6): 1114–22
- Chamosa M, Murillo J, Vázquez T (2005) Lipectomy of arms and lipograft of shoulders balance the upper body contour. *Aesthetic Plast Surg* 29(6): 567–70
- Chant ADB (1972) The effects of posture, exercise and bandage pressure on the clearance of <sup>24</sup>Na from the subcutaneous tissues of the foot. *Br J Surg* 59: 552–5
- Clark M, Krimmel G (2006) Lymphoedema and the construction and classification of compression hosiery. In: *Lymphoedema Framework. Template for Practice: compression hosiery in lymphoedema*. MEP Ltd, London
- Curry FE (2005) Microvascular solute and water transport. *Microcirculation* 12: 17–31
- Dennis R (2008) Haemodynamics of lymphoedema. *J Lymphoedema* 3(2): 45–9
- Ferrandez JC, Laroche JP, Serin D, Felix-Faure C, Vinot JM (1996) Lymphoscintigraphic



- aspects of the effects of manual lymphatic drainage. *J Mal Vasc* 21(5): 283–9
- Foeldi M, Foeldi E, Kubik S (2003) *Textbook of Lymphology for Physicians and Lymphoedema Therapists. Sufficiency and Insufficiency of the Lymphatic System*. Urban and Fisher, Munich
- Giele HP, Liddiard K, Currie K, Wood FM (1997) Direct measurement of cutaneous pressures generated by pressure garments. *Burns* 23: 137–41
- Iyer RB, Libshitz HI (1995) Radiographic demonstration of intercostal lymphatics and lymph nodes. *Lymphology* 28(2): 89–94
- Jacobsson S (1967) Studies of the blood circulation in lymphoedematous limbs. *Scand J Plast Reconstr Surg Suppl* 3: 1–81
- Kawase K, Gayed IW, Hunt KK, Kuerer HM, Akins J, Yi M, et al (2006) Use of lymphoscintigraphy defines lymphatic drainage patterns before sentinel lymph node biopsy for breast cancer. *J Am Coll Surg* 203(1): 64–72
- Kuhl C, Molls M (1995) Increased arterial blood flow in arm edema caused by radiation induced neuropathy after therapy for breast carcinoma? *Strahlenther Onkol* 171(3): 176–7
- Lentner A, Wienert V (1996) Influence of medical compression stockings on venolymphatic drainage in phlebologically healthy test persons and patients with chronic venous insufficiency. *Int J Microcirc Clin Exp* 16(6): 320–4
- Levick JR (2004) Revision of the Starling principle: new views of tissue fluid balance. *J Physiol* 557: 704.
- Levick JR (2009) *An Introduction to Cardiovascular Physiology*. 5th edn. Hodder Arnold
- Macintyre L (2007) Designing pressure garments capable of exerting specific pressures on limbs. *Burns* 33(5): 579–86
- Mann R, Yeong EK, Moore M, Colescott D, Engrav LH (1997) Do custom-fitted pressure garments provide adequate pressure. *J Burn Care Rehabil* 18: 247–9
- Marieb EN, Hoehn K (2007) *Human Anatomy and Physiology*. 7th edn. Pearson Benjamin Cummings, San Francisco
- Martin KP, Foldi I (1996) Are haemodynamic factors important in arm lymphoedema after treatment for breast cancer? *Lymphology* 29(4): 155–7
- Mellor RH, Stanton AW, Azarbod P, Sherman MD, Levick JR, Mortimer PS (2000) Enhanced cutaneous lymphatic network in the forearms of women with postmastectomy oedema. *J Vasc Res* 37: 501–12
- Michel CC (1997) Starling: the formulation of his hypothesis of microvascular fluid exchange and its significance after 100 years. *Exp Physiol* 82: 1–30
- Miller GE, Seale J (1981) Lymphatic clearance during compressive loading. *Lymphology* 14: 161–6
- Modi S, Stanton AWB, Svensson WE, et al (2007) Human lymphatic pumping measured in healthy and lymphoedematous arms by lymphatic congestion lymphoscintigraphy. *J Physiol* 583(Pt 1): 271–85
- Mosti G, Mattaliano V, Partsch H (2008) Influence of different materials in multicomponent bandages on pressure and stiffness of the final bandage. *Dermatol Surg* 34(5): 631–9
- Moore K, Dailey AF (2006) *Clinical Oriented Anatomy*. 5th edn. Lippincott Williams and Wilkins
- Newcomer S, Sauder C, Kuipers N, Laughlin M, Ray C (2008) Effects of posture on shear rates in human brachial and superficial femoral arteries. *Am J Physiol Heart Circ Physiol* 294: 1833–9
- Pain SJ, Barber RW, Chandra K, et al (2005) Short-term effects of axillary lymph node clearance surgery on lymphatic physiology of the arm in breast cancer. *J Appl Physiol* 99: 2345–51
- Partsch H, Clark M, Mosti G, Steinlechner E, Schuren J, Abel M, et al (2008) Classification of compression bandages: practical aspects. *Dermatol Surg* 34(5): 600–9
- Partsch B, Partsch H (2005) Calf compression pressure required to achieve venous closure from supine to standing positions. *J Vasc Surg* 42(4): 734–8
- Partsch H, Junger M (2006) Evidence for the use of compression hosiery in lymphoedema. In: *Lymphoedema Framework. Template for Practice: compression hosiery in lymphoedema*. MEP Ltd, London
- Perbeck L, Celebioglu F, Svensson L, Danielsson R (2006) Lymph circulation in the breast after radiotherapy and breast conservation. *Lymphology* 39(1): 33–40
- Piller NB, Thelander A (1998) Treatment of chronic post mastectomy lymphoedema with low level laser therapy. *Lymphology* 31(2): 74–86
- Reddy NP, Palmieri V, Cochran G (1981) Subcutaneous interstitial fluid pressure during external loading. *Am J Physiol* 240: R327–R329
- Schuenke M, Schulte E, Schumacher U (2006) *Atlas of Anatomy. General Anatomy and Musculoskeletal System*. Ross LM, Lamperti ED, eds. Thieme, Stuttgart
- Squire JM, Chew M, Nneji G, Neil C, Barry J Michel C (2001) Quasi-periodic substructure in the microvessel glycocalyx: a possible explanation for molecular filtering. *J Struct Biol* 136: 239–55
- Stanton AW, Holroyd B, Northfield JW, Levick JR, Mortimer PS (1998) Forearm blood flow measured by venous occlusion plethysmography in healthy subjects and in women with postmastectomy oedema. *Vasc Med* 3(1): 3–8
- Stanton AW, Modi S, Bennett Britton TM, Purushotham AD, Peters AM, Levick JR, Mortimer PS (2009) Lymphatic drainage in the muscle and subcutis of the arm after breast cancer treatment. *Breast Cancer Res Treat* 117(3): 549–57
- Starling EH (1896) On the absorption of fluids from the connective tissue spaces. *J Physiol* 19: 312–26
- Suami H, O'Neill JK, Pan W-R, Taylor GI (2008) Superficial lymphatic system of the upper torso: preliminary radiographic results in human cadavers. *Plast Reconstruct Surg* 121(4): 1231–9
- Svensson WE, Mortimer PS, Tohno E, Cosgrove DO (1994a) Increased arterial inflow demonstrated by Doppler ultrasound in arm swelling following breast cancer treatment. *Eur J Cancer* 30A(5): 661–4
- Svensson WE, Mortimer PS, Tohno E, Cosgrove DO (1994b) Colour Doppler demonstrates venous flow abnormalities in breast cancer patients with chronic arm swelling. *Eur J Cancer* 30A(5): 657–60
- Szuba A, Razavi M, Rockson SG (2002) Diagnosis and treatment of concomitant venous obstruction in patients with secondary lymphedema. *J Vasc Interv Radiol* 13(8): 799–803
- Tanis PJ, van Rijk MC, Nieweg OE (2005) The posterior lymphatic network of the breast rediscovered. *J Surg Oncol* 91: 195–8
- Tschakovsky M, Hughson R (2000) Venous emptying mediates a transient vasodilation in the human forearm. *Am J Physiol Heart Circ Physiol* 279(3): 1007–14
- Weissleder H, Schuchhardt C (eds) (2008) *Lymphoedema Diagnosis and Therapy*. 4th edn. Viavital Verlag
- Willoughby DA, Di Rosa M (1970) A unifying concept for inflammation. In: *Immunopathology in Inflammation. Excerpta Medica Int Cong Series* 229: 28–38
- Yildirim E, Soyduinç P, Yildirim N, Berberoglu U, Yüksel E (2000) Role of increased arterial inflow in arm edema after modified radical mastectomy. *J Exp Clin Cancer Res* 19(4): 427–30
- Zhang X, Curry FR, Weinbaum S (2006) Mechanism of osmotic flow in a periodic fiber array. *Am J Physiol* 290: H844–52